

PATHOMORPHOLOGICAL ALTERATIONS AND REPARATORY PROCESSES IN THE KIDNEYS OF BROILERSTREATED WITH OCHRATOXIN A

NEDELJKOVIĆ - TRAILOVIĆ JELENA, SINOVEC SNEŽANA and SINOVEC Z.

Faculty of Veterinary Medicine, Bul. JA 18, Belgrade, Yugoslavia

(Received 13. Septembar 2001)

A 42-day long trial was performed on a total of 48 Hybro broilers divided into four groups. After a 14 day pre-experimental period, the experimental groups were offered feed contaminated with 0.5, 1.0 or 1.5 ppm ochratoxin A, respectively. After that period all groups were normally fed a mixture without added OTA until the end of the trial. Kidney samples were taken after the period of using contaminated feed, as well as after withdrawal the contaminated feed and a 3 week resting period.

Proximal tubules were predominantly affected, while glomerules were chiefly preserved. The cytoplasm of tubulocytes was microgranulated and the nuclei were masked. Vacuolization was noticed in a certain number of altered cells. Foci of acute tubular necrosis were noticed in a few tubules. In some cases weak hemorrhage could be seen in affected areas. In the kidney samples of the group offered contaminated feed followed by a 3 week resting period morphological alterations were expressed in the form of intracellular edema. Epithelial cells of proximal tubules were enlarged with opaque cytoplasm, which caused tubule lumen stenosis. Apoptotic bodies could be noticed between some tubulocytes.

The obtained results suggest that kidney alterations induced by OTA could be restored only to a certain extent as well as that minimum three week resting period is necessary for this process.

Key words: poultry, ochratoxin A, pathomorphological alterations, reparatory processes

INTRODUCTION

There is a continuing debate about the nature of secondary metabolites and their role in the biology of the organisms producing them (Vinning, 1992), but many of these secondary metabolites (antibiotics, phytotoxins, mycotoxins) do have biological activity and may be toxic to microorganisms, plants or animals including humans. Mycotoxins are a very diverse group of highly toxic secondary metabolites produced by a taxonomically wide range of filamentous fungi. There are over 300 known mycotoxins (Smith and Moss, 1985) each causing different disease conditions in the host.

The ochratoxins are a group of seven isocoumarin derivatives linked with an amide bond to the amino group of Lis a highly toxic compound commonly produced (Frisvad and Samson, 1991) as secondary metabolite by two species of fungi: *Penicillium verrucosum* Dierckx and *Aspergillus ochraceus* Wilhelm (alutaceus).

In recent years ochratoxin A (OTA) has received considerable attention because it has revealed nephrotoxic potential in all single-stomach animals studied to date (Moss, 1996). It does not only seriously affect animal performance and health, but it may also have deleterious effects on humans. Of greatest concern in humans (Marquardt and Frohlich, 1992) is its implicated role in an irreversible and fatal kidney disease (Balkan endemic nephropathy). The danger OTA poses to human health can be two fold, first as a result of consumption of commodities directly contaminated with toxigenic strains of the fungi and secondly by the consumption of meat from animals which have eaten OTA-contaminated feeds (Blunden *et al.*, 1991).

It has been found that OTA primarily provokes pathomorphological alterations in kidneys (Buck and Osweiler, 1976; Uraguchi and Yamazaki, 1978; Humphreys, 1988), while other authors (Wyllie and Morehouse, 1978; Leeson *et al.*, 1995) also describe alterations in liver and other organs. In growing chicks post-mortem lesions observed after OTA administration revealed pale, swollen and enlarged kidneys and change in color from the normal mahogany to tan. Microscopic lesions in ochratoxicosis are most prominent in the kidney and liver. On light microscopy, severe distension, enlargement and hypertrophy of the renal proximal convoluted tubules and thickening of the glomerular basement membrane were seen in kidney sections of broilers receiving 2-4 ppm dietary OA for 20 days. (Dwivedi and Burns, 1984). The same alterations were reported by Mraz and Kosutzky (1992), after feeding broilers with 0.85 ppm OA for 42 days. Pathohistological examination revealed epithelial dystrophy of the proximal tubules, presence of eosinophilic granulocytes in the tubular lumen, glomerular dystrophy and cell infiltrate of the intertubular space.

Although very extensive literature data exist concerning pathomorphological alterations of the kidneys caused by OTA (Dwivedi and Burns, 1984; Chang *et al.*, 1981; Huff *et al.*, 1974; Mraz and Kosutzky, 1992), the reparation process has not been well described. Ayed *et al.* (1991) fed broilers with 0.5 ppm OTA. Chicks were fed the experimental diets for 4 weeks after which time the rations were withdrawn and replaced by control finisher diets for 3 weeks (recovery period). At weeks 1 and 2 the renal cortex of all birds was studded with hemorrhage and the medulla was pale and brown. At week 3, the kidneys were enlarged and congested with the occurrence of hematoma. Microscopically, the glomeruli were packed with lymphoid cells, blood vessels were congested, and many epithelial cells of the convoluted tubules were degenerated and/or necrotic.

The present study was, therefore, designed not only to investigate the pathological effect of short term treatment with graded levels of dietary OA on the in kidney tissue of broilers, but also to assess the possible sanation process after the removal of the causative agents.

MATERIAL AND METHODS

Animals. Hybro broilers were obtained from a commercial hatchery. The trial was initiated with on 48 1-day-old chickens, which were housed in wire floor battery brooders. Light dark cycle, temperature and moisture were maintained throughout the trial.

Experimental design. After 14 days long preexperimental period a total of 48 broilers were divided into three experimental groups (A, D, E) and one control group (C). During the next 7 days the experimental groups were offered feed contaminated with 0.5 1.0 or 1.5 ppm OTA, respectively. After that period all groups were normally fed with a mixture without added OTA until the end of the trial.

Diet. All groups of broilers were fed with commercial mash, which consisted of standard feedstuffs and contained enough nutrients to provide the requirements for the examined category. In the feed for experimental groups A, D and E the 99% pure ochratoxin A (Sigma, O-1877), obtained from *Aspergillus ochraceus* culture (303-47-9), was added to provide 0.5, 1.0 and 1.5mg of toxin per kg of feed, respectively.

Sample collection. Kidney samples were taken after the period of toxin administration (21st day) and the remaining birds from the control and experimental groups were normally fed and watered without toxin addition until the end of the trial (42nd day) when kidney samples were taken again. Immediately after sacrifice detailed macroscopic examination was carried out. In the shortest possible period samples of kidney were taken for histological investigations. Kidney samples were fixed in 10% neutral formalin and absolute alcohol, and embedded in paraffin, were cut. Sections of 5-8 m|m thickness and stained using a standard hematoxylin eosin method (Scheur and Chalk, 1986).

RESULTS AND DISCUSSION

Broilers of the control group had properly developed bone and muscle tissue and were in good condition. Their appetite was good, and droppings were normally formed. No health disturbances were observed in experimental groups, except for weak signs of ochratoxicosis in the group offered the feed with the highest amount of OTA. These broilers consumed more water which led them to exhibit diarrhea in some cases. It is obvious that in animals fed with slightly contaminated feed that health disturbances occur without visible signs (Chang *et al.*, 1981; Huff *et al.*, 1974). The increased consumption of water and sporadic diarrhea are connected with higher OTA contamination of the feed and both signs are linked with impairment of water resorption caused by functional damage to the kidney tubules with consequent impairment of water and electrolyte metabolism (Gekle and Silbernagl, 1996).

In both groups of broilers, successively sacrificed during the trial, no pathomorphological alterations that would point to changes in the normal morphological architecture of the kidney were found (Chang *et al.* 1981; Mraz and Kosutzky, 1992). Macroscopic changes in the kidney were found in affected or dead broilers during experimental or spontaneous T-2 toxicoses (Kubena *et al.*, 1981; Harvey *et al.*, 1987), but it has to be emphasized that the mentioned authors

used a significantly higher amount of OTA during a longer period than employed in our trial which more corresponds to possible field cases.

Pathomorphological changes in the kidney were not seen in broilers of the control or the experimental groups fed with 0.5 or 1.0 ppm of OTA. Histopathological alterations of the kidney were noticed only in the group of broilers offered the feed with the highest amount of OTA and sacrificed immediately after the treatment period as well as in those broilers sacrificed after the withdrawal period, but they were diverse in character, intensity and extent.

Proximal tubules were predominantly affected, while glomerules were chiefly preserved. Epithelial cells of the proximal tubules were enlarged with opaque cytoplasm, which caused tubule lumen stenosis (Figure 1). The basal membrane of epithelial cells was intact. The cytoplasm of tubulocytes was microgranulated and the nuclei were masked. Also, decreased volume and hyperchromatosis of the nucleus in epithelial cells of the proximal tubules were detected. Vacuolization was noticed in a certain number of altered cells and expressed as light, transparent cytoplasm (Figure 2).

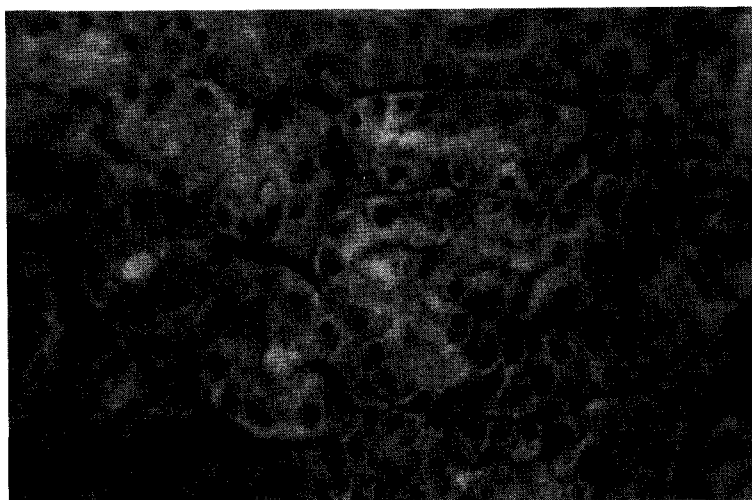


Figure 1. Intracellular edema, cariopycnosis and reduction of kidney tubules in the kidney of an OTA treated chick HE, (40X)

Foci of acute tubular necrosis were noticed in a few tubules (Figure 3). In some cases weak hemorrhage could be seen in affected areas. Fragmentation of the necrotic mass and the presence of fresh red blood cells were also detected. In some cases intensive extravasation could be seen in affected areas (Figure 4).

Similar to our findings, in broilers fed 2 mg OTA/kg feed Kubena *et al.* (1989) detected enlargement of kidney epithelial cells with dark nuclei, which indicated early degenerative changes in the proximal tubules of intoxicated animals. Comparable changes including dilatation and necrosis of tubules, with almost

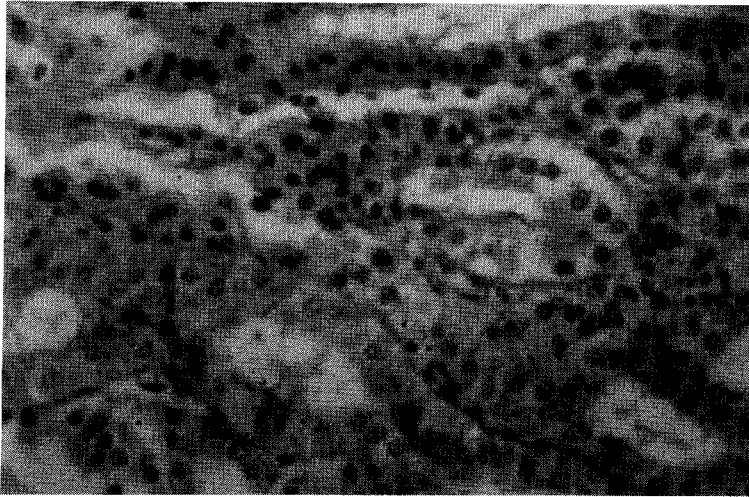


Figure 2. Vacuolized epithelial cells of kidney tubules, from an OTA treated chick



Figure 3. Necrotic damage in an endothelial cells, from an OTA treated chick, HE, (40X)

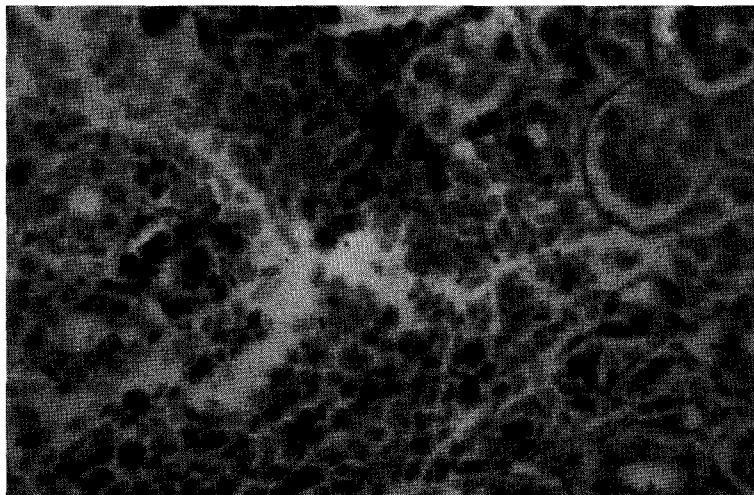


Figure 4. Hemorrhagiae in kidney tissue, from an OTA treated chick, HE, (40X)

double amount of OTA, were described by Harvey *et al.* (1987) who fed broilers with 3.5 mg OTA/kg feed for 28 days. Equivalent alterations could be seen (Mraz and Kosutzky, 1992) after offering broilers feed contaminated with 0.85 ppm OTA for 42 days. Alterations were characterized by proximal tubule epithelial dystrophy, the presence of eosinophilic granulocytes in the lumen of tubules, dystrophic alterations in glomerules as well as the presence of cell infiltrate in intertubule areas.

In the kidney samples from the group offered contaminated feed followed by a 3 weeks of resting period, morphological alterations were expressed in the form of intracellular edema. Epithelial cells of the proximal tubules with unaltered basal membranes were enlarged with opaque cytoplasm, which caused tubule lumen stenosis. Apoptotic bodies could be noticed between some tubulocytes, present as condensed fragments of nucleus with clearly visible light surrounding zones (figure5).

Ayed *et al.* (1991) fed broilers with 0.5 ppm OA for 4 weeks followed by a with 3 week resting period. In contrast opposite to our experimental data, pathohistological examination during the first and second week of treatment revealed an increased number of lymphoid cells, congestion of blood vessels, and degeneration of the proximal tubule epithelial cells. At the end of the third week and during the fourth a homogeneous acidophilus content in tubular lumen was noted, as well as thickening of the glomerular membrane, nodular lymphoid infiltrate and hemorrhages.

The degree of reparation processes could be characterized as mild and weak restitution. Almost all tubules were intact, but enlargement of epithelial cells with opaque cytoplasm and intact basal membrane could still be seen. Although intracellular edema was still the dominant finding, vacuolization of tubulocytes

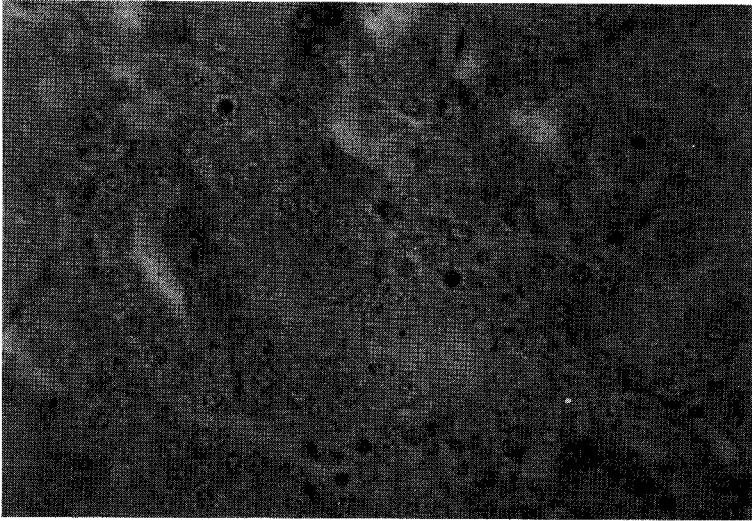


Figure 5. Intracellular edema of tubulocytes and apoptotic body, in the kidney of a chick treated with OTA and then allowed to recover HE, (40X)

could not be seen. Furthermore, hemorrhages and necrotic foci were completely absent. The obtained results suggest that kidney alterations induced by OTA could be restored only to a certain extent as well as that a minimum of three week resting period is necessary for this process.

The obtained results are largely in agreement with the localization of alterations described by almost all authors (Dwivedi and Burns, 1984; Chang *et al.*, 1981; Huff *et al.*, 1974; Mraz and Kosutzky, 1992) who claimed that OTA represents a group of mycotoxins which act preferentially on the nephron. All described pathological changes induced by OTA have a primary localization on proximal kidney tubules and could be connected with toxin metabolism. Stojkovic *et al.* (1984) described the presence of a small molecular weight protein fraction in blood (20.000 Da) which binds OTA more specifically than plasma albumin. The authors concluded that the binding of OTA to these proteins might be relevant to its predominant nephrotoxic effect, because such molecules can easily pass through the normal glomerular membrane, enabling the accumulation of OTA in the kidney. Nevertheless, OTA induced pathological alterations in tubulocytes could be the result of different mechanisms of action: 1) inhibition of mitochondrial activities, 2) inhibition of tRNA-synthetase accompanied by reduced protein synthesis and 3) increased lipid peroxidation. Besides these Gekle and Silberagl (1996) suggest that acute OTA exposure leads to an impairment of postproximal nephron function, resulting in altered electrolyte balance and filtration of electrolytes. The underlying mechanism is most probably a blockade of anion conductance in the plasma membrane with subsequent disturbance of cell acid-base homeostasis.

All presented data indicate that the intensity of pathohistological alterations depends upon dietary level of OTA, meaning that a higher amount leads to more

intensive changes in a shorter period of time, while the same damages could be induced by lower amounts during a longer period of time.

Feeding broilers with highly-contaminated feed unavoidably leads to poor performance caused by morphological followed by functional disturbance of the kidneys. Morphological and functional disturbance of the kidneys develops sooner or later and depends on the duration of broiler exposure to the adverse effect of OTA, as well as on the total quantity the toxin applied. Gradual histogenetic development of changes in water turnover (intracellular edema, vacuolization), hemorrhages and necrosis were found in the kidneys of the treated broilers, but the alterations were reversible and a minimum three week resting period is necessary for this process. Early detection of the presence of OTA in feed, as well as excluding it from broiler diets are methods by which the adverse effects and consequences could be overcome to a certain degree considering the pronounced reparatory processes.

Address for correspondence:
Nedeljković-Trailović Jelena,
Faculty of Veterinary Medicine,
Bul. JNA 18,
11000 Belgrade, Yugoslavia

REFERENCES

1. Ayed AM, Dafalla R, Yagi AI, Sei A, 1991, Effect of ochratoxin A on Lohmann-type chicks. *Vet. Hum. Toxicol.*, 33:557-560.
2. Blunden G, Roch GO, Rogers JD, Coker DR, Bradburn N, John EA 1991, Mycotoxins in food. *Med. Lab. Sci.*, 48:271-282.
3. Buck BW, Osweiler DG, 1976, Clinical and diagnostic veterinary toxicology. 2nd ed., K&H Publ. Comp., Iowa
4. Chang CF, Dorr J, Hamilton PB 1981, Experimental ochratoxicosis in turkey poults. *Poult. Sci.*, 60:114-119.
5. Dwivedi P, and Burns RB, 1984, Pathology of ochratoxin A in young broiler chicks. *Res. Vet. Sci.*, 36:92-102.
6. Frisvad JC, Samson RA, 1991, Mycotoxin produced in species *Penicillium* and *Aspergillus* occurring in cereals. U: Cereal grain mycotoxins, fungi and quality in drying and storage, 441-476, Elsevier, Amsterdam
7. Gekle M, Silbernagl S, 1996, Renal toxicodynamics of ochratoxin A a pathophysiological approach. *Kidney Blood Press. Res.*, 19:225-235.
8. Harvey RB, Kubena LF, Lawhorn BD, Flecher OJ, Phillips D, 1987, Feed refusal in swine feed ochratoxin contaminated grain sorghum Evaluation of toxicity in chicks. *J. Am. Vet. Med. Assoc.*, 190:15-22.
9. Huff WE, Wyatt RD, Tucker TL, Hamilton PB, 1974, Ochratoxicosis in broiler chickens. *Poult. Sci.*, 67:1139-1142.
10. Humphreys DJ, 1988, Mycotoxins. U: Veterinary Toxicology, 3rd ed., 283-311, BT Comp., London
11. Kubena LF, Harvey RB, Huff WE, Corrier DE, Phillips TD, Rottinghaus GE, 1989, Influence of ochratoxin A and T-2 singly and in combination on broiler chickens. *Poult. Sci.*, 68:867-872.
12. Kubena LF, Phillips TD, Creger CR, Witzel DA, Heidelbaugh ND, 1981 Toxicity of ochratoxin A and tunic acid to growing chicks. *Poult. Sci.*, 62:1786-1792.
13. Leesen S, Diaz G, Summers J, 1995, Poultry metabolic disorders and mycotoxins. Univ. Books, Guelph, Canada
14. Marquardt RR, Frohlich AA, 1992, A review of recent advances in understanding ochratoxicosis. *J. Anim. Sci.*, 70:3968-3988.
15. Moss OM, 1996, Mycotoxins. *Mycol. Res.*, 100:513-525.
16. Mraz J, Kosutzky J, 1992, Clinical effects and morphological changes after administration of low doses of ochratoxin A to broiler chicks. *Vet. Med. (Praha)*, 37:237-242.
17. Scheuer PJ, Chalk BT, 1986, Clinical tests: Histopathology. Wolfe Medical Publications, London

18. Smith J, Moss M, 1985, Mycotoxins - Formation, analysis and significance. John Wiley (Sons Ltd, Chichester, Great Britain
19. Stojkovic R, Hult K, Gamulin S, Plestina R, 1984, High affinity binding ochratoxin A to plasma constituents. *Biochem. Int.*, 9:33-37.
20. Uraguchi K, Yamazaki M, 1978, Toxicology, biochemistry and pathology of mycotoxins. Halsted Press, New York, USA
21. Vinning LC, 1992, Role of secondary metabolites from microbes. In Secondary Metabolites: their function and evaluation, 184-194. John Wiley (Sons Ltd, Chichester, Great Britain
22. Wyllie DT, Morehouse GL, 1978b, Mycotoxic fungi, Mycotoxins, mycotoxicosis. An Encyclopedic Handbook, vol. 2, Marcel Dekker, INC, New York

PATOHISTOLOŠKE PROMENE I STEPEN SANACIONIH PROCESA U BUBREZIMA BROJLERA TRETIRANIH OHRATOKSINOM A

NEDELJKOVIĆ TRAILOVIĆ JELENA, SINOVEC SNEŽANA and Z. SINOVEC

SADRŽAJ

Ogled je izveden na 48 Hybro brojlera podeljenih u četiri grupe i trajao je 42 dana. Od 14 dana ogledne grupe su tokom 7 dana dobijale hranu koja je sadržala 0.5, 1.0 ili 1.5 ppm OA. Uzorci bubrega za patohistološka ispitivanja uzeti su nakon završetka tretmana, a preostali brojleri su hranjeni i pojeni bez aplikacije toksina do 42. dana kada su uzorci bubrega ponovo uzeti.

Patohistološkim ispitivanjem utvrđeno je da su pretežno proksimalni tubuli zahvaćeni promenama, dok su glomeruli uglavnom očuvani. Citoplazma tubulocita je sitnozrnasta, a jedra su maskirana. U pojedinim ćelijama uočena je vakuolizacija, dok su u manjem broju tubula uočeni fokusi akutne nekroze. U promenjenim zonama uočena su slaba krvavljenja. U uzorcima bubrega grupa hranjenih kontaminiranom, a zatim nekontaminiranom hranom promene su se ispoljile u vidu intracelularnog edema. Epitelne ćelije proksimalnih tubula su povećane sa zamućenom citoplazmom što je u pojedinim slučajevima izazvalo su'avanje lumena tubula. Apoptotična tela su uočena između pojedinih tubulocita.

Dobijeni rezultati ukazuju da se promene u bubrezima izazvane OA mogu samo delom i u određenom stepenu restituisati, a da za je ove procese potreban period od najmanje tri nedelje.