

*Research article***KIT RECEPTOR EXPRESSION IN CANINE CUTANEOUS MAST CELL TUMORS (CMCTs) WITHOUT C-KIT MUTATION**

VUČIĆEVIĆ Ivana^{1*}, MARINKOVIĆ Darko¹, KUKOLJ Vladimir¹, VUČIĆEVIĆ Miloš², MIRILOVIĆ Milorad³, NEŠIĆ Slađan¹, ALEKSIĆ-KOVAČEVIĆ Sanja¹

¹Department of Pathology, Faculty of Veterinary Medicine, University of Belgrade, Bulevar oslobođenja 18, Belgrade, Serbia; ²Department of Equine, Small Animal, Poultry and Wild Animal Diseases, Faculty of Veterinary Medicine, University of Belgrade, Belgrade, Serbia; ³Department of Economics and Statistics, Faculty of Veterinary Medicine, University of Belgrade, Belgrade, Serbia

(Received 14 April; Accepted 25 May 2016)

Histopathological examination, grading, immunohistochemical staining and molecular genetic examinations are the proposed criteria that should be used for cutaneous mast cell tumors (CMCTs) classification. The presence of aberrant CD117 expression and mutations of the *c-kit* proto-oncogene could be an indicative parameter for final histological grading. Determination of the connection between the localization of KIT receptor expression and the histological grade of CMCTs without *c-kit* proto-oncogene mutations was the main goal of this study. The study included twenty four CMCTs and six control skin samples from 30 dogs of different ages, breed and sex. Formalin-fixed and paraffin-embedded tissue samples were stained with hematoxylin-eosin and toluidine blue and immunohistochemically tested for CD117 expression. DNA was extracted from the same paraffin blocks and subsequent polymerase chain reaction amplification was performed using PE1 and PE2 primers. Degree of malignancy was determined based on the presence of mitotic figures, multinucleated cells, bizarre nuclei and karyomegaly in 10 high power fields. Based on histological features, fourteen of 24 CMCTs were of a high histological grade, while ten were classified as a low-grade malignancy. CD117 cytoplasmic expression was observed in nine of fourteen high-grade malignancy CMCTs, which confirms the link between the aberrant CD117 expression and increased cell proliferation.

Key words: dogs, mast cell tumor, morphology, classification, CD117

INTRODUCTION

Within all round cell tumors that can be diagnosed in dogs, cutaneous mast cell tumors (CMCTs) are the most frequent, comprising 7% to 21% of all skin neoplasms [1-3].

The etiology of CMCTs is probably multifactorial [1,4]. An early study suggested a viral etiology, but ultrastructural examinations have not revealed virus or virus-like particles [5]. Recent work has implied that the transmembrane tyrosine kinase receptor (KIT)

*Corresponding author: e-mail: ivucicevic@gmail.com

that binds the ligand stem cell factor (SCF) is an important factor in the pathogenesis of canine CMCTs [6]. Mutations of the c-kit proto-oncogene could also be involved in CMCT pathogenesis [7-9].

The most commonly used histological grading systems for canine CMCTs are those developed by Patnaik *et al.* and Kiupel *et al.* [10,11].

A large number of grade II CMCTs and interobserver variations are the major weak points of the Patnaik grading system [12]. The Kiupel grading system eliminates ambiguity of intermediate-grade CMCTs and grading criteria are relatively simple and less influenced by subjective inter-observer variation in comparison with the Patnaik grading system [11,13]. According to Kiupel grading system, high-grade CMCTs include neoplasms with at least one of the following features: at least 7 mitotic figures in 10 high power fields (hpf); at least 3 multinucleated cells in 10 hpf; at least 3 bizarre nuclei in 10 hpf; or at least 10% karyomegalic cells of the neoplastic cells [11].

The predictive value of KIT receptor expression has been examined recently [8,9,14,15]. Normal and some neoplastic mast cells have only membranous KIT localization while in many neoplastic mast cells KIT accumulation is noticed in the cytoplasm [8,14-16]. Some authors emphasize a correlation between the expression of the KIT receptor and the histological grade of CMCTs [16,17] and others believe that there is a correlation between the degree of CMCT differentiation and the KIT expression pattern [8].

A significant association between the aberrant KIT expression and the presence of c-kit proto-oncogene mutations has been identified in dogs with CMCTs. However, mutations were not present in all CMCT samples with aberrant KIT expression [18]. The c-kit proto-oncogene encodes the receptor tyrosine kinase [9].

The aim of our study was to determine the connection between the localization of KIT receptor expression in CMCTs without c-kit proto-oncogene mutations and the histological grade of CMCTs.

MATERIAL AND METHODS

Animals

A subset of 24 dogs from the Faculty of Veterinary Medicine medical database was searched for diagnoses of canine cutaneous CMCT. The skin samples of dogs were sampled in different veterinary clinics from the Republic of Serbia. Additional data including age, sex, breed, and location of the mass, were obtained from referring veterinarians. Intact skin samples from 6 necropsied adult dogs were used as the control.

DNA Isolate

Known dog DNA isolate containing c-kit mutation (Michigan State University, USA) was used as a positive control for this mutation.

Histopathology

Initial diagnosis and grading of tumors were made using hematoxylin (HE) and Toluidine blue staining (TB).

Histopathological features of CMCTs, such as the number of mitotic figures, the presence of multinucleated cells, bizarre nuclei and karyomegaly were evaluated on the HE stained sections. Each parameter was observed on 10 hpf (400x).

Immunohistochemical staining

Formalin-fixed paraffin embedded tissue samples were cut to 5µm sections and the three-step indirect immunohistochemical (IHC) technique was performed. Antigen retrieval was achieved by heating the sections in a microwave oven at 560 W for 21 minutes in a citrate buffer (pH 6.0). The sections were treated with methanol containing 0.3% hydrogen peroxide for 15 minutes at room temperature in order to inactivate endogenous peroxidase. Nonspecific binding of secondary antibodies was minimized by incubating with 50% normal goat serum in PBS for 20 min. The sections were incubated with primary antibodies diluted in phosphate buffer saline (pH 7.2) for 1 h in a humid chamber at 22±3°C. For immunohistochemical staining CD117, polyclonal rabbit anti-human antibody (DAKO, A4502) was used diluted 1:400. The immunoreaction was visualized with DAB+ (3,3'-diaminobenzidine tetrahydrochloride, DAKO, K3468). Sections were counterstained with Mayer's hematoxylin. Aqueous medium glycergel (DAKO, C563) was used on the stained sections for mounting. Appropriate positive and negative controls were used.

Evaluation of CD117 immunostaining

CD117 immunohistochemical labeling was evaluated by identifying areas with the highest proportion of immunopositive neoplastic mast cells at 100 x magnification. After determination of highly proliferative areas, a 1 cm² (10 x 10 mm) grid reticle at 400x magnification was used for counting the number of immunopositive cells present in a 10 x 10 mm grid area. The number of immunopositive cells per grid area was determined in 10 hpf fields and subsequently averaged to obtain the growth fraction.

All slides were assigned one of 3 KIT staining patterns: perimembrane (KIT staining pattern I), focal cytoplasmic (KIT staining pattern II), or diffuse cytoplasmic localization (KIT staining pattern III). Neoplastic mast cells that have primarily immunohistochemically stained membrane with only minimal cytoplasmic staining are characteristic for the CMCTs with KIT staining pattern I. KIT staining pattern II was characterized by neoplastic mast cells with focal to stippled cytoplasmic KIT protein localization. Membrane associated staining was not a prominent feature of these cells. KIT-staining pattern III was defined by neoplastic mast cells with diffuse cytoplasmic staining, obscuring all other cytoplasmic features.

Polymerase chain reaction (PCR)

DNA was extracted from the paraffin blocks using the commercial set „KAPA Express Extract KIT” (Cat. No KK7152, Kapa Biosystems, Cape Town, South Africa) according to the manufacturer’s instructions. The primers used for PCR amplification of the c-kit juxtamembrane domain were PE1 (CCA TGT ATG AAG TAC AGT GGA AG) and PE2 (GTT CCC TAA AGT CAT TGT TAC ACG) [7]. These primer pairs were expected to generate a PCR product size of ~191 bp and another of ~250bp. The thermal protocol consisted of an initial denaturation step at 95°C for 3 min, followed by 40 cycles of denaturation (94°C, 15 sec), annealing (59°C, 15 sec) and DNA extension (72°C, 15 sec), and a final extension step at 72°C for 5 min. PCR products were separated by electrophoresis on a 2% agarose gel, stained with ethidium bromide, and “visualized” with UV light. The presence of mutations was determined by visual examination of the gel images.

Statistical analysis

The obtained results were analyzed using descriptive methods such as mean and standard deviation. Comparison of the data and significance determination were performed by the Chi-square test. The significance was determined on a 5% and 1% level of significance.

RESULTS

Determination of age, breed and topographic related distribution of CMCTs in the examined dogs

The mean age of the dogs with CMCT was 7.56 ± 2.45 years. The following breeds were affected with CMCT: Golden Retrievers (n = 9), Boxers (n = 5), Labradors (n = 3), American Bulldogs (n = 2), Fox Terrier (n = 1), Dogo Argentino (n = 1), Maltese (n = 1), American Staffordshire Terrier (n = 1) and mixed breed (n = 1). Tumors were located on the limbs (n = 10), thorax (n = 9), abdomen (n = 3) and the head (n = 2). Seventeen dogs were male and 7 were female.

Morphological characteristics of CMCTs

According to the observed parameters in CMCTs and based on the propositions of the Kiupel grading system, the examined CMCTs were divided into two categories: 14 high grade and 10 low grade CMCTs.

Mitotic Index (MI)

All tumors were evaluated to determine the average mitotic index (MI). More than 6 mitotic figures per 10 hpf were observed in 29.17% of total CMCTs (Figure 1A), while 70.83% of total CMCTs had a low mitotic index (less than 6 mitotic figures per 10 hpf). Mitotic figures were present in 50% of high grade mast cell tumors.

Presence of multinucleated cells, bizarre nuclei and karyomegaly

The presence of more than two multinucleated cells per 10 hpf (Figure 1B) was observed in 45.83% of total CMCTs and in 78.57% of high grade mast cell tumors.

More than two cells with bizarre nuclei per 10 hpf were present in 41.67% of total CMCTs. Bizarre nuclei were observed in 71.43% of high grade mastocytoma (Figure 1C).

More than 10% of anaplastic mast cells with a nucleus diameter greater than $8\mu\text{m}$ were observed in 33.33% of total CMCTs. In high grade mast cell tumors karyomegaly was present in 57.14% (Figure 1D).

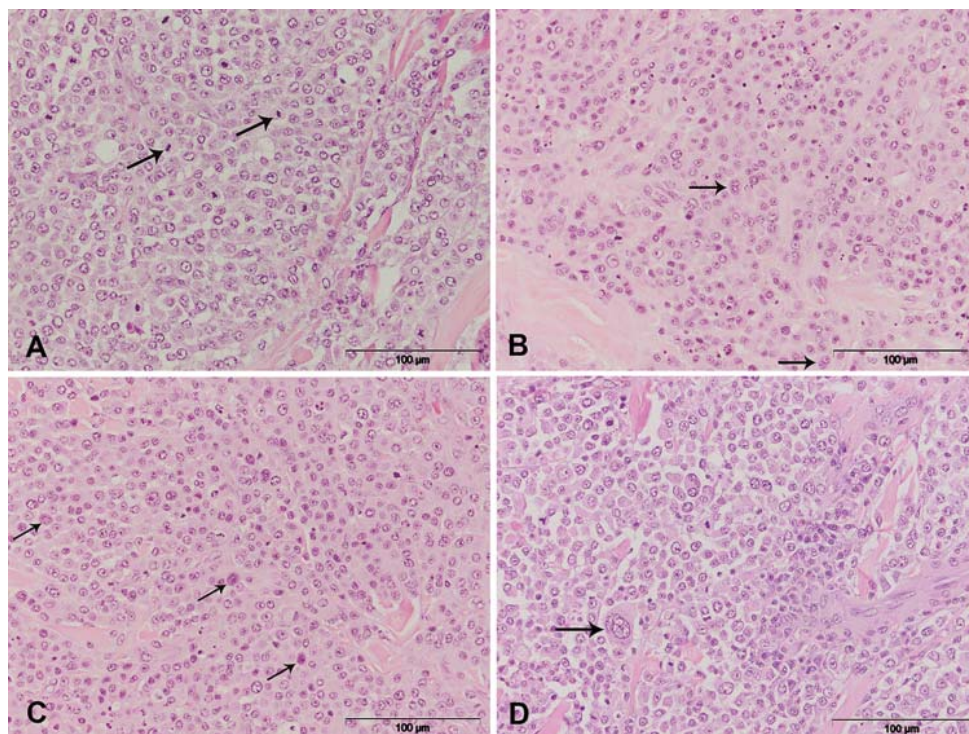


Figure 1. Skin, Dog: **A)** Presence of mitotic figures (arrow) in high grade mast cell tumors, HE, 400x; **B)** Presence of multinucleated cells (arrow) in high grade mast cell tumors, HE, 400x; **C)** Presence of cells with bizarre nuclei (arrow) in high grade mast cell tumors, HE, 400x; **D)** Presence of karyomegaly (arrow) in high grade mast cell tumors, HE, 400x

Microscopic findings on toluidine blue stained slides

In all the observed CMCT samples, cytoplasmic granules showed metachromasia. (Figure 2A and 2B). Intense degranulation of mast cells was observed in 50% of CMCTs (in 1 of 10 low grade and in 11 of 14 high grade CMCTs).

Immunohistochemical parameters relevant for CMCT classification

***KIT* receptor (CD117) immunoexpression in CMCTs**

The majority of CMCTs in this study had KIT-staining pattern I (62.5%) (Figure 2C). This group included all low grade CMCTs and 5 of 14 high grade CMCTs. A total of 20.8% of CMCTs showed KIT-staining pattern II (Figure 2D), while none of the CMCTs had only KIT-staining pattern III. All CMCTs that showed KIT-staining pattern II were high grade CMCTs. Different KIT-staining patterns were detected in 12.5% of CMCTs that had both membranous and focal cytoplasmic expression (Figure 2E), as well as in 4.2% of CMCTs with a membranous/diffuse cytoplasmic pattern (Figure 2F).

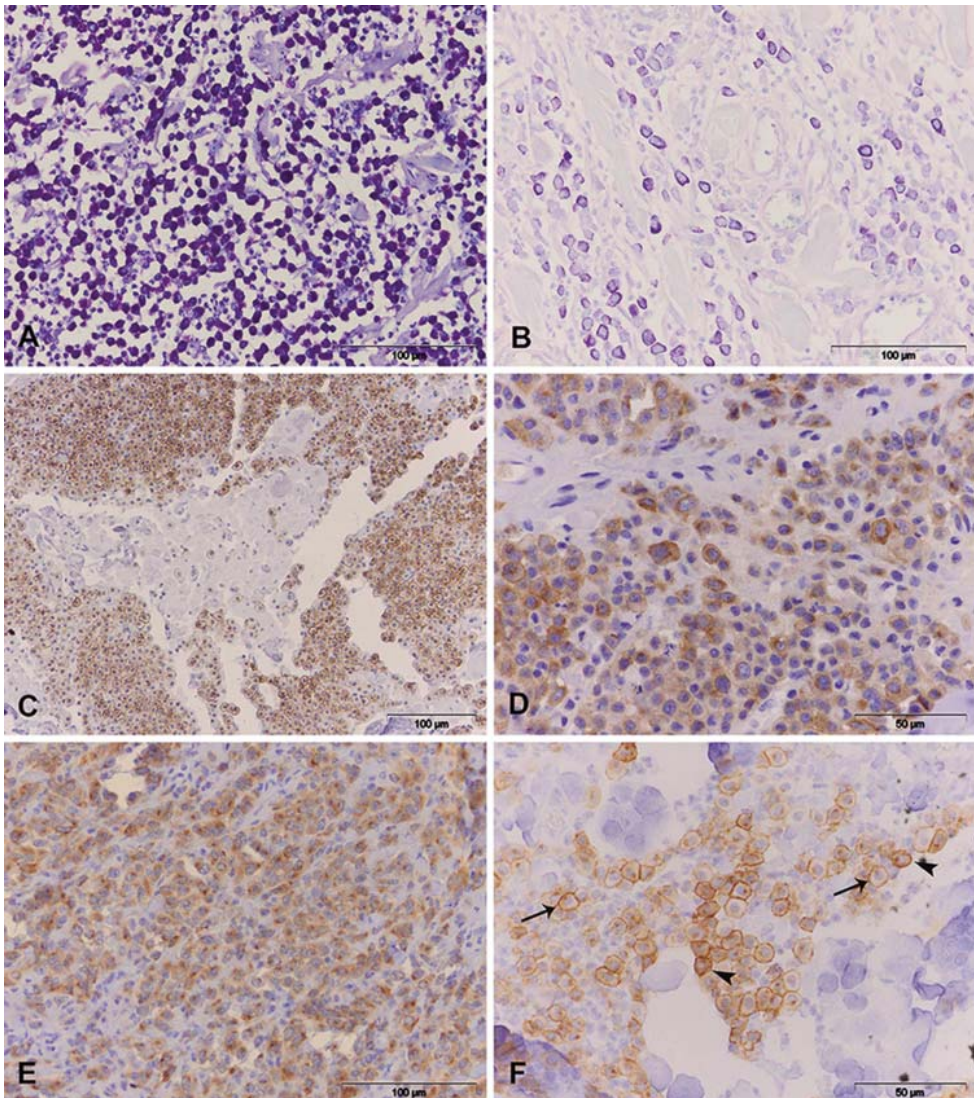


Figure 2. Skin, Dog: **A)** High density of cytoplasmic granules in mast cell tumors, TB, 400x; **B)** Low density of cytoplasmic granules in mast cell tumors, TB, 400x; **C)** KIT expression, membranous expression, CD117, LSAB2, 400x; **D)** KIT expression, diffuse cytoplasmic expression, CD117, LSAB2, 400x; **E)** KIT expression, membranous and focal cytoplasmic expression, CD117, LSAB2, 400x; **F)** KIT expression, membranous (arrow) and diffuse cytoplasmic (arrowhead) expression, CD117, LSAB2, 400x

The obtained results showed that there was no statistically significant difference between different types of cytoplasmic KIT expression in high grade CMCTs ($p=0,285049$). The relation between the different types of KIT expression and the histological degree is shown in Chart 1.

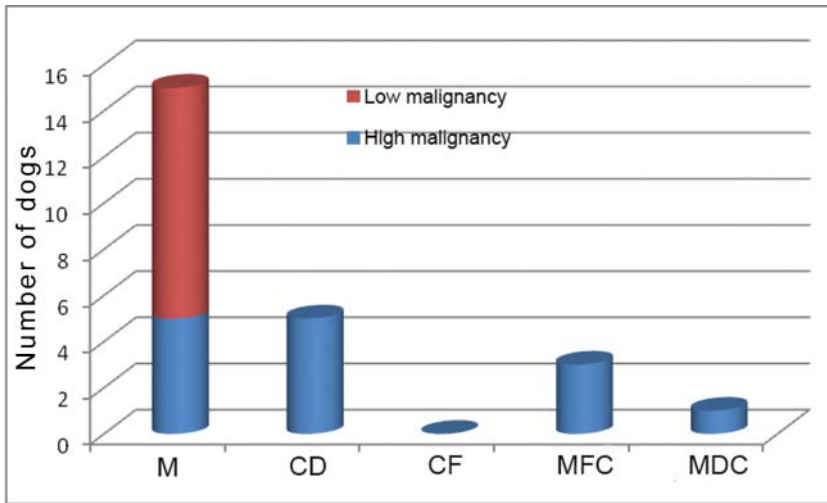


Chart 1. KIT immunohistochemical pattern in 24 MTCs classified according to the histological grade: M-membranous; CD-diffuse cytoplasmic; CF-focal cytoplasmic; MFC- membranous/ focal cytoplasmic; MDC-membranous/ diffuse cytoplasmic

c-KIT Mutation Analysis

No c-KIT mutations (presence of ITD in exon 11) were demonstrated in any of the 24 CMCTs (Figure 3). The positive control showed two bands (150bp and 250bp).

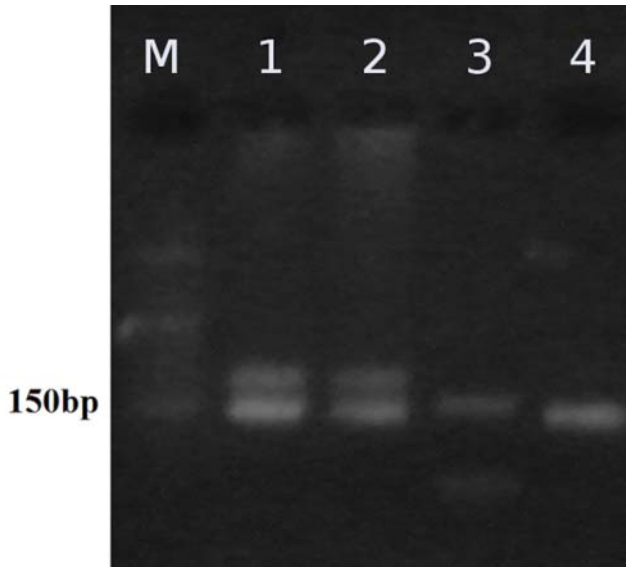


Figure 3. PCR amplification of exon 11 of c-KIT proto-oncogene; M - Marker, 1 - positive control with KIT ITD, 2 - positive control with KIT ITD, 3 PCR product without KIT ITD, 4 - PCR product without KIT ITD

DISCUSSION

Among the nine dog breeds included in this study, the highest frequency of CMCTs was observed in golden retrievers (37.5%), and followed by boxers (20.7%) which reflect a well-known breed predisposition [1,14,18].

According to previous studies, CMCTs were mostly localized on limbs [19,20], or on the trunk [1]. Based on our study, the localization was predominately on the limb skin, similar to other results.

Using the propositions of the Kiupel grading system, we observed more than six mitotic figures in 10 hpf in 50% of high grade CMCTs, so the presence of mitotic figures was not statistically significant ($p>0.05$) in this study. While some authors believe that CMCTs of grades I and II according to the Patnaik classification can also metastasize, and therefore the mitotic index cannot be the only reliable factor to predict tumor behavior [9,10], other authors consider that the mitotic activity is a key prognostic factor of the long-term outcome [11,21]. One of the criteria of the Kiupel grading system is that high-grade CMCTs have at least 7 mitotic figures in 10 hpf [11].

The presence of multinucleated mast cells is characteristic of higher-grade cutaneous CMCTs [10]. In our study more than two multinucleated cells per 10 hpf were observed in 78.57% of high grade CMCTs, while none were present in low grade CMCTs. According to these results multinucleation was significantly associated with higher malignancy.

Cells with poorly marked membranes and large nuclei of irregular shape, as well as multinucleated cells were observed in poorly differentiated CMCTs. More than 10% of anaplastic mast cells with 8-10 μ m nuclei diameter were observed in 57.14% of examined high grade CMCTs. This indicates that karyomegaly cannot be considered as a significant predictive factor in this study.

Unlike previous papers which studied the relationship between the intensity of CD117 immunohistochemical expression and the degree of CMCT differentiation [16], our study revealed an association between the aberrant CD117 expression and the histological degree of CMCTs.

In all low grade CMCTs in this study, only membrane-associated CD117 expression was observed, while both membrane-associated and cytoplasmic CD117 expression occur in high grade CMCTs. Despite the fact that cytoplasmic expression of CD117 is characteristic of a high grade tumor, no significant differences were observed between the expressions of focal or diffuse cytoplasmic CD117 staining pattern related to the histological grade of CMCT. This suggests that both type of cytoplasmic staining may indicate similar cellular changes and cytoplasmic accumulation of CD117 [14]. However, there is a connection between aberrant expression of CD117 and the degree of CMCT differentiation. Increase in cytoplasmic accumulation of CD117 is connected with more aggressive biological behavior of canine cutaneous CMCTs [8,22]. On the other hand, there is an opinion that diffuse CD117 expression is present in clinically benign tumors or in tumors of the first grade of malignancy according to Patnaik and only focal cytoplasmic CD117 expression is characteristic of poorly differentiated (grade III) CMCTs [17].

C-kit mutations are mostly the characteristic of CMCTs of higher histological grade [9,15,23,24]. It has been suggested that these mutations play a role in the malignant transformation of CMCTs [24]. They have been shown to correlate with aberrant CD117 expression, although mutations were not present in all CMCTs with aberrant CD117 expression [18]. Some of the tumor samples we examined had aberrant CD117 expression while mutations were not detected which confirms the fact that CMCTs with no mutation can also express aberrant CD117 pattern. While the intensity of KIT expression may be affected by inter-observer variability, the KIT immunohistochemical pattern (cytoplasmic or membranous) is a more objective parameter. Therefore, KIT staining patterns should be the part of routinely examination of canine patients with CMCTs together with histological grading and c-KIT mutations.

Acknowledgements

Thanks to Dr. Matti Kiupel (College of Veterinary Medicine, Department of Pathobiology and Diagnostic Investigation of Michigan State University, USA) for providing a positive control for c-kit mutation. This study was supported by the Ministry of Education, Science and Technological Development of the Republic of Serbia, Grant III 46002, leader professor Zoran Stanimirović.

Authors' contributions

IV participated in study design, sample collection, carried out histopathological and immunohistochemical examination and translated the manuscript. DM participated in study design and histopathological examination. VK participated in the immunohistochemical examination. MV carried out molecular examination - DNA isolation, PCR, c kit mutation analysis. MM carried out statistical analysis. SN participated in histopathological examination and analysed data. SAK conceived of the study, and participated in its design and coordination and helped to draft the manuscript. All authors read and approved the final manuscript.

Declaration of conflicting interests

The author(s) declared no potential conflicts of interest with respect to the research, authorship, and/or publication of this article.

REFERENCES

1. Welle MM, Bley CR, Howard J, Rufenacht S: Canine mast cell tumours: a review of the pathogenesis, clinical features, pathology and treatment. *Veterinary dermatology* 2008, 19(6):321-339.
2. Feghiu A, Crînganu D, Dumitrescu F, Pascal M, Vasilescu F, Militaru M: Nasal transmissible venereal tumor in a jack russel terrier bitch. *Acta Veterinaria - Beograd* 2015, 65(1):143-148.
3. Aleksić-Kovačević S, Kukolj V, Jelesijević T, Jovanović M: Retrospective analysis of canine mesenchymal tumors of skin and soft tissues. *Acta Veterinaria - Beograd* 2005, 55(5-6):521-529.
4. Strefezzi R, Xavier J, Kleeb S, Catão-Dias J: Prognostic indicators for mast cell tumors. *Brazilian Journal of Veterinary Pathology* 2009, 2(2):110-121.
5. Madewell BR, Munn RJ, Phillips LK: Ultrastructure of canine, feline, and bovine mast cell neoplasms. *American journal of veterinary research* 1984, 45(10):2066-2073.
6. Riva F, Brizzola S, Stefanello D, Crema S, Turin L: A study of mutations in the c-kit gene of 32 dogs with mastocytoma. *Journal of veterinary diagnostic investigation : official publication of the American Association of Veterinary Laboratory Diagnosticians, Inc* 2005, 17(4):385-388.
7. Jones CL, Grahn RA, Chien MB, Lyons LA, London CA: Detection of c-kit mutations in canine mast cell tumors using fluorescent polyacrylamide gel electrophoresis. *Journal of veterinary diagnostic investigation : official publication of the American Association of Veterinary Laboratory Diagnosticians, Inc* 2004, 16(2):95-100.
8. Kiupel M, Webster JD, Kaneene JB, Miller R, Yuzbasiyan-Gurkan V: The use of KIT and tryptase expression patterns as prognostic tools for canine cutaneous mast cell tumors. *Veterinary pathology* 2004, 41(4):371-377.
9. Webster JD, Yuzbasiyan-Gurkan V, Miller RA, Kaneene JB, Kiupel M: Cellular proliferation in canine cutaneous mast cell tumors: associations with c-KIT and its role in prognostication. *Veterinary pathology* 2007, 44(3):298-308.

10. Patnaik AK, Ehler WJ, MacEwen EG: Canine cutaneous mast cell tumor: morphologic grading and survival time in 83 dogs. *Veterinary pathology* 1984, 21(5):469-474.
11. Kiupel M, Webster JD, Bailey KL, Best S, DeLay J, Detrisac CJ, Fitzgerald SD, Gamble D, Ginn PE, Goldschmidt MH et al: Proposal of a 2-tier histologic grading system for canine cutaneous mast cell tumors to more accurately predict biological behavior. *Veterinary pathology* 2011, 48(1):147-155.
12. Sabbatini S, Scarpa F, Berlato D, Bettini G: Histologic grading of canine mast cell tumor: is 2 better than 3? *Veterinary pathology* 2015, 52(1):70-73.
13. Takeuchi Y, Fujino Y, Watanabe M, Takahashi M, Nakagawa T, Takeuchi A, Bonkobara M, Kobayashi T, Ohno K, Uchida K et al: Validation of the prognostic value of histopathological grading or c-kit mutation in canine cutaneous mast cell tumours: A retrospective cohort study. *The Veterinary Journal* 2013, 196(3):492-498.
14. Gil da Costa RM, Matos E, Rema A, Lopes C, Pires MA, Gartner F: CD117 immunexpression in canine mast cell tumours: correlations with pathological variables and proliferation markers. *BMC veterinary research* 2007, 3:19.
15. Thompson J: *Canine Mast Cell Tumors: Characterization of Subcutaneous Tumors and Receptor Tyrosine Kinase Profiling*. The University of Guelph; 2012.
16. Reguera MJ, Rabanal RM, Puigdemont A, Ferrer L: Canine mast cell tumors express stem cell factor receptor. *The American Journal of dermatopathology* 2000, 22(1):49-54.
17. Preziosi R, Morini M, Sarli G: Expression of the KIT protein (CD117) in primary cutaneous mast cell tumors of the dog. *Journal of veterinary diagnostic investigation : official publication of the American Association of Veterinary Laboratory Diagnosticians, Inc* 2004, 16(6):554-561.
18. Webster JD, Yuzbasiyan-Gurkan V, Kaneene JB, Miller R, Resau JH, Kiupel M: The role of c-KIT in tumorigenesis: evaluation in canine cutaneous mast cell tumors. *Neoplasia* 2006, 8(2):104-111.
19. Aleksić-Kovačević S, Kukolj J, Jelesijević T, Jovanović M: Retrospective analysis of canine mesenchymal tumors of skin and soft tissues. *Acta Veterinaria* 2005, 55(5-6):521-529.
20. Stevanović R, Vučićević I, Marinković D, Aleksić-Kovačević S: Morphology, gradation and frequency of mastocytoma in dogs. *Veterinarski glasnik* 2013, 67(3-4):153-162.
21. Romansik EM, Reilly CM, Kass PH, Moore PF, London CA: Mitotic index is predictive for survival for canine cutaneous mast cell tumors. *Veterinary pathology* 2007, 44(3):335-341.
22. Marinković D, Milčić-Matić N, Jovanović M, Vučićević I, Nešić S, Aničić M, Aleksić-Kovačević S: Morphological features and kit receptor expression in canine cutaneous mast cell tumor and systemic mastocytosis. *Acta Veterinaria* 2015, 65(2):226-237.
23. Sailasuta A, Ketpun D, Piyaviriyakul P, Theerawatanasirikul S, Theewasutrakul P, Rungsipipat A: The Relevance of CD117-Immunocytochemistry Staining Patterns to Mutational Exon-11 in c-kit Detected by PCR from Fine-Needle Aspirated Canine Mast Cell Tumor Cells. *Veterinary medicine international* 2014, 2014:787498.
24. Zemke D, Yamini B, Yuzbasiyan-Gurkan V: Mutations in the juxtamembrane domain of c-KIT are associated with higher grade mast cell tumors in dogs. *Veterinary pathology* 2002, 39(5):529-535.

EKSPRESIJA KIT RECEPTORA NA KUTANIM MASTOCITOMIMA PASA BEZ C-KIT MUTACIJA

VUČIĆEVIĆ Ivana, MARINKOVIĆ Darko, KUKOLJ Vladimir, VUČIĆEVIĆ Miloš, MIRILOVIĆ Milorad, NEŠIĆ Slađan, ALEKSIĆ-KOVAČEVIĆ Sanja

Histopatološko ispitivanje, gradacija, imunohistohemijsko bojenje i molekularno genetska ispitivanja su predloženi kriterijumi za klasifikaciju kutanih mastocitoma pasa. Prisustvo aberantne ekspresije CD117 i mutacija c-kit protoonkogeno moglo bi da bude indikativni parameter za finalnu histopatološku klasifikaciju mastocitoma. Glavni cilj ispitivanja je određivanje povezanosti mesta ekspresije KIT receptora i histološkog gradusa mastocitoma bez c-kit mutacija. Ispitivanjima su obuhvaćena 24 mastocitoma i 6 kontrolnih isečaka kože uzorkovanih od ukupno 30 odraslih pasa različitog uzrasta, rase i pola. Uzorci fiksirani u formalinu i ukalupljeni u parafinske kalupe su bojeni hematoksilin-eozinom, toluidin plavo metodom i imunohistohemijski primenom CD117 antitela. DNK je izolovana iz istih parafinskih kalupa, a PCR amplifikacija je izvršena primenom specifičnih prajmera PE1 i PE2. Stepen malignosti je utvrđen na osnovu prisustva mitotskih figura, multinuklearnih ćelija, ćelija sa bizarnim jedrom i kariomegalije na 10 polja velikog uveličanja. Na osnovu histopatoloških osobina, 14 od 24 mastocitoma su svrstani u visoki stepen maligniteta, dok je 10 mastocitoma niskog stepena maligniteta. Citoplazmatska ekspresija CD117 je uočena kod 9 od 14 mastocitoma visokog stepena maligniteta, što potvrđuje vezu između aberantne ekspresije CD117 i povećane ćelijske proliferacije.