

Case Report

MUCOMETRA IN A BITCH AS A CONSEQUENCE OF A SERIOUS PROFESSIONAL MISTAKE

ĐURIĆ Miloje¹, JOVANOVIĆ Ljubomir^{2*}, ANIČIĆ Milan³, NEDIĆ Svetlana¹,
NEDIĆ Sreten⁴

¹University of Belgrade, Faculty of Veterinary Medicine, Department of Obstetrics, Reproduction and Artificial Insemination, Belgrade, Serbia; ² University of Belgrade, Department of Physiology and Biochemistry, Belgrade, Serbia; ³University of Belgrade, Faculty of Veterinary Medicine, Department of Pathology, Belgrade, Serbia; ⁴University of Belgrade, Faculty of Veterinary Medicine, Ruminants and Swine Diseases, Belgrade, Serbia

Received 22 March 2017; Accepted 24 April 2017

Published online: 30 May 2017

Copyright © 2017 Đurić et al. This is an open-access article distributed under the Creative Commons Attribution License, which permits unrestricted use, distribution, and reproduction in any medium, provided the original work is properly cited.

Abstract

An apathetic 14-year-old Hungarian Puli bitch was presented with a seven day history of vaginal discharge and reported ovariohysterectomy (OHE) conducted six years ago. Clinical examination showed elevated body temperature (39.5°C), enlarged abdomen, and vulvar swelling. Despite a reported OHE in the anamnesis, ultrasound examination of the abdomen demonstrated the presence of both ovaries and a large anechogenic zone resembling the uterus. Vaginal cytologic examination and hormonal analysis indicated that the bitch was in the oestrus phase of the cycle. After laparotomy, both intact ovaries and an enlarged uterus with marked adhesions and filled with liquid content were visualised. The cervix was situated in the caudal part of the abdominal cavity and connected to the uterus by only an adhesion stump. After extirpation, uterus and ovarian tissue samples were sent for histological examination. Histological findings of uterus and ovarian tissue samples indicated a diagnosis of mucometra. Obviously, OHE was not conducted professionally, and the procedure performed only prevented conception, but ovaries and uterus continued to be active and caused a serious health disorder after six years. When only a part of the ovaries or uterus is left after OHE, health complications can appear up to ten years later. Our case testifies that even if both ovaries and the entire uterus are left after OHE without communication with cervix and vagina, a bitch can live without noticeable health disorders up to six years. This underlines the importance of lymphatic drainage and resorption processes in the uterus as well as evacuation of uterus content through the vagina.

Key Words: ovariohysterectomy, ovariectomy, ovarian remnant syndrome, uterus

*Corresponding author – e-mail: ljubomir.jovanovic@vet.bg.ac.rs

CASE PRESENTATION

An apathetic 14-year-old Hungarian Puli bitch was presented to the Ambulant Clinic at the Department of Obstetrics, Reproduction and Artificial Insemination, Faculty of Veterinary Medicine, University of Belgrade, Serbia. The owner had noted vaginal discharge, poor appetite, and polydipsia in the previous seven days. The owner also reported that ovariohysterectomy (OHE) had been conducted six years ago, but he periodically noticed vulvar discharge, without any other health problems.

Clinical examination showed elevated body temperature (39.5°C), enlarged abdomen, vulvar swelling and smelly vaginal discharge. Ultrasound examination of the abdomen demonstrated the presence of both ovaries and large anechogenic zone resembling the uterus, projection of which was more cranial than typical anatomical projection of uterus (Figure 1). Vaginal cytology with Diff Quick staining showed a large number of intermediate cells with pyknotic nuclei and a smaller percentage of superficial cells without nuclei. Basal cells, erythrocytes, and neutrophils were not found in the vaginal smear (Figure 2). This finding is characteristic for estrogenisation of vaginal epithelium. Haematological findings suggested leucocytosis, with neutrophilia (Table 1), while biochemical analysis showed no differences from physiological values except slightly increased concentrations of glucose and aspartate aminotransferase (AST) (Table 2). Oestradiol concentration was in a line with vaginal cytological examination and suggested that the bitch was in the oestrus phase of the cycle (Ball et al., 2010) (Table 3).

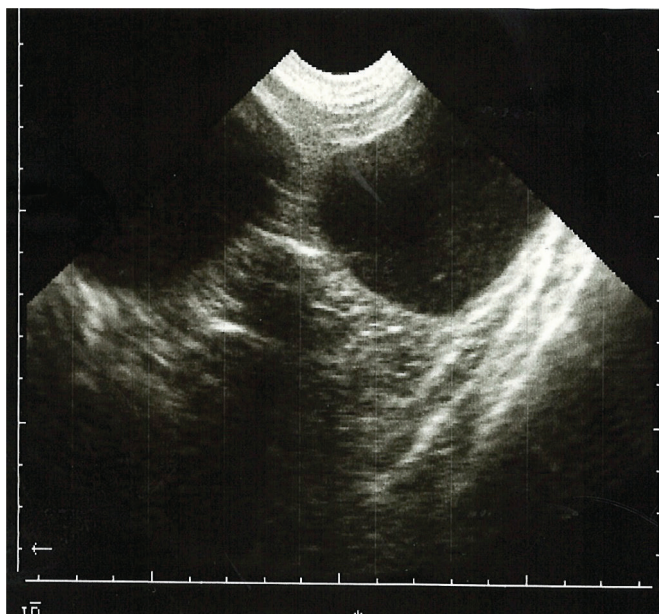


Figure 1 . Ultrasound examination of abdomen demonstrates presence of large anechogenic zone resembles like uterus

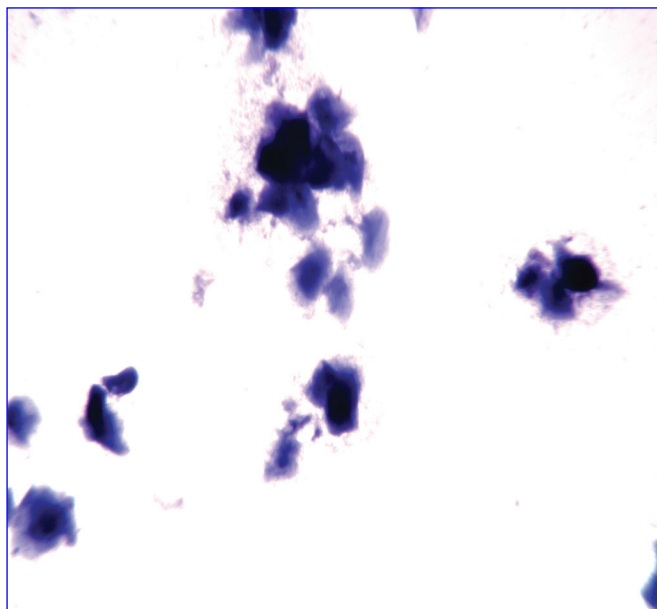


Figure 2. Vaginal cytologic examination characteristic for estrogenization of vaginal epithelium

Table 1. The results of haematological analysis of bitch blood sample and reference values

	Results of the analysis	Reference values
Number of erythrocytes	$6.17 \times 10^{12}/L$	5.50 - 8.50
Haemoglobin concentration	148.00 g/L	120.00 - 180.00
Haematocrit	43.4 %	37.00 - 55.00
MCV ¹	70.00 fL	60.00 - 77.00
MCH	24.00 pg	19.50 - 24.50
MCHC	341 g/L	320.00 - 360.00
RDW	12.00 %	12.00 - 16.00
Number of platelets	$845 \times 10^9/L$	200.00 - 500.00
MPV	8.50 fL	6.70 - 11.10
PCT	2.00 %	0.00 - 2.90
Number of leucocytes	$31.00 \times 10^9/L$	6.00 - 17.00
Differential white blood count		
Lymphocytes	6.30 %	12.00 - 30.00
Monocytes	1.90 %	3.00 - 10.00
Eosinophil	1.70 %	2.00 - 10.00
Granulocytes	90.10 %	60.00 - 80.00

¹MCV – average erythrocytes volume; MCH – average quantity of haemoglobin in erythrocytes; MCHC – average concentration of haemoglobin in erythrocytes; RDW - red cell distribution width; MPV – average platelets volume; PCT – platelet haematocrit

Table 2. The results of biochemical analysis of bitch blood sample and reference values

Parameter	Concentration in serum	Reference values
Total proteins	66.66 (g/L)	55.00 - 78.00
Albumins	36.48 (g/L)	27.00 - 44.00
Glucose	7.41 (mmol/L)	3.33 - 6.66
Bilirubin	6.39 (mmol/L)	0.90 - 10.50
Urea	7.15 (mmol/L)	3.10 - 10.90
Creatinine	56.00 (mmol/L)	<115.00
Calcium	2.68 (mmol/L)	2.00 - 3.00
Phosphorus	1.35 (mmol/L)	0.94 - 1.96
Cholesterol	7.43 (mmol/L)	3.00 - 6.60
Triglycerides	0.53 (mmol/L)	0.33 - 3.30
CK ¹	119.00 (IU/L)	59.00 - 895.00
ALT	221.00 (IU/L)	<100.00
ALP	113.00 (IU/L)	<200.00
AST	24.60 (IU/L)	5.00 - 55.00
γGT	4.70 (IU/L)	0.00 - 14.00
LDH	131.80 (IU/L)	20.00 - 500.00

¹CK – creatine kinase; ALT – alanine transaminase; ALP – alkaline phosphatase; AST – aspartate transaminase; γGT – gamma glutamyltransferase; LDH – lactate dehydrogenase

Table 3. The results of hormonal analysis of bitch blood sample

Parameter	Concentration in serum
Progesterone	0.40 (ng/mL)
Oestradiol	< 25.00 (pg/mL)

The presented findings were a clear indication for performing an explorative laparotomy and revision of the previous OHE. Anaesthesia was conducted in the following manner: premedication consisted of fentanyl (Rotexmedica GmbH Arzneimittelwerk), 10 mcg/kg BW, and medetomidine (Pfizer H.C.P. Corporation) 1mg/m² IM; anaesthesia induction consisted of propofol (B. Braun Melsungen AG) to effect (3mg/kg), ketamine (Richter Pharma Ag) 3mg/kg BW, and diazepam (Galenika AD) 0.25 mg/kg BW, IV; anaesthesia was maintained with propofol and ketamine (1/3 of V of initial dose) to effect; incision site and intraperitoneal/ovarium ligament block was performed with 2% lidocaine (Galenika AD). After laparotomy, both intact ovaries and the enlarged uterus with marked adhesions and filled with liquid content were visualised (Figure 3). The cervix was located in the caudal part of the abdominal cavity and connected to the uterus only with adhesion stump. Complete extirpation of both ovaries and uterus was performed.

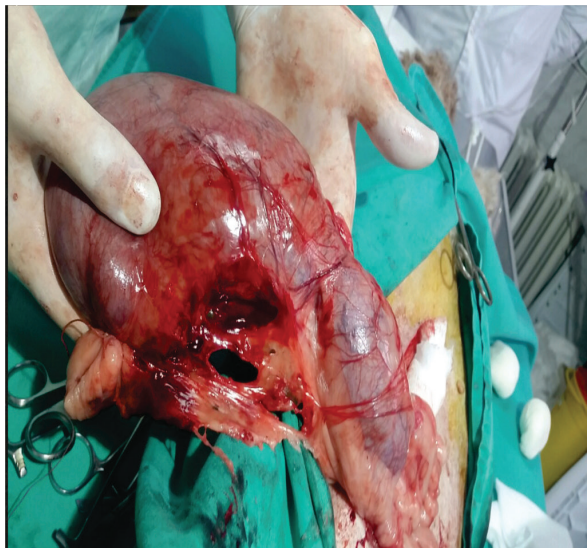

Figure 3. Enlarged uterus with marked adhesions and filled with liquid content

After surgical removal and macroscopic examination, tissue samples of the uterus and ovaries were collected for histological evaluation. Tissue samples were fixed in 10% buffered formalin during 48 hours. After standard processing in an automated tissue processor, tissue samples were embedded in paraffin blocks and 5 μ m-thick sections were stained with hematoxylin and eosin. The results of histochemical staining were analysed by light microscope (BX51, Olympus Optical, Japan), and pictures were taken with an Olympus ColorViewIII® digital camera. Macroscopic examination revealed cystic ovaries with cysts that varied in diameter from 4-8 mm. The uterine horns were remarkably distended and filled with a large amount of reddish, clear, viscous fluid. The endometrial mucosa had a haemorrhagic, granular and, cystic appearance (Figure 4, Figure 5).




Figure 4. Cystic and granular appearance of endometrial mucosa




Figure 5. Cystic ovaries with hemorrhagic and cystic appearance of endometrial mucosa

Microscopic examination of the ovaries revealed follicular cysts of different diameters, as well as marked congestion of the stromal blood vessels. Histopathological changes in the uterus were in the form of hyperplasia of the endometrial cuboidal epithelium, with focal, squamous metaplastic changes. Also, the endometrial glands were moderately dilated, and surrounding connective tissue was congested, oedematous and partly haemorrhagic. Multifocal necrotic foci with aggregation of neutrophil granulocytes were also noted (Figure 6, Figure 7, Figure 8). According to histological findings, mucometra was the final diagnosis in this case.

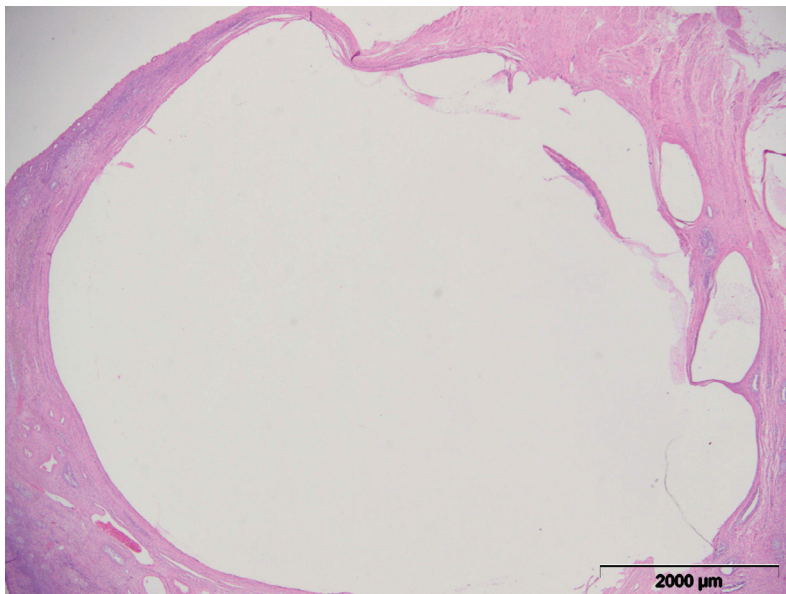


Figure 6. Large follicular cyst, HEx20

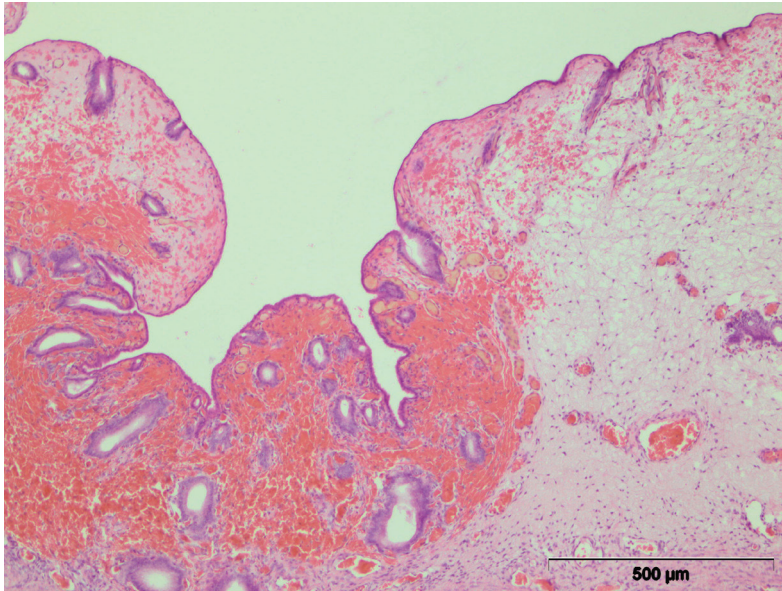


Figure 7. Edema and hemorrhagic connective tissue of endometrial lamina propria, HEx100

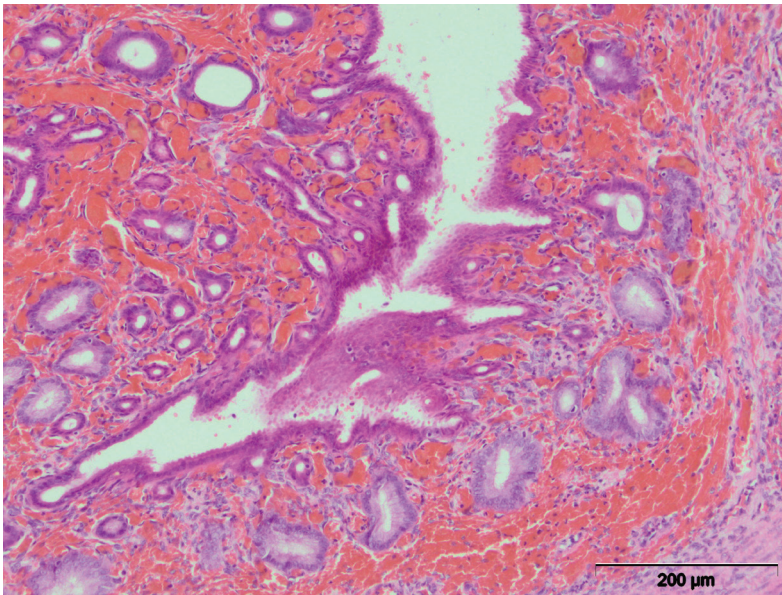


Figure 8. Squamous metaplastic epithelium and dilated endometrial glands, HEx200

DISCUSSION

Ovariectomy (OE) and OHE are among the most common surgical procedures in the small animal practice (Stockner, 1991). OE is often performed in young

animals as a preventive procedure, to avoid oestrus and pregnancy, and to prevent mammary tumours and hormone-dependent dermatitis. OHE is often performed in adult animals as therapy for specific pathological states such as: metritis, pyometra, uterine torsion, prolapse of the uterus, trauma, vaginal prolapse and vaginal neoplasia (Stone, 2003; Fingland, 1998; Wheeler et al., 1984). If all conditions which ensure a professional surgery are satisfied, there is little chance that intraoperative and postoperative complications will arise. Nevertheless, the most common complications include: bleeding from the place of ligation (usually from the ovarian pedicle), wound infections, peritonitis, postoperative evisceration, vaginal bleeding, fistulas (occur if stitching material is not appropriate), ureteral obstruction with consequent hydronephrosis, urinary incontinence, ovarian remnant syndrome (ORS) and stump pyometra (Goethem et al., 2006). Although OHE is one of the most common surgery treatments in the small animal practice, it needs correct surgical technique. If left in the abdomen, ovaries and uterus or their remaining parts continue to be active and can cause health disorders even years later, as was shown in our case.

Clinical findings in our case indicated that during previous surgery, which was conducted six years earlier, extirpation of ovaries and uterus was not conducted. Findings from our laparotomy showed that the veterinarian who performed the previous surgery made a single incision of the uterus, cutting it into two parts. This procedure prevented conception, but ovaries and uterus remained and continued to be active. This professional mistake finally led to serious health disorders. It should be emphasised that the repeated laparotomy and later extirpation of the ovaries and uterus carried a significantly higher risk of surgical bleeding and postoperative complications. Surgical revision in cases of suspected ORS requires proper surgical technique, and often it can be time-consuming and difficult for the surgeon to find and extirpate residual ovarian tissue, which is sometimes very small and poorly visible. In the case presented, surgical revision was somewhat easier because the residual uterine horns sufficed as a landmark that allowed easier visualization of both residual ovaries. However, during the surgery, a continuous danger of possible rupture of the uterus was present, which was amplified due to the highly strained walls and large amounts of connective tissue adhesions. Altogether, these factors significantly hampered correct exteriorisation.

Ball et al. (2010), in a study which included 21 animals, suggested that the period from OHE to ORS can vary from 1 to 120 months with a median of 17 months. In their study, only parts of ovarian tissue were left after OHE, which explained such a long period between OHE and ORS. In contrast, in our case, both ovaries and uterus remained after the first surgery, and it could be expected that clinical signs of health disorders would appear even earlier. Nevertheless, serious health disorders appeared only after six years. From clinical and pathological aspects, it is interesting that serious reproductive disorders and general health disorders in the bitch were not reported earlier. Although hormonally sensitised after the alleged OHE, the uterus managed to prevent serious pathological processes, probably due to the good health status of the

patient, lymphatic drainage and resorption. However, constant ovarian activity with the impossibility of physiological drainage through the cervix and vagina over time led to the accumulation of large amounts of liquid in the uterus, which could easily have caused a rupture of the uterus and jeopardized the life of the bitch.

According to the owner, after the first surgery, he was not made aware of postoperative care or any possible complications, and thus, he did not take any action to remedy temporary vaginal discharges. This serious professional mistake can suggest a lack of adequate OHE surgical technique and insufficient training of veterinary surgeons or even negligence.

Authors' contributions

MĐ performed clinical examination, therapy, surgical operation, and drafted the manuscript. LjJ helped in drafting the manuscript and technically prepared manuscript for submission. MA carried out histopatological examination. SN performed vaginal cytology examination. SN performed biochemical, hematological and hormonal examination.

Declaration of conflicting interests

The author(s) declared no potential conflicts of interest with respect to the research, authorship, and/or publication of this article.

REFERENCES

- Ball, R. L., S. J. Birchard, L. R. May, W. R. Threlfall, and G. S. Young. 2010. Ovarian remnant syndrome in dogs and cats: 21 cases (2000-2007). *Journal of the American Veterinary Medical Association* 236(5): 548-553. doi: 10.2460/javma.236.5.548.
- Fingland, R. B. 1998. Ovariohysterectomy. In *Current Techniques in Small Animal Surgery* (Fourth Edition), edited by M. J. Bojrab, 489-496, Williams & Wilkins, Baltimore, MD.
- Goethem, B., A. U. K. E. Schaefer, Okkens, and J. Kirpensteijn. 2006. Making a rational choice between ovariectomy and ovariohysterectomy in the dog: a discussion of the benefits of either technique. *Veterinary Surgery* 35: 136-143. doi: 10.1111/j.1532950X.2006.00124.x.
- Stockner, P. K. 1991. The economics of spaying and neutering: market forces and owners' values affecting pet population control. *Journal of the American Veterinary Medicine Association* 198: 1180-1182.
- Stone, A. E. 2003. Ovary and uterus. In *Textbook of Small Animal Surgery* (Third edition), edited by D. Slatter, 1495-1499, Saunders, Philadelphia, PA.
- Wheeler, S. L., M. L. Magne, and J. Kaufmann, J. 1984. Postpartum disorders in the bitch: a review. *Compendium on Continuing Education for the Practising Veterinarian* 6: 493.

MUKOMETRA KAO POSLEDICA OZBILJNE STRUČNE GREŠKE

ĐURIĆ Miloje, JOVANOVIĆ Ljubomir, ANIČIĆ Milan, NEDIĆ Svetlana,
NEDIĆ Sreten

Kratak sadržaj

Četrnaest godina stara kuja rase mađarski puli je dovedena u apatičnom stanju i sa anamnezom iscedka iz vagine koji je prisutan 7 dana. Prema rečima vlasnika ovariohisterektomija je urađena pre 6 godina. Kliničkim nalazom je utvrđena povišena telesna temperatura (39,5°C) uvećan abdomen i otok vulve. Uprkos podacima iz anamneze ultrazvučni pregled je ukazivao na prisustvo oba jajnika i velike anehogene zone koja je ukazivala na prisustvo materice. Citološki nalaz brisa vagine i hormonska analiza su ukazivali na to da je kuja bila u estralnoj fazi ciklusa. Nakon laparotomije potvrđeno je prisustvo oba jajnika i uvećane materice koja je bila ispunjena tečnim sadržajem i sa velikim brojem adhezija. Cerviks je bio lociran u kaudalnom delu abdomena i pričvršćen za uterus samo adhezionim patrljkom. Nakon ekstirpacije uterus i ovarijumi su poslani na histološku analizu, kojom je utvrđena dijagnoza mukometre. Očigledno da prethodno urađena ovariohisterektomija nije bila obavljena stručno i da je urađeni postupak sprečio koncepciju ali su ovarijumi i materica nastavili da budu aktivni što je prouzrokovalo ozbiljan zdravstveni problem 6 godina kasnije. Kada nakon ovariohisterektomije ostanu samo delovi tkiva ovarijuma i uterusa zdravstvene komplikacije se mogu javiti i do 10 godina nakon operacije. Prikazani slučaj svedoči o tome da je, čak i u slučaju kada su nakon operacije ostavljeni oba ovarijuma i uterus bez komunikacije sa cerviksom i vaginom, kuja 6 godina živela bez ozbiljnijih zdravstvenih problema. Ovo naglašava značaj limfne drenaže i procesa resorpcije sadržaja iz materice, pored pražnjenja kroz cerviks i vaginu.

Ključne reči: ovariohisterektomija, ovariektomija, sindrom zaostatka jajnika, materica