

What is your Diagnosis?

MAST CELL TUMOR WITHIN A LIPOMA IN A WHITE TOY POODLE

VUČIĆEVIĆ Ivana*, MARINKOVIĆ Darko, KUKOLJ Vladimir,
NESIĆ Slađan, ANIČIĆ Milan, ALEKSIĆ-KOVAČEVIĆ Sanja

Faculty of Veterinary Medicine, University of Belgrade, Serbia

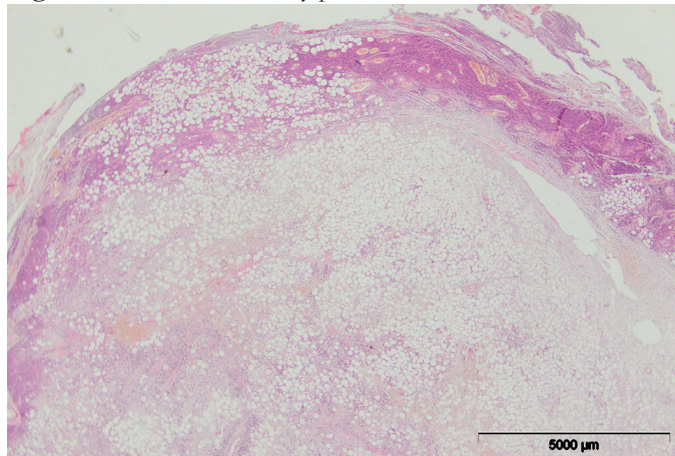
Received 11 June 2017; Accepted 17 December 2017

Published online: 06 February 2018

Copyright © 2018 Vučićević et al. This is an open-access article distributed under the Creative Commons Attribution License, which permits unrestricted use, distribution, and reproduction in any medium, provided the original work is properly cited.

STUDY TOPIC

Figure 1. Subcutis of the toy poodle



CASE PRESENTATION

An 11-year-old female white toy poodle was referred to the Veterinary Clinic due to the presence of a well-demarcated, soft, subcutaneous nodule in the lateral part of the chest. The overlying skin was intact and the nodule was movable (Figure 1). The size

*Corresponding author – e-mail: ivanav@vet.bg.ac.rs

of the nodule was 3x4 cm and it had grown to that size in a few months. Aside from the lesion on the chest, the dog was in good condition and healthy. Fine-needle aspirate was obtained from the mass for cytological examination, and it was stained with Diff-Quick stain. Cytological examination of the fine-needle aspirate obtained revealed the presence of numerous well-differentiated adipocytes with abundant cytoplasm and nuclei peripherally located, as well as round cells with eosinophilic granules in the cytoplasm, and a moderate number of eosinophil granulocytes. These findings indicated several differential diagnoses, such as mastocytoma, inflamed lipoma, or eosinophilic allergic dermatitis. After surgical removal of the mass, the tissue was fixed in 10% buffered formalin, processed by standard techniques and embedded in paraffin blocks. Tissue samples were stained using hematoxylin and eosin, and toluidine blue methods. Immunohistochemical analysis was performed for CD117 (KIT receptor).

INTERPRETATION

Histopathological examination of the subcutaneous nodule revealed the mass consisted of mature, well-differentiated adipocytes and a small amount of connective tissue. Multiple foci of round cells with granulated cytoplasm were present between the adipocytes. These neoplastic round cells were mostly uniform, except a small number of cells which showed slight polymorphism and were arranged in small sheets. Mitotic figures were rarely present, while eosinophil granulocytes were interspersed among the neoplastic cells. Toluidine blue staining showed metachromatic granules in the cytoplasm of mast cells (Figure 2a). The majority of neoplastic mast cells expressed KIT receptor on the cell membrane but not in the cytoplasm (Figure 2b). Cytological and histological examination, therefore, revealed a diagnosis of a mast cell tumor (MCT) within the lipoma, while histological and immunohistochemical characteristics indicated the observed MCT was of low-grade malignancy.

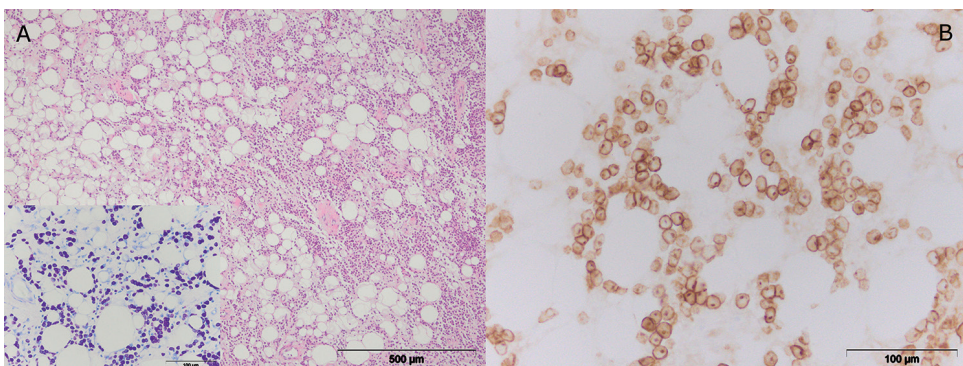


Figure 2. Microscopic and immunohistochemical changes in the skin of the dog with low grade mast cell tumour within lipoma: **a)** Mast cells arranged in a row, surrounded with adipocytes and separated by collagen bundles, HE. Insert: Cytoplasmic granules in the mast cells, TB; **b)** Membranous KIT-staining pattern, CD117, LSAB2

DISCUSSION

MCTs can be located in the epidermis or outer dermis when they are classified as cutaneous MCT, or below these anatomic structures when they are subcutaneous MCTs (Kiupel, 2017). While subcutaneous MCTs can often be completely surrounded by fatty tissue, this case was a rare occurrence of MCT within a lipoma in an 11-year-old female white toy poodle. It is infrequent in veterinary pathology to diagnose a primary malignant skin tumor within a benign tumor.

MCTs are one of the most frequent round cell tumors in dogs, comprising 7% to 21% of all skin tumors (Kiupel, 2017). Despite the fact that MCTs are one of the most common neoplasms in dogs, there is only one published case of a MCT within a lipoma (Jakab *et al.*, 2009). Histopathological examination is recommended for all clinically and cytologically suspicious nodes, especially in the case of the appearance of granulated mast cells in a cytological smear. Apart from confirming the diagnosis, histopathology is also used for determining the tumor grade. Several grading systems have been proposed for classifying canine MCTs (Kiupel *et al.*, 2011). Histopathologically, in our case, most of the neoplastic cells were uniform; the nuclei were large, while multinucleated cells and cells with bizarre nuclei were not present. Mitotic cells were rarely present. Karyomegaly was not observed. According to these characteristics and the grading proposal recommended by Kiupel *et al.* (2011), our MCT was of low-grade malignancy. Using toluidine blue staining as a confirmative method, the intracytoplasmic granules of the mast cells stained purple. Therefore, these neoplastic mast cells expressed only the membranous KIT staining pattern, which is in accordance with low-grade malignancy (Marinkovic *et al.*, 2015; Vucicevic *et al.*, 2016).

Authors contributions

IV participated in the histopathology analysis, carried out immunohistochemical staining and drafted the manuscript. DM conceived the study and participated in the histopathology analysis. VK participated in study design and histopathology analysis. SN helped to draft the manuscript and participated in the histopathology analysis. MA participated in the histopathology analysis and image preparation. SAK participated in the histopathology analysis, conceived and designed the study. All authors read and approved the final manuscript.

Competing interests

The authors declare that they have no competing interests.

REFERENCES

- Jakab, C., Szász, A. M., Kulka, J., Schaff, Z., Rusvai, M., Németh, T., Gálfi, P. 2009. Cutaneous mast cell tumour within a lipoma in a boxer. *Acta Veterinaria Hungarica*, 57:263-274. doi: 10.1556/AVet.57.2009.2.7
- Kiupel, M., Webster, J.D., Bailey, K.L., Best, S., DeLay, J., Detrisac, C.J., Fitzgerald, S.D., Gamble, D., Ginn, P.E., Goldschmidt, M.H., Hendrick, M.J., Howerth, E.W., Janovitz, E.B., Langohr, I., Lenz, S.D., Lipscomb, T.P., Miller, M.A., Misdorp, W., Moroff, S., Mullaney, T.P., Neyens, I., O'Toole, D., Ramos-Vara, J., Scase, T.J., Schulman, F.Y., Sledge, D., Smedley, R.C., Smith, K., Snyder, P., Southorn, E., Stedman, N.L., Steficek, B.A., Stromberg, P.C., Valli, V.E., Weisbrode, S.E., Yager, J., Heller, J., Miller, R. 2011. Proposal of a 2-tier histologic grading system for canine cutaneous mast cell tumours to more accurately predict biological behavior. *Veterinary Pathology*, 48:147-155. doi: <http://dx.doi.org/10.1177/0300985810386469>
- Kiupel, M. 2017. Mast cell tumours. In: *Tumours in Domestic Animals*, edited by Meuten D. J., 5th ed. 176-203. Ames: Iowa State University Press.
- Marinković, D., Milčić-Matić, N., Jovanović, M., Vučićević, I., Nešić, S., Aničić, M., Aleksić-Kovačević, S. 2015. Morphological features and kit receptor expression in canine cutaneous mast cell tumour and systemic mastocytosis. *Acta Veterinaria-Beograd*. 65(2): 226-237. doi: 10.1515/acve-2015-0019
- Vučićević, I., Marinković, D., Kukulj, V., Nešić, S., Aničić, M., Aleksić-Kovačević, S. 2016. Kit receptor expression in canine cutaneous mast cell tumours (CMCTS) without c-kit mutation. *Acta Veterinaria-Beograd*, 66:222-233. doi: <http://dx.doi.org/10.1515/acve-2016-0019>.

MASTOCITOM UNUTAR LIPOMA KOD BELE TOJ PUDLE

VUČIĆEVIĆ Ivana, MARINKOVIĆ Darko, KUKOLJ Vladimir,
NESIĆ Slađan, ANIČIĆ Milan, ALEKSIĆ-KOVAČEVIĆ Sanja

Kratka sadržaj

Uprkos činjenici da su mastocitomi jedna od najčešćih neoplazmi kod pasa, postoji samo jedan objavljeni slučaj mastocitoma u lipomu. U ovom slučaju, kod 11-godišnje ženke toj pudle primećeno je prisustvo dobro ograničene, pokretne, meko-elastične mase na lateralnoj strani grudnog koša. Histopatološki pregled je pokazao dobro ograničenu masu koja se sastojala od zrelih adipocita između kojih se nalaze skupine ćelija sa granuliranom citoplazmom. Bojenjem toluidin plavim je dokazano prisustvo metahromatskih granula u citoplazmi mastocita. Histopatološke i imunohistohemijske karakteristike ukazale su na to da je ispitan mastocitom niskog stepena maligniteta.