

Research article
COMPARATIVE PATHOMORPHOLOGICAL, MYCOLOGICAL AND MOLECULAR EXAMINATION OF TURKEY POULTS WITH DIFFERENT IMMUNOLOGICAL STATUS EXPERIMENTALLY INFECTED WITH *ASPERGILLUS FUMIGATUS*

JEZDIMIROVIĆ Nemanja^{1*}, KURELJUŠIĆ Branislav¹, IVETIĆ Vojin¹,
 KRNJAIĆ Dejan², RADANOVIĆ Oliver³, ŽUTIĆ Jadranka⁴, SPALEVIĆ Ljiljana⁵,
 JOVANOVIĆ Milijan⁶

¹Department of Pathology, Institute of Veterinary Medicine of Serbia, Belgrade, Serbia; ²Department of Microbiology, Faculty of Veterinary Medicine, Belgrade University, Serbia; ³Department of Microbiology, Institute of Veterinary Medicine of Serbia, Belgrade, Serbia; ⁴Department of Immunology, Institute of Veterinary Medicine of Serbia, Belgrade, Serbia; ⁵Department for Poultry Diseases, Institute of Veterinary Medicine of Serbia, Belgrade, Serbia; ⁶Department of Pathology, Faculty of Veterinary Medicine, Belgrade University, Serbia

(Received 06 February, Accepted 08 May 2019)

The aim of this study was to determine the pathological, mycological and molecular findings in turkey poults with different immunological status experimentally infected with *Aspergillus fumigatus*. The investigation was carried out 1, 3, 7, 14 and 21 days after intratracheal inoculation of 5.056×10^7 spores of *A. fumigatus* to 14-day-old turkey poults in group G-1, as well as to turkey poults in group G-2 which were treated prior to infection with dexamethasone. *A. fumigatus* was isolated on day 1 p.i. in both groups, but the number of positive samples was bigger in group G-1. *A. fumigatus* was isolated from the respiratory organs of group G-1 as early as on day 1 and 3 p.i. in 4 out of 12 examined specimens (33%). On day 7 p.i. *A. fumigatus* was possible to isolate from the respiratory organs of 50% of infected birds, on day 14 in 83.33% and on day 21 p.i. *A. fumigatus* was isolated in 6 out of 6 sacrificed turkey poults (100%). In dexamethasone-treated group *A. fumigatus* isolates from the respiratory organs on day 1 and 3 p.i. were same as in group G-1, whereas on days 7 and 14 p.i. the number of turkey poults positive to *A. fumigatus* increased in comparison with the untreated G-1 group. The histopathological lesions in turkey poults treated with dexamethasone developed earlier, were more intensive and extensive. The mycological and nested PCR results revealed a higher number of samples positive for the presence of *A. fumigatus* DNA in the group G-2, pretreated with dexamethasone.

Key words: *Aspergillus fumigatus*, turkey poults, respiratory organs, nested PCR

*Corresponding author: e-mail: jezdimitirovicnemanja@gmail.com

INTRODUCTION

Of all species of the *Aspergillus* genus which may cause aspergillosis in poultry, *Aspergillus fumigatus* is the primary causative agent. In turkeys, the disease occurs sporadically, often causing severe mortality in young birds and chronic illness in older ones [1].

The disease usually runs an acute or chronic course. Invasive aspergillosis is characterized by acute forms with variable morbidity and high mortality, rapid progression and poor prognosis. Clinical symptoms are characterized by dyspnoea, wheezing and abdominal distension due to ascites [2-4]. Chronic aspergillosis occurs after prolonged exposure of birds with impaired resistance to *A. fumigatus* spores. It usually happens in poultry at the age of 13-18 weeks [5-8,4,9].

Pathological lesions in birds are commonly confined to the lungs and air sacs, although infections of the oral mucosa, trachea, brain, eye, skin, bone, liver, kidney and the nasal passages have also been described. Typical lesions are characterized by granulomatous inflammation with necrosis, hemorrhage and the presence of intralesional fungal elements that are locally invasive [10]. Microscopic examination reveals the presence of granulomatous foci and necrosis with a surrounding region of proliferation including giant cells, macrophages, heterophils and lymphocytes and an outer capsule of connective tissue. Branching and septate mould hyphae are systematically observed within the lesions [7].

The study of aspergillosis in birds has been carried out in various species (chickens, ducks, turkeys, quails and domestic pigeons), of different ages, in both immunocompetent and immunosuppressed birds artificially infected with *Aspergillus* spp. conidia injected into the trachea, lungs or directly into the air sacs [11-14]. Although there are some reports on the pathogenesis of aspergillosis in turkey poults [7] little is known about the development of pathomorphological changes and distribution of the causative agent into different tissues, especially in immunosuppressed birds. For that reason, in this investigation immunocompetent and immunosuppressed (treated with dexamethasone) turkey poults were involved. The aim of this study was to determine the pathological, mycological and molecular findings by comparative investigation of artificially infected turkey poults with *A. fumigatus* 1, 3, 7, 14 and 21 days post-inoculation (p.i.).

MATERIAL AND METHODS

Animals. The experiment was conducted on 90 turkey poults, hybrid "Converter", of both sexes, divided into four experimental groups: infected groups G-1 and G-2 with 30 birds per group, and two control groups, G-3 and G-4, with 15 birds in each. The turkeys were housed in cages in separate boxes, with appropriate ambient conditions. Final disinfection with formaldehyde vapour was performed. The birds were fed *ad libitum* with feed made by Veterinary Institute Subotica intended for the corresponding

age category. Before use, the feed tested negative mycologically according to ISO 21527-2:2008 method. Fresh water disinfected by heat was continually available. The research was complied with all the relevant national regulations and institutional policies for the care and use of animals (Ministry of Agriculture and protection of the Environment, Veterinary Directorate, 30 June 2015, No. 323-07-05566/2015-05).

Aspergillus strain. For the experimental infection the reference strain of *A. fumigatus* ATCC 204305 (Stock No: 01021, Lot number: 1021-08), Kwik-stik™ 2 Pack (MicroBioLogics, USA) was used. According to the manufacturer's instructions, the suspension was seeded on 2 plates of Sabouraud dextrose agar. One plate was incubated at 25°C and the other one at 37°C, both for 48 hours. Thereafter, the colonies from both plates were transferred to 5 plates of Sabouraud dextrose agar and incubated at 25°C for 72 hours. *A. fumigatus* conidia were harvested with sterile distilled water and after centrifugation at 4°C for 5 minutes at 2000rpm, the spores were counted in a Neubauer chamber.

Experimental study. The turkeys (groups G-1 and G-2) were infected at the age of 14 days. On arrival and housing the birds were checked for any existing respiratory mould infection: 5 turkeys were killed and their lungs were examined by applying on Sabouraud dextrose agar at 25°C under aerobic conditions; the plates were checked for 7 days and proved negative.

Group G-1 was inoculated intratracheally with 0.3 ml of suspension containing approximately 5.056×10^7 spores. Turkey poults in group G-2 were treated for six days prior to infection with dexamethasone (Dexaveto® 0.2, V.M.D, Holland) at the dose of 4 mg/kg BW/day, administered intramuscularly. These were inoculated with *A. fumigatus* in the same manner and on the same day as G-1. The control group G-3 on the fourteenth day of age was intratracheally inoculated with 0.3 ml of isotonic sodium chloride solution. The control group G-4 was additionally treated with dexamethasone for six consecutive days prior to intra-tracheal inoculation with 0.3 ml of isotonic sodium chloride solution.

After the infection, the turkey poults were monitored three times daily in order to assess the clinical status in the p.i. period. The experiment lasted 21 days.

Six randomly selected turkey poults from G-1 and G-2 and three from G-3 and G-4 were culled by manual cervical dislocation method on days 1, 3, 7, 14 and 21 p.i., necropsied and their lungs, air sacs, livers, hearts and brains were collected for further examination.

Immunosuppression in groups G-2 and G-4 was proved by the percentage of heterophils and monocytes and percentage of lymphocytes and eosinophils in blood films stained with Giemsa - Wright's stain. In that manner the percentage of heterophils and monocytes was significantly increased, whereas the percentage of lymphocytes and eosinophils was significantly decreased by treatment with dexamethasone. Consequently, after treatment with dexamethasone, heterophil/lymphocyte ratio was significantly increased from 1.4 ± 0.26 to 2.5 ± 0.68 . Additionally, immunosuppression

was proved by cutaneous basophil hypersensitivity test, through the intradermal injection of phytohemagglutinin (PHA) for assessing cell mediated immunity. Skin swelling response was measured in millimeters on the interdigital skin. After 24 hours in G-1, G-2, G-3 and G-4 groups average values were: 2.50 ± 0.28 mm, 2.12 ± 0.18 mm, 2.29 ± 0.41 mm and 2.40 ± 0.21 mm, respectively. The obtained results confirmed immunosuppression in groups G-2 and G-4.

Mycological analysis. The organ samples were set on Sabouraud dextrose agar with 0.5% chloramphenicol and incubated for 5 days at 25°C under aerobic conditions. Sterile cotton swabs were used for sampling of air sacs. Species identification was done according to de Hoog *et al.* [15].

Histopathological analysis. Samples for histopathological study were fixed in 10% buffered formalin and after standard processing in an automated tissue processor (dehydration, illumination and impregnation), cast in paraffin blocks. The paraffin sections, 3-5µm thick, were stained with hematoxylin and eosin (HE), Grocott (Bio-Optica, Italy) and PAS method (Bio-Optica, Italy) for light microscopic examination.

Molecular analysis. The air sac swabs were prepared by immersing into sterile PBS and mixed vigorously in a vortex mixer. The organ samples (lung, liver, heart and brain) from G-1 and G-2 groups were prepared in pools weighing 1 gram composed of 6 samples of each organ (except for G-3 and G-4 groups where pools composed of 3 samples), homogenized in a mortar with a pestle, in sterile PBS to obtain the final dilution of 1:10. After homogenization, the sample suspensions were centrifuged for 10 min at 2,000 rpm. The supernatant was used for nucleic acid extraction.

DNA was isolated by using QIAamp DNA Mini Kit (Qiagen, Germany), following the recommended tissue protocols, with a slight modification. Namely, after the overnight incubation at 56°C with proteinase K and ALI, the samples were subjected to three cycles of freezing (1 min. in liquid nitrogen) and boiling (2 min.).

For the detection of *A. fumigatus* DNA, the nested-PCR protocol was carried out according to that described by Bansod *et al.* [16].

The first amplification was accomplished by using the primers AFU7S (5'CGG AAT TTA CCC AGC CCG'3) and AFU7AS (5'CGG AAT TTA CCC AGC CCG'3) which produced 405 bp amplicons. In order to increase the sensitivity, PCR products with no visible bands after the first round were used as the templates for the nested round with the primers AFU5S (5'AGG GCC AGC GAG TAC ATC ACC TTG'3) and AFU5AS (5'GG G (AG) GT TGC CAA CGT C (CT) C (CT) CC TGA'3) binding to the 18S rRNA sites specific to *A. fumigatus* yielding a final product of 236 bp.

The amplification products were electrophoresed on 2% agarose gel containing ethidium bromide, and visualized by UV transillumination. Thermo Scientific Gene Ruler 100 bp was used for the sizing of PCR products on the gel.

RESULTS

Clinical signs

Clinical signs appeared on the second day p.i. as depression and ruffled feathers. Respiratory dyspnea and nasal discharge appeared on day 4 p.i. in both groups, and was more intensive in group G-2. There were no clinical signs in groups G-3 and G-4. All the birds survived to the end of the experiment.

Macroscopic findings

At necropsy, focal air sac inflammation, lung oedema and hyperaemia were firstly observed in G-2 group on day 1 p.i. Diffuse air sac inflammation and lung granulomas were observed firstly in the G-2 group on day 3 p.i., while in the group G-1, on the 14th day p.i. There were no macroscopic lesions on the other organs.

Mycological and molecular analysis

Mycological and molecular findings obtained from the organs of turkey poult infected with *A. fumigatus* (groups G-1 and G-2) are presented in Table 1.

The results of mycological and molecular research showed that *A. fumigatus* was isolated from the air sacs and the lungs on days 1 and 3 post infection in 2 out of 6 (33.33%) turkey poult of the infected (G-1) group, as well as in the dexamethasone-treated and infected group (G-2). *A. fumigatus* DNA was detected in the pooled samples of air sacs and lungs.

On day 7 p.i. the causative agent was isolated in the lungs and air sacs in 3 out of 6 (50%) turkey poult in group G-1, and in 4 out of 6 (66.66%) in group G-2. *A. fumigatus* DNA was detected in pooled samples of air sacs and lungs in both infected groups (G-1 and G-2).

On day 14 the mould was isolated in 5 out of 6 (83.33%) turkey poult of group G-1 and in 6 out of 6 (100%) in group G-2, whilst on day 21 p.i. it was isolated from all sacrificed turkey poult from groups G-1 and G-2. On days 14 and 21 p.i. the presence of *A. fumigatus* DNA was confirmed in pooled samples of air sacs and lungs in both infected groups (G-1 and G-2). The causative agent was not isolated, but only detected in the livers of G-1 turkey poult on days 1, 14 and 21 p.i., whilst on days 7, 14 and 21 p.i. it was isolated from the liver of 2 out of 6 (33.33%) turkey poult in group G-2. In pooled liver samples *A. fumigatus* DNA was confirmed on days 7, 14 and 21 in G-2 group.

On day 7 p.i. the mould was detected in the heart of G-1 turkey poult, and isolated and detected in 1 out of 6 (16.66%) turkey poult in group G-2. On days 14 and 21 p.i. it was isolated and detected in 4 out of 12 (33%) G-1 and G-2 sacrificed turkey poult (Tab. 1).

Table 1. Mycological and molecular findings in turkey poult after inoculation of *A. fumigatus*
 Number of animals in which *A. fumigatus* was isolated (I) and its DNA detected (D)

		G R O U P S							
		G-1		G-2		G-3		G-4	
Days of sacrifice	Organs	I	D	I	D	I	D	I	D
1	Air sacs	2/6	+	2/6	+	0/3	-	0/3	-
	Lungs	2/6	+	2/6	+	0/3	-	0/3	-
	Liver	2/6	+	0/6	-	0/3	-	0/3	-
	Heart	0/6	-	0/6	-	0/3	-	0/3	-
	Brain	0/6	-	0/6	+	0/3	-	0/3	-
3	Air sacs	2/6	+	2/6	+	0/3	-	0/3	-
	Lungs	2/6	+	2/6	+	0/3	-	0/3	-
	Liver	0/6	-	0/6	-	0/3	-	0/3	-
	Heart	0/6	-	0/6	-	0/3	-	0/3	-
	Brain	0/6	-	0/6	+	0/3	-	0/3	-
7	Air sacs	3/6	+	4/6	+	0/3	-	0/3	-
	Lungs	3/6	+	4/6	+	0/3	-	0/3	-
	Liver	0/6	-	2/6	+	0/3	-	0/3	-
	Heart	0/6	+	1/6	+	0/3	-	0/3	-
	Brain	0/6	+	0/6	+	0/3	-	0/3	-
14	Air sacs	5/6	+	6/6	+	0/3	-	0/3	-
	Lungs	5/6	+	6/6	+	0/3	-	0/3	-
	Liver	0/6	+	2/6	+	0/3	-	0/3	-
	Heart	2/6	+	2/6	+	0/3	-	0/3	-
	Brain	0/6	+	3/6	+	0/3	-	0/3	-
21	Air sacs	6/6	+	6/6	+	0/3	-	0/3	-
	Lungs	6/6	+	6/6	+	0/3	-	0/3	-
	Liver	0/6	+	2/6	+	0/3	-	0/3	-
	Heart	2/6	+	1/6	+	0/3	-	0/3	-
	Brain	1/6	+	4/6	+	0/3	-	0/3	-

From both experimental groups 6 turkeys and from the control groups 3 turkeys were dispatched at each time of sacrifice

Group 1: Turkeys infected with *A. fumigatus*

Group 2: Turkeys infected with *A. fumigatus* after dexamethasone treatment

Group 3: Control group

Group 4: Control group treated with dexamethasone

+ DNA detected - DNA not detected

On day 7 p.i. *A. fumigatus* was detected in the brains of G-1 and G-2 turkey poult, and on day 14 it was detected in G-1 turkey poult, and isolated and detected in the brain of 3 out of 6 turkey poult (50%) in group G-2. On day 21 p.i. the mould was isolated from the brain of 1 out of 6 (16.66%) G-1 turkey poult. In G-2 turkey poult the causative agent was isolated and detected in the brains of 3 out of 6 (50%) turkey poult, as well as on day 14 p.i., and on day 21 p.i. it was isolated and detected in 4 out of 6 (66.66%) turkey poult. In addition, the mould was not detected in turkey poult in the control groups (G-3 and G-4) at any time of examination.

Histopathological findings

Group infected with *A. fumigatus* (G-1)

On the first day p.i. thickening of the pleura due to subpleural accumulation of serous fluid containing a few cells, mainly heterophils, was noticeable in the lungs. In the lung parenchyma there was diffuse hyperaemia and focal cellular periparabronchial infiltration. The cellular infiltrate consisted of heterophils, macrophages and lymphocytes. The lumen of the bronchiole and terminal alveoli was without odd contents. The bronchial epithelium was oedematous, with initial degenerative changes - vacuolisation, and the subepithelial lymphatic tissue was hyperplastic.

On day 3 p.i., the cellular infiltration was not limited only to the parabronchioli, but was present in other parts of the parenchyma, formed granulomas consisting of mononuclear cells, macrophages and lymphocytes. In the granuloma or in their immediate vicinity, 1-2 rather small multinuclear giant cells were noticeable (Figure 1A, Table 2). In this phase no regressive changes were seen in the granulomas.

Table 2. Specific lung lesions assessment on the various days p.i.

Days post infection	G-1					G-2				
	1.p.i.	3.p.i.	7.p.i.	14.p.i.	21.p.i.	1.p.i.	3.p.i.	7.p.i.	14.p.i.	21.p.i.
Solitary giant cell	-	+	+	-	-	-	-	-	-	-
Multiple giant cell	-	-	+	+	+	-	+	+	+	+
Granuloma without necrosis	-	+	+	-	-	-	-	-	-	-
Granuloma with necrosis	-	-	-	+	+	-	+	+	+	+
Confluent granuloma	-	-	+	+	+	-	-	+	+	+

Legend: - not present, + present

The air sacs were thick due to edema and infiltration with heterophils, macrophages and lymphocytes. The node-forming tendency of these cells was noticed, i.e. their tendency to form granulomas, but in this phase the presence of multinucleated giant cells was not clearly visible (Figure 1B). In the regions of intensive cellular infiltration the epithelium of the air sacs was absent.

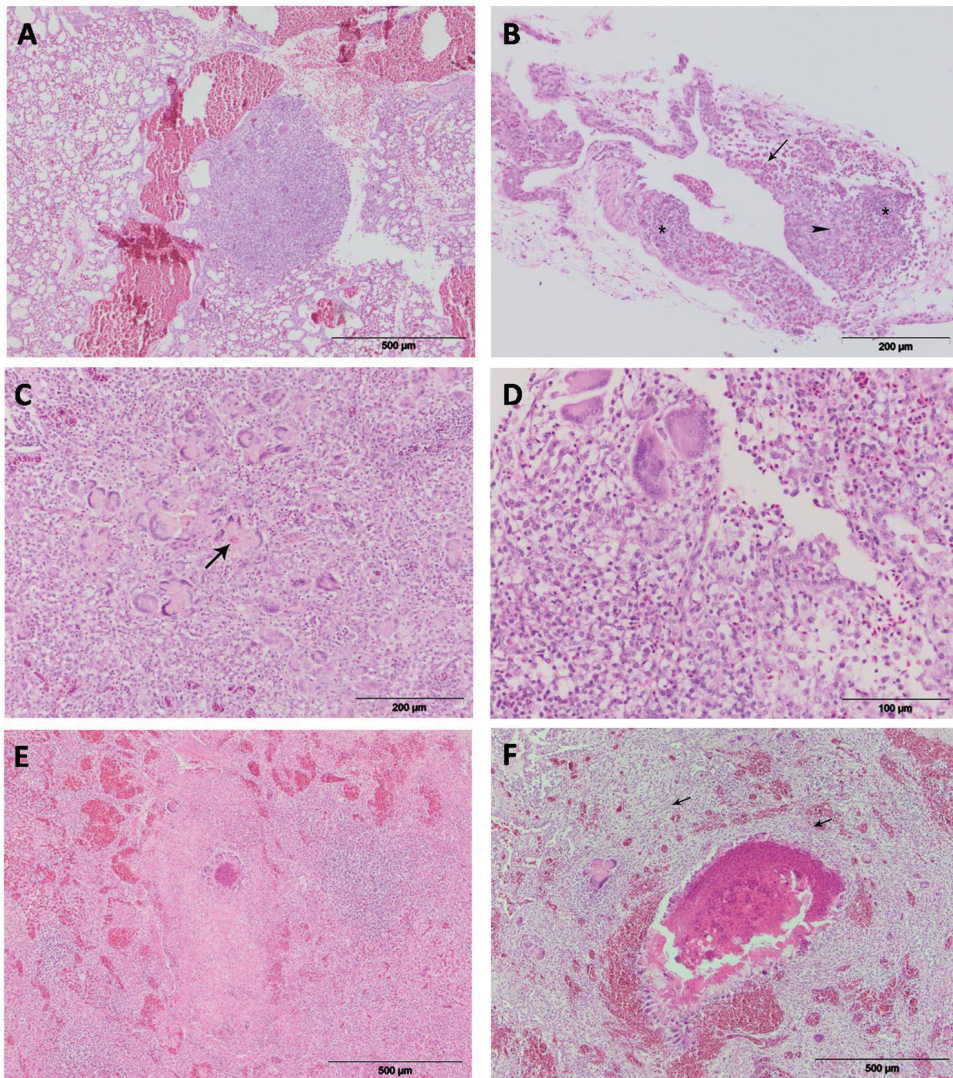


Figure 1. Histopathological changes in the turkey poults lungs and air sacs **a)** Granuloma and hyperemia in the lung parenchyma (G-1, 3 days p.i.), (HE); **b)** The thickening of the air sacs due to accumulation of heterophils (arrow), macrophages (arrowheads) and lymphocytes (asterisks) (G-1, 3 days p.i.), (HE); **c)** Initial necrosis in the center of the lung granuloma (arrow), surrounded by numerous giant cells, heterophils and lymphocytes (G-1, 7 days p.i.), (HE); **d)** Granuloma on the mucous membrane of bronchiole (G-1, 7 days p.i.), (HE); **e)** Moderate granulomatous lung inflammation (G-1, 14 days p.i.), (HE); **f)** Large lung granuloma with extended central necrosis surrounded by numerous giant cells and fibrous tissue (arrows) (G-1, 21 days p.i.), (HE)

On day 7 p.i. in the lungs numerous granulomas were noticed, which fused in certain regions and spread to wide areas of lung parenchyma. Central parts of the granulomas consisted of epithelioid and giant cells, whilst on the periphery there were more lymphocytes and heterophils. Apart from solitary cases in giant cells, necrotic changes in this phase of the disease in this animal group were not noticeable (Figure 1C). Granulomas of the same composition were noticed on the mucous membranes of bronchioli and on air sacs (Figure 1D).

On day 14 p.i. an increasing number of granulomas and diffuse infiltration with heterophils, macrophages and lymphocytes were noticed in the lungs. On the vast majority of granulomas necrotic lesions occurred, which were located in the central parts of the granulomas and were homogenous, eosinophilic in appearance, with visible remnants of cellular nuclei in their centre. The necrotic areas were surrounded by wreaths of multinucleated cells, and an intensive infiltrate consisting of macrophages, heterophils and lymphocytes spread to the periphery (Figure 1E). In the immediate vicinity of these changes, areas of intensive hyperaemia were present. Regressive changes were visible also in the granulomas in the air sacs.

On day 21 p.i. the changes in the lungs and air sacs were similar to those already described regarding their character and intensity, with the exception of necrotic lesions, which were generally more intensive. The necrotic areas spread to large parts of the granulomas, they were also located in the centre and usually surrounded by numerous multinucleated giant cells which formed a wreath. On the periphery of the granulomas the presence of fibrous tissue fibres was noticeable (Figure 1F).

Mould elements, such as hyphae and conidia, were present and visible in areas of the affected lungs and air sacs. The presence of moulds, especially hyphae, was already visible after routine staining with HE, but was more noticeable in slides stained using PAS and Grocott's stain methods. They were located in the central parts of the granulomas, and were present especially in the necrotic areas (Figure 2A). They were also detected in multinucleated giant cells. The presence of the moulds in macrophages was especially prominent in older larger granulomas in turkey poult sacrificed on day 21 p.i.

In other organs which were subjected to inspection – the brain, heart, liver – in groups G-1 and G-2, histopathological changes were not found.

Group treated with dexamethasone and infected with *A. fumigatus* (G-2)

In the G-2 group examined on day 1 p.i. the pleura thickening due to oedema and infiltration with numerous heterophils and a few macrophages and lymphocytes was noticed. The lung parenchyma was hyperaemic, also infiltrated with heterophils, macrophages and lymphocytes. In the alveoli in certain areas the accumulation of a homogenous, eosinophilic substrate was visible.

On day 3 p.i. in the lungs of turkey poult clearly formed granulomas consisting of large numbers of multinucleated giant cells, epithelioid cells, macrophages, lymphocytes and heterophils were found. The multinucleated giant cells were of various sizes and shapes, so that in the same granuloma there were both Langhans type cells and

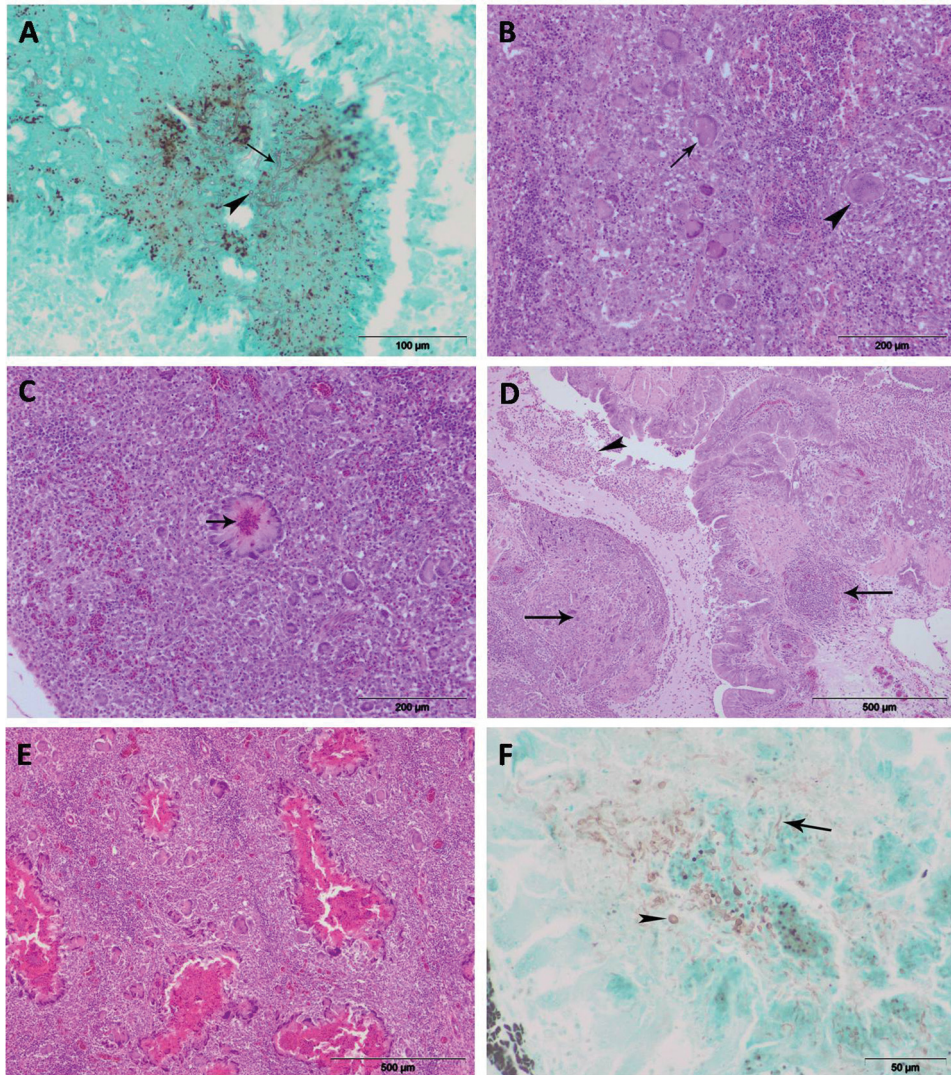


Figure 2. Histopathological changes in the turkey poult lungs **a)** Arborized and septed hyphae (arrow) and spores (arrowhead) visible in the central part of the lung granuloma (G-1, 14 days p.i.), (Grocott); **b)** Langhans type giant cell (arrow) and foreign-body giant cell (arrowhead) in lung granuloma (G-2, 3 days p.i.), (PAS); **c)** Necrosis in the lung granuloma center (arrow) surrounded by rim of giant cells (G-2, 3 days p.i.), (PAS); **d)** Bronchial granulomas (arrows) in the mucosa (left) and submucosa (right). Exudate (arrowhead) with heterophils and sparse lymphocytes (G-2, 3 days p.i.), (HE); **e)** Numerous confluent lung granulomas with extensive necrosis (G-2, 21 days p.i.), (HE); **f)** Hyphae and spores in the lung granuloma (G-2, 21 days p.i.), (Grocott)

foreign-body giant cells (Figure 2B). In a small number of granulomas initial regressive changes were noticed, with central necrosis usually surrounded by multinucleated giant cells which formed a wreath of cells (Figure 2C, Table 2).

In the same period in the mucosa of the bronchus and bronchioles granulomas of the same composition as of those in the lung parenchyma, with clearly formed multinucleated giant cells were noticed (Figure 2D). The lumen of bronchioli was filled with homogenous mucous contents which contained numerous cells, mainly heterophils, and a small number of lymphocytes.

In this group of sacrificed turkey poult the changes on the air sacs were seen as diffuse thickening due to edema and intensive infiltration with heterophils, macrophages, epithelioid and multinucleated giant cells. Granulomas were not clearly defined, and the necrotic areas did not clearly show up.

On day 7 p.i. consolidation and severe infiltration with cells which formed confluent granulomas were seen in the lungs. Central parts of granulomas were filled with eosinophilic necrotic debris in which remnants of cellular detritus were visible. The necrotic debris was also surrounded by a wreath of multinucleated giant cells.

The necrotic changes in this period were also prominent in the granulomas located in the mucous membrane and submucosa of the bronchus and bronchioli.

On day 14 p.i. the granulomas were of similar composition and appearance as in turkey poult sacrificed previously. There was a noticeable difference in the size of necrotic areas, which spread to the major parts of the granulomas in this period. The eosinophilic necrotic debris was becoming almost homogenous; the remnants of cellular nuclei were less noticeable.

There was a great thickening of the air sacs, which were pervaded with confluent granulomas. In the central parts of the granulomas necrotic changes were readily noticeable.

On day 21 p.i. the changes in the lungs and air sacs advanced: both, granuloma number and size were larger. In this group a large number confluent granulomas with extensive necrosis was noticed (Figure 2E).

Mould elements – hyphae and spores – were visible from day 1 p.i. The moulds were noticed between infiltrating cells, in the necrotic areas of the granulomas, as well as in the cytoplasm of multinucleated giant cells (Figure 2F).

On other organs which were examined (liver, hearth and brain) in this group, as well as in the previous one, histopathological changes were not noticed.

DISCUSSION

Experimental infection of birds with *A. fumigatus* can be achieved by inoculation of the spores by various means [17,11,12]. Some of these routes of inoculation have

certain drawbacks because the dose of *A. fumigatus* spores each bird was given cannot be determined, and by some means of application the proximal part of the respiratory system and its defense mechanisms are being more or less avoided, which renders the explanation of pathogenesis of spontaneous infection difficult [18]. In the current research two-week-old turkey poults were experimentally infected by individual intratracheal inoculation of suspension containing 5.056×10^7 *A. fumigatus* spores per bird. This dose did not lead to mortality during the three weeks of the experiment. The approximate dose of *A. fumigatus* spores applied into the air sacs in 18-week-old turkeys did not result in deaths also [10]. However, Arne *et al.* [19] claim that 1.2×10^7 spores inoculated into the trachea lead to death in 20% treated 2-week-old Japanese quails. Experimental infection of three-week-old turkey poults with aerosol containing spores, which were applied in the concentration of 5×10^5 spores per gram of lungs resulted in 50% mortality [20]. Stress and immunosuppression caused by dexamethasone lead to 100% mortality in pigeons infected with *A. fumigatus* spores inoculated into the lungs [21].

On the first day p.i. in this investigation, pulmonary hyperaemia and oedema were dominant with initial focal or diffuse cellular infiltration. Similar findings in the first days of *Aspergillus* infection were described by Julian and Gory [17], who also reported the dominance of fibrin and fibrinous pneumonia as the first changes in further evolution of the pathological process.

From day 3 to 21 p.i. granulomatous pneumonia was dominant. Regressive changes (necrosis) in the central part of the granulomas were first detected on day 7 p.i., and were prominent on days 14 and 21 p.i. However, Kunkle and Rimler [10] found granulomatous changes with necrosis as early as 72 h p.i., which might be related to a different application route, dose or higher virulence of the strain.

Mould elements were found in the cytoplasm of multinucleated giant and epithelioid cells, which is in accordance with the claims of other authors [10]. The presence of germinative stages of the mould in blood vessels, which proves their haematogenic dissemination [10], was not detected in the current research.

Similar granulomatous forms were described by some other researchers [22-26,5]. Sutton *et al.* [25] suggested the possibility that the moulds proliferate inside the granulomas, which gradually increase in size, and that the mould toxins and enzymes do damage to the tissues. According to some authors [22,27,26] extensive tissue necrosis results from the effects of *A. fumigatus* elastase and gliotoxin, which inhibits phagocytosis or impair the cooperation of B and T lymphocytes. In the opinion of Kwon-Chung [28] and Ben-Ami [29] the angiotoxic effect of gliotoxin is responsible for the onset of invasive aspergillosis. A similar effect is exerted by the metabolite fumagillin, which inhibits the proliferation of endothelial cells [30].

Significant histopathological findings observed on day 3 p.i. in turkey poults pretreated with dexamethasone and infected with the mould was granulomatous bronchitis. Similar findings were described in chickens which died 15 days p.i. and in which 85%

of the parabronchi were obturated with fibrin, necrotic detritus and granulomas [17]. Macroscopic and histopathological findings in the current research proved that in turkey poults experimentally infected with *A. fumigatus* necrotic granulomatous pneumonia was established. The comparison of findings in the two infected groups - those which were and which were not pretreated with dexamethasone - detected certain differences in the evolution, character and the intensity of pathological changes.

Mycological testing of lung tissue samples and the air sacs of infected turkey poults each day of sacrifice proved the isolation of *A. fumigatus* from the respiratory organs as early as on days 1 and 3 p.i. It was detected that on days 7 and 14 p.i. the number of isolates of *A. fumigatus* from the respiratory organs of turkey poults infected and pretreated with dexamethasone was higher than in those infected but not pretreated. This small increase in the number of isolates on days 7 and 14 p.i. resulted from the influence of dexamethasone on cellular immunity: it decreases the number of macrophages and their phagocytic activity in the alveolae, as well as the numbers of macrophages in the circulation. Dexamethasone does not influence neither the concentration of interleukins and interferons, nor the number of neutrophils in murine model of aspergillosis [31].

Dexamethasone pretreatment in our study did not increase significantly the number of turkey poults in which *A. fumigatus* was isolated from the heart in comparison to the corresponding number in not pretreated but only infected turkey poults; it only shortens the time of initial isolation from the heart (day 7 p.i.) in comparison to the birds which were only infected but were not administered dexamethasone (day 14 p.i.). Similar results of isolation of the mould from the heart were published by Martin *et al.* [8] in five-week-old turkeys spontaneously infected with *Aspergillus* spp. Mycological findings in the heart confirmed the hematogenic spread of *A. fumigatus*, especially 14 and 21 days p.i.

This investigation proved that dexamethasone increased the number of *A. fumigatus* isolates from the brain tissue, but the isolation is possible not before two weeks p.i.

Molecular detection of *A. fumigatus* in pooled samples of lungs and air sacs, heart, liver, and brain of turkey poults on day 1, 3, 7, 14 and 21 p.i. revealed higher numbers of positive samples in G-2 group. This finding possibly results from the immunosuppressive effect of dexamethasone, which decreases the haemotaxis and the phagocytic activity of lymphocytes and macrophages, which are known to play the main role in the immune response [32]. Further, the isolation and detection of the mould from the organs (the heart, liver and brain) of turkey poults treated with dexamethasone was possible sooner than in those which were not pretreated.

It has been known that stress and glucocorticoids primarily decrease the activity of macrophages, which eliminate the conidia of *A. fumigatus* from tissues and organs [2]. Besides, it was proven that glucocorticoids decrease the production and the activity of polymorphonuclear leucocytes, which are capable of damaging the hyphae. Dexamethasone exerts a stronger direct effect on the cells with anticonidial activities

than on *A. fumigatus* itself. However, some authors claim that cortisone exerts effect on *A. fumigatus*, increases the metabolic activity of hyphae and stimulates moderate growth [2].

In this investigation the histopathological changes in turkey poultts treated with dexamethasone prior to infection with *A. fumigatus* developed earlier, were more intensive and extensive, but also the regressive changes were more extensive and occurred earlier. The analysis of the results obtained with the nested PCR revealed a higher number of samples positive for the presence of *A. fumigatus* DNA in the group pretreated with dexamethasone.

Acknowledgements

This work was supported by the Ministry of Education, Science and Technological Development, Republic of Serbia (Grant No. III46009). We are very grateful to dr Vesna Milićević and dr Božidar Savić, for their assistance and suggestions in the preparation of the manuscript for publication.

Authors' contributions

JN carried out the experimental study, histopathological and molecular study as well, and drafted the manuscript. KB carried out the experimental study and participated in writing. IV participated in the design of the study and performed the histopathological analysis. KD helped to draft the manuscript. RO and ŽJ participated in mycologicam analysis and writing. SLj carried out the experimental study and helped to draft manuscript. JM participated in the design of the study, performed the histopathological analysis, took microphotographs and participated in writing. All authors read and approved the final manuscript.

Declaration of conflicting interests

The author(s) declared no potential conflicts of interest with respect to the research, authorship, and/or publication of this article.

REFERENCES

1. Peden WM, Rhoades KR: Pathogenicity differences of multiple isolates of *Aspergillus fumigatus* in turkeys. *Avian Dis* 1992; 36: 537-542.
2. Latge JP: *Aspergillus fumigatus* and aspergillosis. *Clin Microbiol Rev* 1999, 12 (2): 310-350.
3. Charlton BR, Chin RP, Barnes HJ: Fungal infections. In: *Diseases of poultry*. 12th edn, Blackwell Publishing; Iowa; 2008, 989-998.
4. Zafra R, Perez J, Perez-Ecija RA, Borge C, Bustamante R, Carbonero A, Tarradas C: Concurrent aspergillosis and ascites with high mortality in farm of growing broiler chickens. *Avian Dis* 2008, 52(4): 711-713.

5. Akan M, Haziroglu R, Ilhan Z, Sareyyupoglu B, Tunca R: A case of Aspergillosis in broiler breeder flock. *Avian Dis* 2002, 46: 497-501.
6. Leishangthem GD, Singh ND, Brar RS, Banga HS: Aspergillosis in Avian Species: A Review. *Journal of Poultry Science and Technology* 2015, 3: 1-14
7. Femenia F, Fontaine JJ, Lair-Fullerenger Berkova N, Huet D, Towanou N, Rakotovao F, Grenet OI, Le-Loch G, Arne P, Guillot J: Clinical, mycological and pathological findings in turkeys experimentally infected by *Aspergillus fumigatus*. *Avian Pathol* 2007, 36(3): 213-219.
8. Martin MP, Bouck KP, Helm J, Dykstra MJ, Wages DP, Barnes HJ: Disseminated *Aspergillus flavus* Infection in Broiler Breeder Pullets. *Avian Dis* 2007, 51: 626-631.
9. Kapetanov M, Potkonjak D, Milanov D, Stojanov I, Živkov-Balaš M, Prunić B: Investigation of dissemination of aspergillosis in poultry and possible control measures. *Zb Matice Srp Prir Nauk* 2011, 120, 267-276.
10. Kunkle RA, Rimler RB: Pathology of acute aspergillosis in turkeys. *Avian Dis* 1996, 40(4): 875-886.
11. Steinbach WJ, Benjamin DK, Trasi SA, Miller JL, Schell WA, Zaas AK, Foster WM, Perfect JR: Value of an inhalational model of invasive aspergillosis. *Med Mycol* 2004, 42 (5): 417-425.
12. Beernaert LA, Pasmans F, Haesebrouck F, Martel A: Modelling *Aspergillus fumigatus* infections in racing pigeons (*Columba livia domestica*). *Avian Pathol* 2008, 37(5): 545-549.
13. Dagenais TR, Keller NP: Pathogenesis of *Aspergillus fumigatus* in invasive aspergillosis. *Clin Microbiol Rev* 2009, 22(3): 447-465.
14. Thierry S, Durand B, Melloul E, Tafani JP, Wang DY, Deville M, Cordonnier N, Chermette R, Guillot J, Arne P: Assessment of *Aspergillus fumigatus* pathogenicity in aerosol-challenged chickens (*Gallus gallus*) belonging to two lineages. *Comp Immunol Microbiol Infect Dis* 2013, 36(4): 379-385.
15. de Hoog GS: Atlas of clinical fungi. 2000:1-1126
16. Bansod S, Gupta I, Rai M: Specific detection of *Aspergillus fumigatus* in sputum sample of pulmonary tuberculosis patients by two-step PCR. *Afr J Biotechnol* 2008, 7 (1): 16-21.
17. Julian RJ, Goryo M: Pulmonary aspergillosis causing right ventricular failure and ascites in meat-type chickens. *Avian Pathol* 1990, 19 (4): 643-654.
18. Fedde M.R: Relationship of structure and function of the avian respiratory system to disease susceptibility. *Poultry Sci* 1998, 77(8): 1130-1138.
19. Arne P, Thierry S, Wang D, Deville M, Le Loch G, Desoutter A, Femenia F, Nieguitsila A, Haung W, Chermette R, Guillot J: *Aspergillus fumigatus* in Poultry. *Int J Microbiol* 2011, 14 pp.
20. Richard JL, Cutlip RC, Thurston JR, Songer J: Response of turkey poults to aerosolized spores of *Aspergillus fumigatus* and aflatoxigenic and nonaflatoxigenic strains of *Aspergillus flavus*. *Avian Dis* 1981, 25(1): 53-67.
21. Le Loch G, Arne P, Bougerot C, Risi E, Pericard JM, Quinton JF, Bretagne S, Guillot J: Detection of circulating serum galactomannan for the diagnosis of avian aspergillosis. 16th Congress of the International Society for Human and Animal Mycology (ISHAM), June 25-29 th, 2006. Paris.
22. Mullbacher A, Waring P, Eichner RD: Identification of agent in cultures of *Aspergillus fumigatus* displaying anti-phagocytic and immunomodulating activity in vitro. *J Gen Microbiol* 1985, 131: 1251-1258.

23. Cacciottolo E, Rossi G, Nardoni S, Legrottaglie R, Mani P: Anatomopathological aspects of avian aspergillosis. *Vet Res Commun* 2009, 33: 521-527.
24. Sutton P, Newcombe NR, Waring P, Mullbacher A: In vivo immunosuppressive activity of gliotoxin, a metabolite produced by human pathogenic fungi. *Infect Immun* 1994, 62: 1192-1198.
25. Sutton P, Waring P, Mullbacher A: Exacerbation of invasive aspergillosis by the immunosuppressive fungal metabolite. *Immunol Cell Biol* 1996, 74: 318-322.
26. McCormick A, Loeffler J, Ebel F: *Aspergillus fumigatus*: contours of an opportunistic human pathogen. *Cell Microbiol* 2010, 12: 1535-1543.
27. Monod M, Paris S, Sanglard D, Jatton-Ogay K, Bille J, Latgé JP: Isolation and characterisation of a secreted metalloprotease of *Aspergillus fumigatus*. *Infect Immun* 1993, 61, 4099-4104.
28. Kwon-Chung KJ, Bennett JE: *Medical mycology*. Lea and Febiger, 1992, Philadelphia.
29. Ben-Ami R, Lewis RE, Leventakos K, Latgé JP, Kontoyiannis DP: Cutaneous model of invasive aspergillosis. *Antimicrob Agents Chemother* 2010, 54: 1848-1854.
30. Rementeria A, López-Molina N, Ludwig A, Vivanco AB, Bikandi J, Pontón J, Garaizar J: Genes and molecules involved in *Aspergillus fumigatus* virulence. *Rev Iberoam Micol* 2005, 22 (1): 1-23.
31. Matsuse H, Fukushima C, Fukahori S, Tsuchida T, Kawano T, Nishino T, Kohno S: Differential effects of Dexamethasone and Itraconazole on *Aspergillus fumigatus* – exacerbated allergic airway inflammation in a murine model of mite - sensitized asthma. *Basic Sci Invest* 2013, 85:429-435.
32. Shi Bao Z, You G, Li Wen-Bin, Jiang T: A single *Aspergillus fumigatus* intracranial abscess in an immunocompetent patient with parietal lobe tumorectomy, *World J Surg Oncol* 2014, 12:181

KOMPARATIVNA PATOMORFOLOŠKA, MIKOLOŠKA I MOLEKULARNA ISPITIVANJA ČURIĆA RAZLIČITOG IMUNOLOŠKOG STATUSA EKSPERIMENTALNO INFIGIRANIH *ASPERGILLUS FUMIGATUS*

JEZDIMIROVIĆ Nemanja, KURELJUŠIĆ Branislav, IVETIĆ Vojin, KRNJAIĆ Dejan, RADANOVIĆ Oliver, ŽUTIĆ Jadranka, SPALEVIĆ Ljiljana, JOVANOVIĆ Milijan

Cilj ovog ispitivanja je bio da se utvrde patološki, mikološki i molekularni nalazi kod čurića različitog imunološkog statusa koji su eksperimentalno inficirani sa *Aspergillus fumigatus*. Ispitivanja su obavljena 1., 3., 7., 14. i 21. dana nakon intratrahealne inokulacije $5,056 \times 10^7$ spora *A. fumigatus* kod 14 dana starih čurića grupe G-1, kao i grupe čurića G-2 prethodno tretirane deksametazonom. *A. fumigatus* je izolovan prvog dana p.i. u obe grupe, ali je broj pozitivnih uzoraka bio veći u grupi G-2. *A. fumigatus* je izolovan iz respiratornih organa grupe G-1 već 1. i 3. dana u 4 od 12 ispitivanih uzoraka (33%). Sedmog dana p.i. *A. fumigatus* je bilo moguće izolovati iz respiratornih organa

50% inficiranih ćurića, 14. dana u 83.33%, a 21. dana *A. fumigatus* je izolovane kod 6 od 6 žrtvovanih ćurića (100%). U grupi ćurića prethodno tretiranoj deksametazonom izolacija iz respiratornih organa 1 i 3 dana p.i. je bila ista kao u grupi G-1, dok se 7 i 14 dana p.i. broj izolata *A. fumigatus* povećao u poređenju sa netretiranom grupom G-1. Histopatološke lezije kod ćurića prethodno tretiranih deksametazonom bile su intenzivnije i opsežnije. Rezultati dobijeni mikološkim ispitivanjem i PCR metodom su pokazali da je veći broj uzoraka pozitivan na prisustvo DNK *A. fumigatus* u grupi G-2 koja je prethodno tretirana deksametazonom.