

# Journal of the Hellenic Veterinary Medical Society

Vol 73, No 4 (2022)



## Concurrent infection by *Clostridium perfringens* type A, *Clostridium septicum*, and *Clostridium sordelli* in mouflon (*Ovis aries musimon*) - A case report

*BZ Milovanović, MM Đorđević, BM Savić, NV Jezdimirović, NM Zdravković, Z Zurovac-Sapundžić, D Glišić, M Ninković, B Kureljušić*

doi: [10.12681/jhvms.28086](https://doi.org/10.12681/jhvms.28086)

Copyright © 2023, Bojan Zoran Milovanović, Milutin Milomir Đorđević, Božidar Milan Savić, Nemanja Velibor Jezdimirović, Nemanja Milan Zdravković, Zorana Aco Zurovac-Sapundžić, Dimitrije Jovan Glišić, Milan Živorad Ninković, Branislav Ilija Kureljušić



This work is licensed under a [Creative Commons Attribution-NonCommercial 4.0](https://creativecommons.org/licenses/by-nc/4.0/).

### To cite this article:

Milovanović, B., Đorđević, M., Savić, B., Jezdimirović, N., Zdravković, N., Zurovac-Sapundžić, Z., Glišić, D., Ninković, M., & Kureljušić, B. (2023). Concurrent infection by *Clostridium perfringens* type A, *Clostridium septicum*, and *Clostridium sordelli* in mouflon (*Ovis aries musimon*) - A case report. *Journal of the Hellenic Veterinary Medical Society*, 73(4), 5067–5072. <https://doi.org/10.12681/jhvms.28086>

## Concurrent infection by *Clostridium perfringens* type A, *Clostridium septicum*, and *Clostridium sordelli* in mouflon (*Ovis aries musimon*) - a case report

B. Milovanović<sup>1</sup> , M. Đorđević<sup>2</sup> , B. Savić<sup>1</sup> , N. Jezdimirović<sup>1</sup> , N. Zdravković<sup>1</sup> ,  
Z.Z. Sapundžić<sup>1</sup> , D. Glišić<sup>1</sup> , M. Ninković<sup>1</sup> , B. Kureljušić<sup>1</sup> 

<sup>1</sup>Institute of Veterinary Medicine of Serbia, Belgrade, Republic of Serbia

<sup>2</sup>Faculty of Veterinary Medicine, University of Belgrade, Republic of Serbia

**ABSTRACT:** A female mouflon, weighing 40 kilograms, was submitted to the diagnostic laboratory of the Institute of Veterinary Medicine of Serbia for determining the potential cause of death. Necropsy revealed massive hemorrhages in subcutaneous and intermuscular tissue and on papillary muscle. Petechiae and ecchymoses were found on the omentum, mesentery and adipose tissue of heart, kidney and costal pleura. Haemorrhagic-necrotic enteritis in duodenum and jejunum was characterized by catarrhal hemorrhagic inflammation with the presence of mucous and bloody content, whereas gas bubbles in the submucosa have also been confirmed. Bacterial cultures from sampled organs were identified as *Clostridium perfringens* type A, *Clostridium septicum*, and *Clostridium sordelli*. Based on the established pathological and histological changes and the results of the bacteriological, biochemical, and molecular examination, the state of septic shock and toxemia with disseminated massive bleeding was the immediate cause of mouflon death. The septic condition is a consequence of enterotoxemia caused by *Clostridium perfringens* type A, *Clostridium septicum*, and *Clostridium sordelli* infection.

**Key words:** mouflon; *Clostridium* spp; haemorrhagic-necrotic enteritis; enterotoxemia.

Corresponding Author:  
Bojan Milovanović, Janisa Janulisa 14, 11 000 Beograd, Serbia  
E-mail address: ojanmilovanovic10@gmail.com

Date of initial submission: 29-09-2021  
Date of acceptance: 27-04-2022

## CASE HISTORY

In this paper, the case of concurrent infection by *Clostridium perfringens* tip A, *Clostridium septicum*, and *Clostridium sordelli* in necropsied mouflon is described.

A female mouflon, weighing 40 kilograms, in good physical condition, was submitted to the diagnostic laboratory of the Institute of Veterinary Medicine of Serbia for determining cause of death. The female mouflon was originated from the hunting area of the city of Belgrade. According to the information obtained from the hunting organisation sudden death in mouflon was happened and recent more such cases occurred frequently. For these reasons, samples of corn from the hunting feeders where the animals were fed were also previously sampled and tested microbiologically, chemically, and mycotoxicologically according to ISO standards. Obtained results met the criteria following national regulations.

After the necropsy, samples for histopathological, bacteriological, and molecular examination were taken. The subcutaneous lymph nodes were slightly enlarged resembling serous lymphadenitis. Bilaterally, in the subcutaneous tissue and the intermuscular connective tissue of the femoral and cruris region, hemorrhagic suffusions and infiltrations were very extensive (Figure 1 (A)). In addition, subcutaneous and intermuscular hemorrhagic infiltrations were expressed in both the prescapular and subscapular regions, bilaterally.

Petechiae and ecchymoses were found on the omentum, mesentery, adipose tissue of the kidney, and costal pleura. The esophageal mucosa was white, and beneath the mucosa there were three parasitic cysts observed, 3-5 mm in diameter, resembling *Sarcocystis* spp. cysts. The lungs had a firm-elastic consistency. Numerous nodules, 1-3 mm in diameter, gray and yellow in the colour were observed in the lung tissue with signs of calcification, both subpleural and inside the lung parenchyma. Petechiae and ecchymoses were disseminated predominantly on the adipose tissue of the longitudinal and transverse sulci of the heart. Massive hemorrhages were noticed especially in the zone of the papillary muscle of the left ventricle (Figure 1 (B)). Massive hemorrhages with the formation of blood clot were found on the liver tissue nearby the gallbladder (Figure 1(C)). The spleen was slightly enlarged, with blunt edges. The forestomachs (rumen, reticulum, and omasum) were filled with content, composed of green mass- grass, leaves, and acorns. In the duodenum and jejunum, haemorrhagic-necrotic inflammation was noticed with the presence of mucous and bloody content (Figure 1(D)).

Skeletal muscles, esophagus, small intestine, liver, spleen, lungs, and heart samples for histopathological examination were fixed in 10% buffered formalin, processed by standard procedures, and embedded in paraffin blocks. Paraffin sections of tissue 5 µm thick were stained with hematoxylin-eosin (HE). Microscopic examination of lung tissue revealed different stages of lungworms in which calcified forms of lar-

**Figure 1.** Macroscopic findings in mouflon at necropsy (A): Hemorrhagic suffusions and infiltrations in subcutaneous and intermuscular tissue of the femoral and cruris region, (B): Massive hemorrhages (arrows) on papillary muscle in left ventricle, (C): Hemorrhages on the liver tissue nearby gallbladder, (D): Necrotic-haemorrhagic inflammation of small intestine, with the presence of mucous and bloody content (inset).

vae were present. Granulomas were surrounded by a large number of macrophages, lymphocytes, neutrophils, and eosinophils that were densely packed. Mild chronic catarrhal inflammation with the presence of mucous exudate as well as inflammatory cells was present in the lumen of the bronchi and bronchioles. In the liver tissue, microvesicular degeneration was observed. Additionally, disseminated necrotic foci were infiltrated by basophilic bacilliform bacteria. In the heart, hemorrhages were widespread in subepicardial and subendocardial tissue. In kidneys, tubules were dilated and with necrotic and vacuolated epithelium. Massive bleeding was present in the spleen, and a significant follicular lymphoid depletion was observed, as well (Figure 2 (A)). Massive bleeding was observed in skeletal muscle tissue as well as parasitic cysts, which were resembled as *Sarcocystosis* spp. cysts. Necrotic enteritis was characterised by sloughing of intestinal villi. The presence of gas bubbles was indicated in the submucosa (Figure 2 (B)). In the esophagus on pathohistological examination, an oval-shaped cystic parasite was observed.

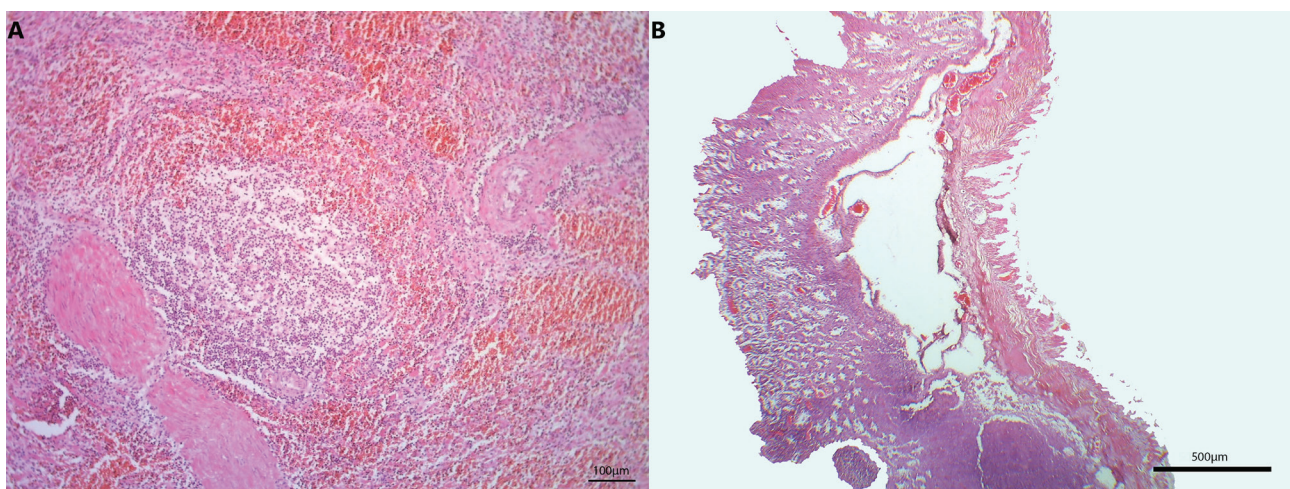
Keeping in mind that hemorrhagic diathesis was very prominent, it was decided to perform real-time RT-PCR for the presence of bovine viral diarrhea virus (BVDV) in parenchymatous organs as previously described (Hoffmann et al., 2006). The result was negative for the presence of the BVDV genome.

For bacteriological examination, the altered parts of the skeletal muscles with subcutaneous tissue, liver, spleen, and small bowel with the content were collected. The samples were inoculated on Kitt-Tarozzi broth and Columbia agar (HiMedia) supplemented

with 6% ovine blood under aerobic and anaerobic conditions for 48h at a temperature of 37°C. The isolated bacteria were preliminarily identified using routine techniques (Quinn et al 2011a, Hall 2016) followed by, biochemical characteristics with BBL Crystal Anaerobe ID (Becton Dickinson, USA) and molecular examination by PCR according to the protocols previously described (Sasaki et al., 2002; Van Asten et al., 2009). Bacteriology procedures revealed negative isolation for aerobic bacteria, while anaerobe isolates were further determined based on morphological, cultural, physiological characteristics and PCR assays. Bacterial cultures from skeletal muscles and small intestinal samples were identified as *Clostridium perfringens* type A, while liver and spleen samples revealed presence of *Clostridium perfringens* type A, *Clostridium septicum*, and *Clostridium sordelli*.

## DISCUSSION

Mouflons are one of the most prized game in Serbia, which was imported and inhabited a lot due to the growing trend of sport hunting. Due to similar climate and terrain, mouflons are imported from Slovenia and the Czech Republic. It is estimated that the number of mouflons in Serbia is 1221 individuals, according to the latest reports of the Republic Statistical Office of the Republic of Serbia in 2019 (Statistical Office of the Republic of Serbia, 2019). Some publications suggest that mouflons are affected by the same bacterial, viral and parasitic diseases as sheep (Takats, 1992). In Serbia, as in others countries, there aren't too many studies related to the diseases of mouflons, especially concerning pathology and bacterial diseases. In addition to parasitic diseases that are very



**Figure 2.** Pathohistological examination (A): Bleeding in the spleen with presence of follicular lymphoid depletion, (B): Necrotic enteritis with presence of gas bubbles in submucosa

common in wild animals as well as mouflon, mouflons are very sensitive to many parasites including genus *Muellerius* spp., *Trichostrongylus* spp., *Fasciola* spp. and *Dicrocoelium* spp. These parasites cause health problems, deaths, and consequently producing economic losses (Bliss, 2009). Infections caused by *Clostridium perfringens* have a significant role, as well. *Clostridium perfringens* type A, *C. sordellii*, *C. septicum*, *C. chauvoei*, and *C. novyi* type A have an impact on the etiology of gas gangrene in sheep (Silva et al, 2016). *Clostridium septicum* is the cause of gas edema and necrotic abomasitis (braxy). *Clostridium sordellii* is one of the microorganisms responsible for wound infection in sheep and other susceptible animals, development of malignant edema, and the etiological factor in the development of acute toxemia. *Clostridium septicum* is one of the most commonly isolated bacteria while *Clostridium perfringens* type A and *Clostridium sordellii* are less frequently isolated. Due to the possibility of post mortem invasions, isolation of *Clostridium sordellii* alone is not relevant for confirming the cause of death (Beveridge, 1983).

*Clostridium* species are evident inhabitants of intestinal tract of mouflon as well as other ruminants (Sipos et al., 2003). Endogenous infection is the most common cause of death, but infection can also occur due to ingestion of contaminated feed and water (Popova et al, 2007). *Clostridium septicum* is an ubiquitous microorganism that in conditions of immunodeficiency can lead to endogenous infection (Srivastava et al., 2017). Since no traces of skin discontinuity were found on the necropsied mouflon, we concluded that the infection was caused by ingestion of water or feed from soil outside the hunting feeders contaminated with corpses or plants in a rotting process that creates conditions conducive to the growth of these bacteria. However, results of microbiological, chemical, and mycotoxicological analyses of corn met the criteria following national regulations. On the other hand, we cannot exclude the possibility of contamination of the other feed such as acorn and leaves from the forest which was consumed by mouflons in the hunting area. In addition, in some parts of the hunting area, according to the report of local veterinarians and hunters, puddles of water were also noticed. In such places, water can be a suitable medium for clostridia survival and their proliferation, as well as for other bacteria. Intake of such water contaminated by spores can be a source of clostridial infection of mouflons. Additionally, fecal contamination has a major role in transmitting this bacteria. Bacteria from the genus

*Clostridium* survive longer in soil with a neutral and alkaline reaction, and precisely such soil is found during the winter or relatively colder seasons (Todorov et al., 1998). Necropsied mouflon was found in a food-rich region, with large amounts of grass and hay, leading to increased food intake, resulting in slowed peristalsis and creating anaerobic conditions in the intestines which favor the multiplication of clostridia and consequently the development of enterotoxemia.

Massive hemorrhages can be explained by the high potential of toxins produced by *Clostridia*. *Clostridium perfringens* type A produce a toxin with lecithinase activity that hydrolyzes the phospholipid bilayer of the cell membrane. The effect of alpha-toxin in the body is hemolytic, leukocidal, increases the permeability of capillaries, and leads to damage to the plasma membrane of muscle cells (Quinn et al., 2011b). The *C. septicum*  $\alpha$ -toxin is a lethal and necrotizing pore-forming cytolysin (Ballard et al., 1995). A range of effects that  $\alpha$ -toxin has on the target cell includes lytic and vacuolating properties (Wichroski et al., 2002). Synergistic effects of different toxin types can explain very prominent hemorrhagic diathesis observed in this case.

It is known in the literature that parasitic infections are very common finding in mouflons. In one study in Hungary (Andras, 2003) out of the 154 mouflons examined, 93.5% had various parasitic infections. Parasitic infections in small ruminants can be associated with respiratory disturbances (Mansfield et al., 1993) as well as secondary bacterial infections of the lungs (Kontrimavichus et al., 1976a). These infections are accompanied by a decrease in body weight and productive results, reduced number of offspring as well as abortions and neonatal death (Kontrimavichus et al., 1976b). In the present case, we could only hypothesize that parasitic infections have influenced the course of the clostridial disease, without the chance of its confirmation.

Based on the established pathological changes and the results of the bacteriological, biochemical, and molecular examination, the state of septic shock and toxemia with disseminated massive bleeding were the immediate cause of mouflon death. The septic condition is a consequence of enterotoxemia and malignant edema caused by *Clostridium perfringens* type A, *Clostridium septicum*, and *Clostridium sordellii* infection.

**ACKNOWLEDGEMENTS**

This research was supported by the Ministry of Education, Science and Technological Development, contract number 451-03-9/2021-14/ 200030.\

**CONFLICT OF INTEREST**

None declared by the authors.

**REFERENCES**

- András T (2003) Helminthic infestation of the mouflon (*Ovis ammon musimon*) in Hungary. *Magy Allatorvosok Lapja* 125:94-98.
- Ballard J, Crabtree J, Roe BA, Tweten RK (1995) The primary structure of *Clostridium septicum* alpha-toxin exhibits similarity with that of *Aeromonas hydrophila* aerolysin. *Infect. Immun.* 63:340-344.
- Beveridge WIB (1983) Bacterial Diseases of Sheep and Cattle. *Animal Health in Australia* 4:73-75.
- Bliss H (2009) The control of gastro-intestinal nematode parasites of hoofed wild life in North America. *Mid-American Ag. Research Vetrina, WI* 53593.
- Hall GS (2016) Hall Anaerobic Bacteriology, Chapter 4 In: Lynn Garcia ed, *Clinical Microbiology Procedures Handbook*, 3th ed, American Society Microbiology, Washington DC:pp 1-28.
- Hoffmann B, Depner K, Schirrmeyer H, Beer M (2006) A universal heterologous internal control system for duplex real-time RT-PCR assays used in a detection system for pestiviruses. *J. Virol. Methods* 136:200-209.
- Kontrimavichus VL, Deliamure SL, Boev SN (1976) *Metastrongyloidei domashnih i dikih jivotnih*, In: *Osnovy Nematodologii*, Rijikov K, Izdatelstvo Nauka, Moskva, Russia:pp 237.
- Mansfield LS, Gamble HR, Baker JS, Lichtenfels JR (1993) Lungworm infection in a sheep flock in Maryland. *J Am Vet Med Assoc* 202:601-606.
- Popova T, Tzvetkov Y, Dikova T (2007) ENTEROTOXAEMIA IN MOUFLONS (*OVIS MUSIMON*). *Bulg J Vet Med* 10.
- Quinn PJ, Markey BK, Leonard FC, Hartigan P, Fanning S, Fitzpatrick ES (2011). *Quinn Veterinary Microbiology and Microbial Disease*, 2nd ed, Wiley-Blackwell (Oct): pp 928, ISBN: 978-1-405-15823-7.
- Sasaki Y, Kojima A, Aoki H, Ogikubo Y, Takikawa N, Tamura Y (2020) Phylogenetic analysis and PCR detection of *Clostridium chauvoei*, *Clostridium haemolyticum*, *Clostridium novyi* types A and B, and *Clostridium septicum* based on the flagellin gene. *Vet. Microbiol* 257:257-267.
- Silva R, Uzal F, Oliveira C, Lobato F (2016) *Gas Gangrene (Malignant Edema)*. Wiley Blackwell 243-254.
- Sipos W, Fischer L, Schindler M., Schmoll F. 2003. Genotyping of *Clostridium perfringens* isolated from domestic and exotic ruminants and swine. *J. Vet. Med* 50(7):360-362.
- Srivastava I, Aldape MJ, Bryant AE, Stevens DL (2017) Spontaneous *C. septicum* gas gangrene: a literature review. *Anaerobe* 48:165-171.
- Statistical Office of Republic of Serbia (2019) <https://data.stat.gov.rs/Home/Result/13040601?languageCode=sr-Latn#> [accessed 30 July 2021]
- Takats A (1992) Hoof-disease of the mouflon (*Ovis ammon musimon*). *Magy Allatorvosok Lapja*, 47(9): 475-478.
- Todorov D, Dikova T, Masalski N (1998) Enterotoxemia in goats caused by *Clostridium perfringens* type A. *Vet. Med.* 4(2):95-96.
- Van Asten AJ, Van der Wiel CW, Nikolaou G, Houwers DJ, Gröne A (2009) A multiplex PCR for toxin typing of *Clostridium perfringens* isolates. *Vet. Microbiol* 136(3-4):411-412.

Wichroski MJ, Melton JA, Donahue CG, Tweten RK, Ward GE (2002) Clostridium septicum alpha-toxin is active against the parasitic protozoan Toxoplasma gondii and targets members of the SAG

family of glycosylphosphatidylinositol-anchored surface proteins. Infect. Immun.70:4353 - 4361.