

COMPARISON OF THREE METHODS OF MEASURING VERTEBRAL HEART SIZE IN GERMAN SHEPHERD DOGS

SPASOJEVIĆ KOSIĆ LJUBICA*, KRSTIĆ N**, and TRAILOVIĆ RD**

*Department of veterinary medicine, Faculty of agriculture, Novi Sad

**Faculty of veterinary medicine, Beograd

(Received 19. November 2006)

The method of measuring the heart size in thoracic radiography by comparing it to the length of thoracic vertebrae is marked as vertebral heart size (VHS). Besides the original VHS measurement suggested by Buchanan and Bücheler, there are modifications of these measurements in literature. With the aim to evaluate differences between different methods of VHS measurement, we compared radiographs of six clinically healthy dogs of the same breed and age (German shepherd dogs, 3 years of age), whose heart size was measured according to three different methods of VHS measurement. There were not significant differences between the values obtained by different methods of VHS measurement. In our study, we also compared findings of radiographs subjective assessment and VHS measurements. The second and third method of measurement were much more consistent to subjective assessment than the first method. Diagnosis of cardiac abnormalities in dogs should not be based solely on the measurement of vertebral heart size. However, VHS measurement is very suitable for clinical practice. According to the study reported here, the second method of VHS measurement described in this paper, was recommended.

Key words: dogs, thoracic radiography, vertebral heart size.

INTRODUCTION

Radiographic diagnosis in dog cardiovascular medicine is used to identify generalized cardiac enlargement, specific cardiac chamber or great vessel enlargement, pulmonary parenchyma and vascular abnormalities, as well as determination of effusions in the body cavities (pleural effusion and ascites) (Kittleson, 1998; Dark *et al.*, 1996).

Evaluation of the cardiac silhouette uses a variety of subjective methods as well as cardiothoracic ratios. These methods are not suitable for clinical practice. Their precision and accuracy are undermined by marked interbreed and individual variations in the thoracic conformation in dogs, as well as by variations in the appearance of the cardiac silhouette resulting from inconsistent patient's

positioning for radiography, phases of the respiratory or cardiac cycles and any other concurrent thoracic diseases (Kealy, 1979; Dennys and Herrtage, 1995; Krstić, 2002; Root and Bahr, 2002; Lamb, 2004). To overcome these limitations, the vertebral heart size method (VHS, vertebral heart size) that compares cardiac dimensions to the length of thoracic vertebrae was developed. Besides the original measurement method that was suggested by Buchanan and Bücheler (1995) there are modifications of these measurements which are based on reference points for short heart axis determination and introduction of the VHS unit - i.e. the length of one thoracic vertebra (Hansson *et al.*, 2005).

In the study reported here, we compared radiographs of clinically healthy dogs of the same breed and age, whose heart size was measured according to three different methods of VHS measurement. The aim of this study was to evaluate whether there are significant differences between methods of VHS measurement and to determine the most reliable method for further radiographic evaluation.

MATERIAL AND METHODS

Animals

Six German shepherd dogs (5 males and 1 female) of the same age (3 years) without clinical symptoms of cardiovascular or respiratory disease were included in this study. All dogs were evaluated by clinical examination including the history of each dog (ascertained by an interview with its owner), physical examination, complete blood count and serum chemistry, thoracic radiography, electrocardiography and echocardiography. All examinations were performed with manual restraint of the animals, without the use of sedation or anesthesia.

Positioning of the patient for thoracic radiography was in the right lateral recumbence (laterolateral thoracic radiographic view). Radiographic scanning was performed using Gierth HF 200 (Japan), with a condition of 70-80 kV, 25 mA, 0.10 - 0.20 s and FfO 80 cm. Cassettes format 30 x 40 cm with green screens and green films were used for recordings.

Radiographs of all dogs were analyzed by subjective assessment and then three methods of VHS measurement were performed.

Measurements

First measurement – Longitudinal and short axis of the heart were placed on lateral radiographic view. The long axis (LA) of the heart was measured from the ventral border of the left main stem bronchus to the most distant ventral contour of the cardiac apex (Figure 1). The measurement was made using a caliper, and then the measured length was repositioned over the thoracic vertebrae beginning with the cranial edge of the fourth thoracic vertebrae (T4). In the case that length did not cover a whole number of vertebrae estimation of proportion to the length of the last covered thoracic vertebra, LA was counted in decimal values of vertebrae. Maximal short axis (SA) of the heart was placed in the central third region of the heart, perpendicular to the long axis. The length of SA was assessed on the same

way as in case of LA, by a caliper. Finally, the sum of both values (long and short axis) was equivalent to the vertebral heart size.

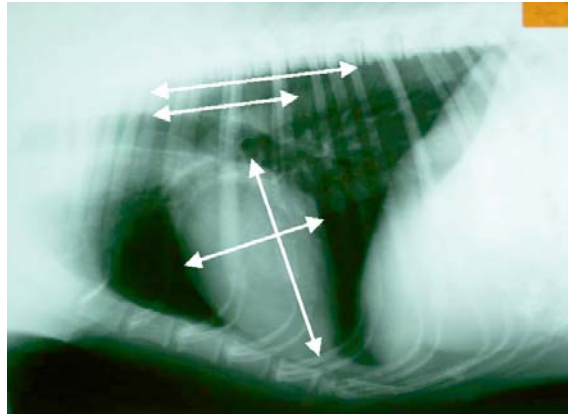


Figure 1. Long (LA) and short (SA) axis of the heart in lateral radiograph view, with repositioning of their length over thoracic vertebrae beginning with cranial edge of T4

Second measurement – The long and short axes of the heart were placed on the same way as previously described in the first measurement. The distance was measured by using calipers and then repositioned on a ruler, so that the long and short heart axis were measured in mm. The cardiac long and short axis were transformed from mm into whole and 0.01 of VHS units (v), by dividing both values with the length (in mm) of the body and caudal disc of T4. The two VHS measurements (for long and short axis) were then summed.

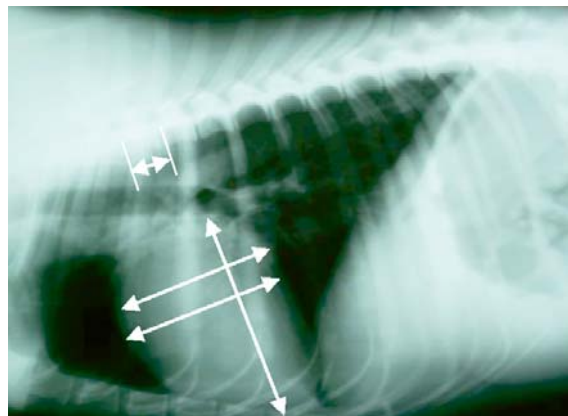


Figure 2. Laterolateral thoracic radiographic view with long and short axis of the heart and VHS unit (body and disc of T4) according to second and third method of VHS measurement

Third measurement: long heart axis was determined in the same way as described in the first and second measurement. The cardiac short axis was placed perpendicular to the long axis. The caudal reference point for heart width was halfway between the dorsal and ventral border of the vena cava caudalis. Both values were measured in mm, and then divided with the length of VHS unit (body and disc of T4), so that heart size would be measured in v (Figure 2).

Statistical analysis

Statistical analyses was performed with a computerized statistical software package Statistics 7.1.

RESULTS

Laterolateral thoracic radiographic view of the homogeneous group consisted of six clinically healthy German shepherd dogs (1 female and 5 males) all 3 years of age.

Radiographs were of good technical quality, so anatomic landmarks were used as references points for cardiac silhouette size determination.

Radiographs of these dogs were analyzed by one person, an experienced veterinary radiologist. Analyses of radiographs show that heart position varies from stenic (dogs 1 and 2) to astenic (dogs 4 and 5) and hyperstenic (dogs 3 and 6). Heart size was not over 3.5 intercostal spaces in any of the observed dogs. Normal heart shape was described for dog 1, while two dogs had mild accentuation of the left heart contour (left chamber ventricle in dog 2 and left atrium and ventricle in dog 4). There were accentuations of the right heart in dogs 4 and 5 (concentric hypertrophy) while dog 6 had a more convex right and left contour of the heart silhouette (myopathic configuration).

There were respiratory abnormalities in two dogs: chronic bronchitis (dog 3) and emphysema pulmonum (dog 6).

Hilar regions in all dogs were well developed except for dog number 3 where the hilus was emphasized.

Results of the VHS measurements, mean values, standard deviations and coefficients of variation are shown in Table 1.

There were not significant differences between values in three different methods of VHS measurement.

The first method of measurement in three dogs (dog 1, 2 and 5) showed the highest values and in the other three dogs (dogs 3, 4 and 6) the lowest values then the two other methods of measurement. The second method of measurement in three dogs (dogs 3, 4 and 6) showed the highest values then in the other two dogs, while the third method gave the lowest values for dogs 1, 2 and 5. All values were in the normal range for this breed (8.7 – 11.2v). Neither of the VHS values in the radiographed dogs was 11.1v, which is considered as the mean VHS value in German shepherd dogs with heart disease.

Considering the value of 10.2v, which is in German shepherd dogs a threshold value for cardiac diseases, only one dog in the first measurement had VHS value lower than 10.2v. According to the second measurement three dogs

had values higher than 10.2v (dogs 2, 3 and 6) while in the third measurement VHS values greater than 10.2v had two dogs (dog 3 and dog 6).

Table 1. VHS values (mean, standard deviation and coefficient of variation according to three methods of VHS measurement in German shepherd dogs

Dogs	I measurement (v)	II measurement (v)	III measurement (v)
Dog 1	10.46	10.14	10.07
Dog 2	10.68	10.48	10.20
Dog 3	10.54	10.63	10.55
Dog 4	9.84	9.92	9.87
Dog 5	10.25	10.20	9.96
Dog 6	10.63	10.88	10.73
\bar{X}	10.40	10.37	10.23
SD	0.44	0.32	0.34
CV%	4.26	3.08	3.36

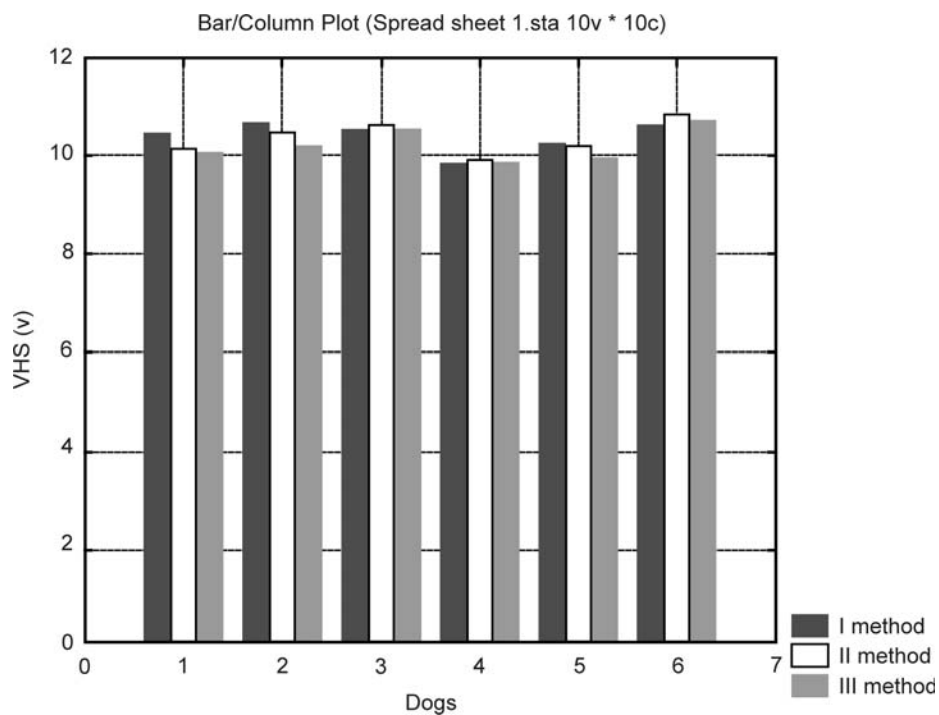


Figure 3. VHS values (v) in dogs according to three methods of VHS measurement

DISCUSSION

Thoracic radiography is one of the most available methods of heart and lung examination to the veterinarians. However, difficulties in the interpretation of dog radiographs still exist in assessing the changes in size and shape of the cardiac silhouette (Kealy, 1979; Suter, 1994; Dennys and Herrtage, 1995; Dark *et al.*, 1996; Kittleson, 1998; Krstić, 2002; Root and Bahr, 2002; Lamb, 2004). Buchanan and Bücheler have recently described a VHS method of cardiac silhouette measurement and determined normal range of VHS by analyzing radiographs of 100 clinically healthy dogs of different breeds. VHS method is suggested as a method which can increase the accuracy of radiographic diagnosis of the cardiac disease. This method is independent from the observer's experience (Hansson *et al.*, 2005). Its significance is important in the assessment of cardiomegaly in dogs, as well as qualifying its progression during a period of time (Buchanan and Bücheler, 1995).

The recognition of interbreed variations in cardiac dimensions has already led to the development of breed – specific ranges for echocardiography (Morrison *et al.*, 1992; Kayar *et al.*, 2006). Researchers have suggested that in radiographic measurements it might be better to use breed specific normal ranges (Lamb *et al.*, 2000; Lamb *et al.*, 2001).

According to the three studied methods of measurement differences in VHS values resulted from different reference points for long (LA) and short (SA) axis of the heart, as well as from the comparison of cardiac LA and SA, either with the number of vertebrae they covered with their length or with the length of one specific thoracic vertebrae.

Differences were not significant and for each dog were less than 0.5v.

The first method of measurement, as described by Buchanan and Bucheler, consists in marking the long and short axis of the heart. The long axis of the heart was marked from the ventral border of the left mainstem bronchus to the cardiac apex, while the short axis of the heart was marked at the point of maximal width in the central third region of the heart, perpendicular to the long axis. LA represents the size of the left atrium and left ventricle together, while SA represents the size of the right and left atrium. Both of these lengths were repositioned along the ventral border of thoracic vertebrae started from T4. It was counted how many vertebrae covered LA and SA with their length. The sum of these values was equivalent to VHS. The basic complaint for this method of VHS measurement was the estimation of proportions in the case when LA and SA were not covered by a whole number of vertebrae, as well as the fact that length of thoracic vertebrae of each individual varies within a certain range.

Two other methods of VHS measurement introduced the VHS unit (length of body and discus of T4) with the aim to express the heart size by comparing it with the length of one specific vertebra. For practical reasons the T4 vertebra was used as a reference unit, as this vertebra was the cranial reference point for VHS measurements. Introduction of the VHS unit simplifies the calculations very much.

The second and third methods of heart size measurement differed from each other in terms of the choice of the reference point for the cardiac short axis.

The third method of measurement introduced a determinate reference point for the short axis of the heart, as the caudal reference point for the short axis of the heart was halfway between the dorsal and ventral border of the caudal vena cava. For the first time this type of measurement (Hansson *et al.*, 2005) was performed on Cavalier King Charles spaniel dogs, a breed that has a predisposition for mixomatous valve degeneration, with left atria enlargement as a result of mitral regurgitation. Thus, the reference point was precise and the point for measurement was the same no matter the left atrium was enlarged or not. In our study, we established a second method which is characterized by the VHS unit (length of body and disc of T4) as well as by the reference points for LA and SA of the heart analogous to those described in the first method of measurement.

Moreover, the maximal length of the short axis was not the same in all dogs as the line perpendicular to LA was halfway between the dorsal and ventral border of the caudal vena cava. For that reason placing SA on the widest part of the heart is more susceptible to individual changes within the same breed, specially in breeds which do not have a predisposition for cardiac diseases. On the other hand such determination of the SA is still subjective in the assessment of the maximal width of the central third of the heart. However, the cardiac silhouette must always be examined for subtle changes in contour that may develop in dogs with concentric hypertrophy without consequent dilatation (Buchanan and Bücheler, 1995).

Although VHS measurement might be expected to help in the radiographic diagnosis of cardiac disease, there is limited published data to support this hypothesis (Lamb *et al.*, 2000; Lamb *et al.*, 2001; Nakayama *et al.*, 2001; Sleeper and Buchanan, 2001).

The accuracy of cardiac diagnosis was not improved when VHS measurement was used as a supplement to subjective assessment of radiographs (Lamb *et al.*, 2000).

Comparison of subjective assessment of radiographs and VHS measurements in our work showed differences in the first method of VHS measurement. Although VHS values were in the normal range (8.7v - 11.2v) only dog 4 had VHS less than 10.2v. This value was considered as the threshold value for cardiac diseases diagnostics in German shepherd dogs (Lamb *et al.*, 2001). Dog 4 was the only female in our study. Previous research (Lamb *et al.*, 2001) reported that females have lower VHS values than males. According to the first method of VHS measurement dog 1 also had VHS > 10.2v, while all other analyses (laboratory findings, electrocardiography and echocardiography) show that it was a healthy dog with normal electrical and mechanical heart action. Three dogs were suspect of heart abnormalities (dogs 2, 3 and 6) according to the second method of measurement. According to the third method of measurement dog 3 and dog 6 had heart abnormalities which were consistent with the subjective assessment of radiographs. Our study showed the possibility that by using VHS measurement (second and third methods) dog 5 was described as healthy, while subjective analyses, analyses of electrocardiography and echocardiography showed the existence of abnormalities on the right and left heart. These abnormalities consisted of concentric hypertrophy, according to the subjective

assessment of radiographs, left ventricular enlargement was evident. Augmentation of the left ventricle internal diameter in diastole and systole was observed by M-mode echocardiographic measurements.

Many of the dogs with cardiac diseases had VHS values within the normal reference ranges (Buchanan and Bücheler, 1995). Also, there were so many normal dogs with VHS values above the normal reference ranges (Lamb *et al.*, 2000). Studies performed on German shepherd dogs showed a trend for cardiac disease in dogs, but not linked to respiratory disease, to have a higher mean value on the VHS scale than normal dogs of the same breed. The diagnostic accuracy of the VHS measurement results was 75% in this breed (Lamb *et al.*, 2001).

The value of the method as a screening test for cardiac disease is significantly limited by breed, sex, disease diagnosis, variations in the conformation of individual dogs of the same breed, the phase of the respiratory or cardiac cycles, inconsistencies in positioning for radiography, mistakes in measuring of complexities of the calculation itself.

In conclusion, diagnosis of a cardiac disease in dogs should not be based solely on the measurement of vertebral heart size. Radiographic diagnosis is a part of the diagnostic procedure and should be considered together with clinical symptoms, physical examination and other special cardiovascular examinations. Objectiveness, simplicity of measurements and calculation, independence of clinical experience gives an advantage to this method compared with subjective analyses of radiographs. This is particularly the case for the second method of VHS measurement in which dimensions of the left and right heart were taken in consideration. Introduction of T4 body and disc length as a VHS unit, made the procedure of calculation easier.

Address for correspondence:
Assistant Mr Ljubica Spasojević Kosić
Faculty of agriculture Novi Sad
Department of veterinary medicine
Trg Dositeja Obradovića 8,
21000 Novi Sad
Serbia
e-mail: ljubicask@polj.ns.ac.yu

REFERENCES

1. Buchanan JW, Bücheler J, 1995, Vertebral scale system to measure canine heart size in radiographs, *JAVMA*, 206, 194-9.
2. Dark P, Bonagura JD, Kelly DF, 1996, Cardiac radiography, In: Dark P, Bonagura JD, Kelly DF, editors, *Color atlas of veterinary cardiology*, St Louis: Mosby, 32-7.
3. Denny R, Herrtage M, 1995, Thorax. In Robin L, editor, *Manual of small animal diagnostic imaging*, Gloucestershire: British small animal veterinary association, 51-6.
4. Hansson K, Haggstrom J, Kvarn C, Lord P, 2005, Interobserver variability of vertebral heart size measurement in dogs with normal and enlarged hearts, *Veterinary Radiology & Ultrasound*, 46, 122-30.
5. Kayar A, Gonul R, Or ME, Uzsal A, 2006, M-mode echocardiographic parameters and indices in the normal German shepherd dog, *Vet Radiol Ultrasound*, 47, 482-6.

6. Kittleson MD, 1998, Radiography of the cardiovascular system, In: Kittleson MD, Kienle RD, editors, Small animal cardiovascular medicine, St Louis: Mosby, 47-72.
7. Krstić N, Macanović Lazarević M, 2002, Rendgenski pregled respiratornog trakta, srca i velikih krvnih sudova toraksa, Praktikum iz rendgenologije za studente veterinarske medicine, Zemun: AS Delo, 76-82.
8. Kayar A, Gonul R, Or ME, Uzsar A, 2006, M-mode echocardiographic parameters and indices in the normal German shepherd dog, *Veterinary Radiology & Ultrasound*, 47, 482-6.
9. Lamb CR, 2004, Why is cardiac radiology so difficult?, 29th World Congress of The World Small Animal Veterinary Association.
10. Lamb CR, Tyler M, Boswood A, Skelly BJ, Cain M, 2000, Assessment of the value of the vertebral heart scale in the radiographic diagnosis of cardiac disease in dogs, *Veterinary Record*, 146, 687-90.
11. Lamb CR, Wikeley H, Boswood A, Pfeiffer DU, 2001, Use of breed specific ranges for the vertebral heart scale as an aid to the radiographic diagnosis in dogs, *Vet Rec*, 148, 707-11.
12. Morrison SA, Moise NS, Scarlett J, Mohammed H, Zeager AE, 1992, Effect of breed and bodyweight on echocardiographic values in four breeds of dogs of differing somatotype. *J Vet Intern Med*, 6, 220-4.
13. Nakayama H, Nakayama T, Hamlin RL, 2001, Correlation of cardiac enlargement as assessed by vertebral heart size and echocardiographic and electrocardiographic findings in dogs with evolving cardiomegaly due to rapid ventricular pacing, *J Vet Intern Med*, 15, 217-21.
14. Root CR, Bahr RJ, 2002, The heart and great vessels, In Thrall DE, editor, *Textbook of veterinary diagnostic radiology*, Philadelphia: WB Saunders, 402 - 20.
15. Sleeper MM, Buchanan JW, 2001, Vertebral scale system to measure heart size in growing puppies, *JAVMA*, 219, 57-9.
16. Suter PF, 1994, The radiographic diagnosis of canine and feline heart disease, In *Radiology in practice*, The compendium collection, Prenton, New Jersey: Veterinary learning system, 48-61.

POREĐENJE TRI METODE MERENJA VELIČINE SRCA U ODNOSU NA VERTEBRE KOD NEMAČKIH OVČARA

SPASOJEVIĆ-KOSIĆ LJUBICA, KRSTIĆ N I TRAILOVIĆ RD

SADRŽAJ

Metod koji poredi dimenziju srčane siluete rendgenskog snimka toraksa psa sa dužinom tela torakalnih pršljenova označen je kao VHS metod. Pored originalnog merenja VHS koga su predložili Buchanan i Bücheler, u literaturi se opisuju i modifikacije ove metode. Sa ciljem da se ispita razlika između različitih metoda merenja VHS, izvršeno je poređenje rendgenskih snimaka šest klinički zdravih pasa iste rase i starosti (nemački ovčari stari 3 godine), čija je veličina srca izmerena upotrebom tri različita metoda merenja. Nisu utvrđene statistički značajne razlike između vrednosti dobijenih ovim različitim VHS metodama. Dijagnoza promena na srcu kod pasa ne treba da se isključivo zasniva na merenju veličine srca u odnosu na vertebre ali je VHS merenje veoma pogodno za kliničku praksu. Prema našim ispitivanjima, preporučen je drugi metod VHS merenja koji je opisan u radu, kao najpouzdaniji metod za rendgenska ispitivanja.