

Research article

CANINE AND FELINE THELAZIOSIS CAUSED BY *Thelazia callipaeda* IN SERBIA

GAJIĆ Bojan^{1*}, BOGUNOVIĆ Danica¹, STEVANOVIĆ Jevrosima², KULIŠIĆ Zoran¹, SIMEUNOVIĆ Predrag², STANIMIROVIĆ Zoran²

¹Department of Parasitology, Faculty of Veterinary Medicine, University of Belgrade, Bul. oslobođenja 18, Belgrade, Serbia; ²Department of Biology, Faculty of Veterinary Medicine, University of Belgrade, Bul. oslobođenja 18, Belgrade, Serbia

(Received 26 April; Accepted 20 October 2014)

Thelazia callipaeda is a parasitic nematode causing ocular infections in different mammalian species and humans, clinically manifested as lacrimation, conjunctivitis, keratitis, corneal opacity or corneal ulcer. In this paper, we reported six cases of autochthonous canine and feline thelaziosis on different localities in Serbia. Total of 285 parasites (85 males and 200 females) were collected from the eyes of infected animals (n=6) suffering from uni- or bilateral conjunctivitis, with the number of parasites ranging from 7 to 150 per animal. All parasites were morphologically identified as *T. callipaeda*, while molecular analyses of cytochrome oxidase 1 (*cox1*) gene revealed the presence of h1 haplotype, as the unique previously reported in other studies in Europe. Since *T. callipaeda* is a newly detected parasite in Serbia with the infective potential for humans, there is a necessity for animal owners education and cooperation among professional services in order to control this zoonosis.

Key words: autochthonous infection, cats, dogs, h1 haplotype, Serbia, *Thelazia callipaeda*

INTRODUCTION

Thelazia callipaeda (Spirurida, Thelaziidae) parasitizes in the eyes and surrounding tissues of different carnivore species, rabbits and humans causing lacrimation, conjunctivitis, keratitis, corneal opacity or corneal ulcer [1, 2]. This parasitic nematode was originally detected in the Soviet Union and some Asian countries (China, Indonesia, Thailand, Korea, Myanmar, India and Japan) and it is also known as the Oriental eyeworm [3].

The first case of infection by *T. callipaeda* in dogs in Europe was reported in Italy in 1989 [4]. Further studies confirmed the presence of the parasite in dogs from endemic areas in Italy, as well as in cats and foxes [5]. Cases of imported thelaziosis in France and Germany were reported [6,7] followed by autochthonous infections in dogs and cats in the same countries [8,9]. In addition to the infections in domestic and/or wild carnivores in Switzerland, Spain, Belgium and Portugal [10-15] *T. callipaeda* infection

Corresponding author: e-mail: gajicb@vet.bg.ac.rs

was also reported in brown hares from Italy [2]. Human ocular infections caused by *T. callipaeda* detected in endemic areas of Italy, France and Spain implicated the epidemiological importance of this parasite and the need for control measures [16,17]. The intermediate host and vector for *T. callipaeda* in Europe is the fruit fly *Phortica variegata* (Drosophilidae, Steganinae), which is confirmed under both experimental and natural conditions [18,19].

Morphological identification of *T. callipaeda* is based on the parameters of Skrjabin et al. [20] and Otranto et al. [21] while the analysis of the *cox1* gene is used for molecular identification and haplotype determination of the parasite [22]. Seven haplotypes of *T. callipaeda* were established in dogs in Asia based on the differences in *cox1* sequence, while only one haplotype 1 (h1) was found in Europe irrespective of the host (dogs, foxes and cats) [22].

This paper describes autochthonous cases of canine and feline thelaziosis caused by *Thelazia callipaeda* on different locations in Serbia.

MATERIAL AND METHODS

Sample collection

Adult parasites were collected in 2012 and 2013 from the eyes of four dogs and two cats originating from six different sites in Serbia (Figure 1, Table 1). All animals were

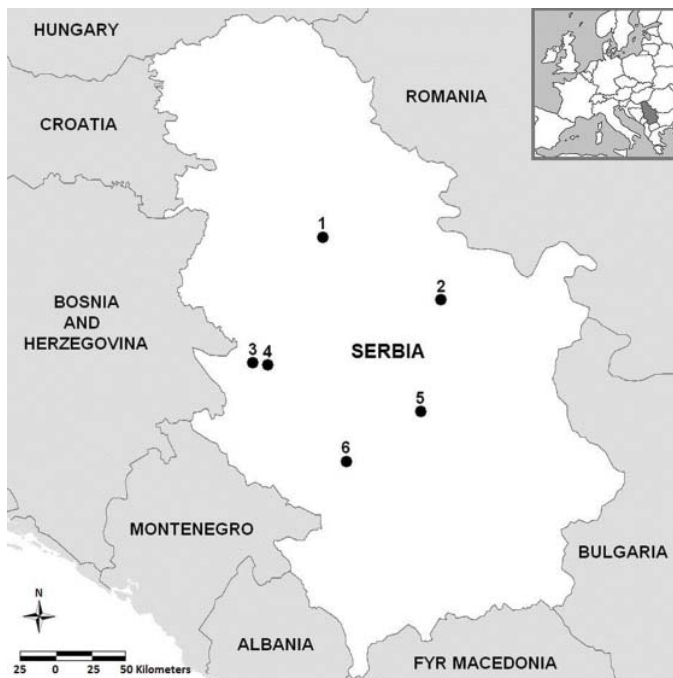

Figure 1. Location of cases of *T. callipaeda* infections reported in Serbia

brought to veterinary practitioners with symptoms of uni- or bilateral conjunctivitis, severe ocular discharge from one or both eyes, edema and conjunctival hyperemia (Figure 2). All examined animals were client-owned, they have never travelled abroad or to other areas of Serbia, and have never been treated with any antiparasitic drug. After the application of local anesthetic, (tetracaine hydrochloride; 0,5% Tetrakain; Hemomont, Montenegro) parasites were carefully removed from the eyes of infected animals with tweezers, washed in saline solution (0.9% NaCl), fixed in 70% ethanol and sent to the Laboratory of Parasitology and Laboratory for Animal Genetics at the Faculty of Veterinary Medicine, University of Belgrade, for morphological and molecular identification.

Table 1. Geographic characteristics of localities and *Thelazia callipaeda* sampling dates

No.	Locality	Coordinates	Altitude (m)	Habitat	Sampling date
1	Umka	44°40'N, 20°18'E	82	river, forest	Sept 2013
2	Kladurovo	44°26'N, 21°32'E	291	forest	Nov 2013
3	Užice	43°50'N, 19°51'E	490	river, forest	Oct 2013
4	Požega	43°50'N, 20°20'E	451	river, forest	Nov 2013
5	Kruševac	43°33'N, 21°27'E	216	river, forest	Sept 2013
6	Brvenik	43°21'N, 20°37'E	522	river, forest	Oct 2012

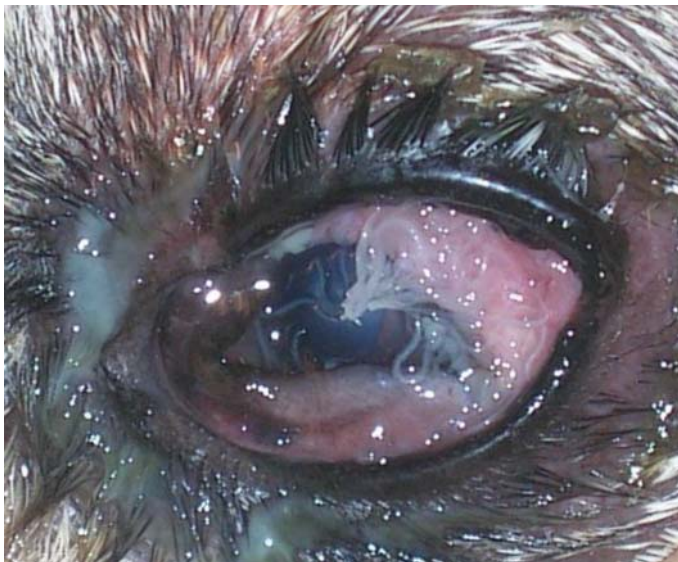

Figure 2. Eye of an infected dog with numerous adults of *T. callipaeda*

Morphological identification

All collected nematodes were morphologically identified according to the keys of Skrjabin et al. [20] and Otranto et al. [21], including body length and maximal width of adult parasites, number and position of postcloacal papillae and spicule length in males, as well as the position of the vulva in females.

DNA extraction

In order to confirm the morphological identification, two nematodes from each animal (total of 12) were used for molecular analyses. Total DNA was extracted from single parasites using KAPA Express Extract Kit (Kapa Biosystems) according to manufacturer's protocol.

PCR and sequencing

Partial *cox1* gene sequences (689 bp long) were amplified by PCR using primers NTF (5'-TGATTGGTGGTTTGGTAA-3') and NTR (5'-ATAAGTACGAGTATCAATATC-3') [23]. PCR was carried out in 25 µl volume containing 1x KAPA Taq buffer, 200 µM of each dNTP, 2.5 µM of MgCl₂, 0.5 µM of both primers, 0.5 U KAPA Taq DNA Polymerase (KAPA Taq PCR Kit, Kapa Biosystems) and 2.5 µl of template DNA. PCR was performed in Multigene Gradient Thermal Cycler (Labnet International, Inc). The PCR parameters for amplification were: initial DNA denaturation for 5 min at 95 °C, 30 cycles of denaturation for 30s at 95 °C, 30 s annealing at 45 °C, 1 min extension at 72 °C, followed by final extension for 5 min at 72 °C. Amplification efficiency was checked by electrophoresis in 2% agarose gel stained with ethidium-bromide and then visualized under UV light. A commercial O'RangeRuler™ 200 bp DNA Ladder (Fermentas) was used as a size marker. Amplified sequences were purified using the FastGene Gel/PCR Extraction Kit (Nippon Genetics) and sequenced in two directions in ABI 3730XL automatic DNA sequencer (Applied Biosystems) using commercial service (Macrogen Europe).

Sequence analysis

Obtained sequences were analyzed using BioEdit version 7.0.9.0. [24] and Clustal W software [25] and then compared to appropriate *cox1* sequences of *T. callipaeda* deposited in GenBank (Accession numbers AM042549-AM04556) [22].

RESULTS

A total of 285 worms (85 males and 200 females) were collected from six infected animals, with number of parasites ranging from 7 to 150 per animal (Table 2).

All parasites were morphologically identified as *T. callipaeda*. Male nematodes ranged from 10.46-13.91 mm in length, and maximal body width ranged from 385-438 µm.

All male worms had five pairs of postcloacal papillae on the ventral side of the body. The distance from the position of the cloaca to the end of the tail ranged from 74-85 μm . The shorter, right spicule length ranged from 140-159 μm , and the much longer, left spicule length ranged from 1.421-1.800 mm (Figure 3). Female worms ranged from 14.48-17.95 mm in length, and maximal body width ranged from 420-453 μm . The vulva was situated anterior to the oesophago-intestinal junction (Figure 4) and the distance between the vulva and buccal extremity ranged from 573-640 μm in length.

Table 2. *T. callipaeda* burden in infected animals of different breed, age, sex and purpose in Serbia

Locality	Species/Breed	Age (year)	Sex (m/f)*	Animal purpose	Parasite localization	Number of parasites	
						Total	m/f*
Umka	cat/domestic	3	f	pet	left eye	7	1/6
Kladurovo	dog/Samoyed	1.5	m	pet	left eye	91	32/59
Užice	dog/crossbreed	3	m	pet	both eyes	17	5/12
Požega	dog/Epagneul breton	8	m	hunting dog	both eyes	150	42/108
Kruševac	cat/domestic	2	f	pet	left eye	11	3/8
Brvenik	dog/Sharplanina**	3	m	pet	left eye	9	2/7

* m-male; f-female; ** Yugoslavian shepherd dog-Sharplanina

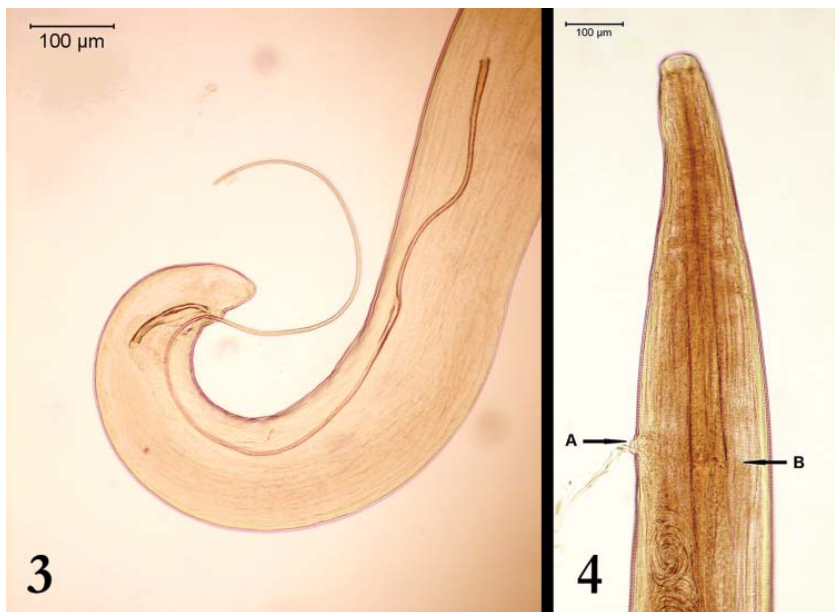

Figure 3. Posterior end of *T. callipaeda* male with unequal spicules; **Figure 4.** Anterior end of *T. callipaeda* female with vulva (A) and oesophago-intestinal junction (B)

All 12 PCR amplifications were successful, resulting in *cox1* amplicons of the same size on agarose gel (Figure 5). Besides, all analyzed *cox1* sequences from dogs and cats from this study were unique (GenBank Accession number KJ433982 and KJ433983, respectively) and identical to reference sequence of h1 haplotype (GenBank Accession number AM042549).

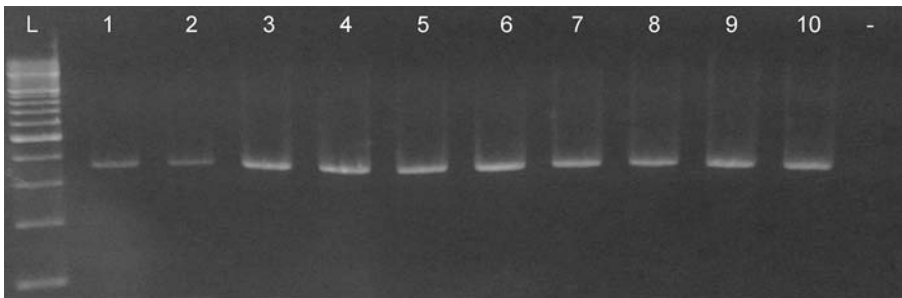


Figure 5. PCR amplicons of *T. callipaeda* *cox1* sequence* 200 bp ladder (L); 689 bp *cox1* amplicons of *T. callipaeda* from dogs (1-8) and cats (9-10); negative control (-)

* Two PCR amplicons from cats are not shown

DISCUSSION

In this study, cases of infection of dogs and cats caused by *T. callipaeda* were confirmed in Serbia. In all examined animals originating from six localities, only h1 haplotype of *T. callipaeda* was identified. Since all previous investigations from other European countries revealed the same haplotype, our finding of h1 haplotype confirms the hypothesis of low genetic variability of this parasite in Europe, already proposed by Otranto et al. [22].

Detection of the eyeworm in animals that had never travelled abroad indicates of autochthonous presence of thelaziosis in Serbia as it was previously recorded by other authors in endemic areas similar in geographic position, altitude and field configuration to those in our study [5,8-10,13-15,26]. In addition, distances between localities (from 16 to 146 km air distance) and the affected area (about 12390 km²) in our study indicate the endemic nature of thelaziosis in Serbia.

In the absence of official data concerning eyeworm infections in neighboring countries, the origin of this parasite in dogs and cats in Serbia can be explained by parasite establishment in wildlife from affected areas, as it was already observed in Italy, Switzerland and Spain [2,5,10,11].

All infected animals analyzed in this study were kept outdoor, increasing exposition to the vectors of *T. callipaeda*. However, *P. variegata*, the already proven intermediate host and vector for the eyeworm in Europe [18,19], had never been described in Serbia. Knowing this vector is the prerequisite for autochthonous thelaziosis in any area, as

well as the fact that Serbia is part of areas in Europe expected as suitable for *P. variegata* [27], further investigations concerning this issue are necessary.

The number of parasites per animal (7 to 150) in our study was greater than reported by other researchers (from 1 to 76) [10,13-15,26]. The highest parasite burden was observed in a 8-years-old hunting dog (harbouring totally 150 parasites). This finding can be explained by the fact that this dog had a higher possibility for contact with *P. variegata*, since these flies are more often present in forests and could be easily infected from *Thelazia*-positive wild animals, acting as possible reservoirs for *T. callipaeda* [2].

The fact that all parasites in this study originated from infected animals with clinical symptoms (bilateral or unilateral conjunctivitis) indicates that thelaziosis is underdiagnosed in Serbia, which is in agreement with recently reported studies including *Thelazia* affected dogs and cats from other European countries [15,26,28].

The present data indicate the importance of education and disease awareness among veterinarians and animal owners, since proper identification and treatment of infected animals contribute to the animal welfare eliminating discomfort and pain caused by *T. callipaeda*. Since *T. callipaeda* is a newly described parasite in Serbia, it will be necessary to consider thelaziosis as differential diagnosis during future clinical examinations of animals with ocular symptoms.

First cases of human thelaziosis have been recently described in some parts of Europe that had been previously reported to be endemic for canine thelaziosis [16,17]. Because of the expansion rather than limitation of spread of *T. callipaeda* in European countries and the zoonotic potential of this parasite, closer cooperation between veterinary and medical services is necessary in order to control this zoonosis.

Acknowledgements

This study was supported by the Ministry of Education, Science and Technological Development of the Republic of Serbia (Grant number III 46002).

We would also like to thank Prof. dr Jugoslav Vasić, DVM Zoran Radivojević, DVM Pavle Blagojević, DVM Zoran Đapović, DVM Darko Savić and DVM Dragoljub Bulić for the field support.

REFERENCES

1. Otranto D, Traversa D: *Thelazia* eyeworm: an original endo- and ecto-parasitic nematode. Trends Parasitol 2005, 21:1-4.
2. Otranto D, Dantas-Torres F, Mallia E, DiGeronimo PM, Brianti E, Testini G, Traversa D, Lia RP: *Thelazia callipaeda* (Spirurida, Thelaziidae) in wild animals: Report of new host species and ecological implications. Vet Parasitol 2009, 166:262-267.
3. Anderson RC: The superfamily Thelazioidea. In: *Nematode parasites of vertebrates: Their development and transmission*, 2nd edn. Guilford, United Kingdom: CABI Publishing; 2000, 404-407.

4. Rossi L, Bertaglia P: Presence of *Thelazia callipaeda* Railliet & Henry, 1910, in Piedmont, Italy. *Parassitologia* 1989, 31:167-172.
5. Otranto D, Ferroglio E, Lia RP, Traversa D, Rossi L: Current status and epidemiological observation of *Thelazia callipaeda* (Spirurida, Thelaziidae) in dogs, cats and foxes in Italy: a “coincidence“ or a parasitic disease of the Old Continent? *Vet Parasitol* 2003, 116:315-325.
6. Chermette R, Guillot J, Bussi ras J: Canine ocular thelaziosis in Europe. *Vet Rec* 2004, 21:248.
7. Hermosilla C, Herrmann B, Bauer C: First case of *Thelazia callipaeda* infection in a dog in Germany. *Vet Rec* 2004, 154:568-569.
8. Dorchies Ph, Chaudieu G, Sim on LA, Cazalot G, Cantacessi C, Otranto D: First report of autochthonous eyeworm infection by *Thelazia callipaeda* (Spirurida, Thelaziidae) in dogs and cat from France. *Vet Parasitol* 2007, 149:294-297.
9. Magnis J, Naucke TJ, Mathis A, Deplazes P, Schnyder M: Local transmission of the eye worm *Thelazia callipaeda* in southern Germany. *Parasitol Res* 2010, 106:715-717.
10. Malacrida F, Hegglin D, Bacciarini L, Otranto D, N geli F, N geli C, Bernasconi C, Scheu U, Balli A, Marengo M, Togni L, Deplazes P, Schnyder M: Emergence of canine ocular thelaziosis caused by *Thelazia callipaeda* in southern Switzerland. *Vet Parasitol* 2008, 157:321-327.
11. Calero-Bernal R, Otranto D, P rez-Mart n JE, Serrano FJ, Reina, D: First report of *Thelazia callipaeda* in wildlife from Spain. *J Wildlife Dis* 2013, 49:458-460.
12. Caron Y, Premont J, Losson B, Grauwels M: *Thelazia callipaeda* ocular infection in two dogs in Belgium. *J Small Anim Pract* 2013, 54:205-208.
13. Pimenta P, Cardoso L, Pereira MJ, Maltez L, Coutinho T, Alves MS, Otranto D: Canine ocular thelaziosis caused by *Thelazia callipaeda* in Portugal. *Vet Ophthalmol* 2013, 16:312-315.
14. Soares C, Sousa SR, Anast cio S, Goreti MM, Marqu s I, Mascarenhas S, Jo o Vieira M, Madeira de Carvalho L, Otranto D: Feline thelaziosis caused by *Thelazia callipaeda* in Portugal. *Vet Parasitol* 2013, 196:528-531.
15. Vieira L, Rodrigues TF, Costa  , Diz-Lopes D, Machado J, Coutinho T, Tuna J, Latrofa MS, Cardoso L, Otranto D: First report of canine ocular thelaziosis by *Thelazia callipaeda* in Portugal. *Parasite Vector* 2012, 5:124.
16. Otranto D, Dutto M: Human thelaziosis, Europe. *Emerg Infect Dis* 2008, 14:647-649.
17. Fuentes I, Montes I, Saugar JM, Latrofa S, G rate T, Otranto D: Thelaziosis in humans, a zoonotic infection, Spain, 2011. *Emerg Infect Dis* 2012, 18:2073-2075.
18. Otranto D, Lia RP, Cantacessi C, Testini G, Troccoli A, Shen JL, Wang ZX: Nematode biology and larval development of *Thelazia callipaeda* (Spirurida, Thelaziidae) in drosophilid intermediate host in Europe and China. *Parasitology* 2005, 131:847-855.
19. Otranto D, Cantacessi C, Testini G, Lia RP: *Phortica variegata* as an intermediate host of *Thelazia callipaeda* under natural conditions: Evidence for pathogen transmission by a male arthropod vector. *Int J Parasitol* 2006, 36:1167-1173.
20. Skrjabin KI, Sobolev AA, Ivashkin VM: Spirurata of animals and man and the disease caused by them. Part 4: Thelazioidea. In: *Essential of Nematodology. Vol. XVI*. Moscow, USSR: Academy of Sciences of the USSR; 1967, 8-58.
21. Otranto D, Lia RP, Traversa D, Giannetto S: *Thelazia callipaeda* (Spirurida, Thelaziidae) of carnivores and humans: morphological study by light and scanning electron microscopy. *Parassitologia* 2003, 45:125-133.

22. Otranto D, Testini G, De Luca F, Hu M, Shamsi S, Gasser RB: Analysis of genetic variability within *Thelazia callipaeda* (Nematoda: Thelazioidea) from Europe and Asia by sequencing and mutation scanning of the mitochondrial cytochrome c oxidase subunit 1 gene. *Mol Cell Probe* 2005, 19:306-313.
23. Casiraghi M, Anderson TJC, Bandi C, Bazzocchi C, Genchi C: A phylogenetic analysis of filarial nematodes: comparison with the phylogeny of *Wolbachia* endosymbionts. *Parasitology* 2001, 122:93-103.
24. Hall TA: BioEdit: a user-friendly biological sequence alignment editor and analysis program for Windows 95/98/NT. *Nucl Acid S* 1999, 41:95-98.
25. Thompson JD, Higgins DG, Gibson TJ: CLUSTAL W: improving the sensitivity of progressive multiple sequence alignment through weighting, position-specific gap penalties and weight matrix. *Nucleic Acid Res* 1994, 22:4673-4680.
26. Miro G, Montoya A, Hernández L, Dado D, Vázquez MV, Benito M, Villagrasa M, Brianti E, Otranto D: *Thelazia callipaeda*: infection in dogs: a new parasite for Spain. *Parasite Vector* 2011, 4:148.
27. Otranto D, Brianti E, Cantacessi C, Lia RP, Maca J: The zoophilic fruitfly *Phortica variegata*: morphology, ecology and biological niche. *Med Vet Entomol* 2006, 20:358-364.
28. Motta B, Nägeli F, Nägeli C, Solari-Basano F, Schiessl B, Deplazes P, Schnyder M: Epidemiology of the eye worm *Thelazia callipaeda* in cats from southern Switzerland. *Vet Parasitol* 2014, 203:287-293.

TELAZIOZA PASA I MAČAKA IZAZVANA SA *Thelazia callipaeda* U SRBIJI

GAJIĆ Bojan, BOGUNOVIĆ Danica, STEVANOVIĆ Jevrosima, KULIŠIĆ Zoran, SIMEUNOVIĆ Predrag, STANIMIROVIĆ Zoran

Thelazia callipaeda je parazitska nematoda koja izaziva infekciju oka različitih vrsta sisara i ljudi, a koja se klinički manifestuje pojačanim suzenjem, pojavom konjuktivitisa, keratitisa, zamućenja rožnjače ili pojave ulcera na rožnjači. U ovom radu opisani su nalazi autohtone telazioze pasa i mačaka na šest različitih lokaliteta u Srbiji. Iz očiju inficiranih životinja (n=6) sa simptomima uni- ili bilateralnog konjuktivitisa sakupljeno je 285 parazita (85 mužjaka i 200 ženki), pri čemu se broj parazita po životinji kretao od 7 do 150. Svi paraziti morfološki su identifikovani kao *T. callipaeda*, dok su molekularne analize citohrom oksidaza 1 (*cox1*) gena utvrdile postojanje h1 haplotipa, koji je do sada i jedini utvrđeni haplotip ovog parazita u Evropi. S obzirom da se radi o novootkrivenom parazitu na teritoriji Srbije koji može inficirati i ljude, neophodno je uložiti napore u edukaciju vlasnika životinja i saradnju stručnih službi u cilju kontrole ove zoonoze.