

Histological Effects of Enamel Matrix Derivative on Exposed Dental Pulp

Marijana Popović Bajić¹, Vesna Danilović², Branislav Prokić³, Bogomir Bolka Prokić³,
Milica Manojlović⁴, Slavoljub Živković¹

¹University of Belgrade, School of Dental Medicine, Department of Restorative Odontology and Endodontics, Belgrade, Serbia;

²University of Belgrade, School of Dental Medicine, Department of Histology, Belgrade, Serbia;

³University of Belgrade, Faculty of Veterinary Medicine, Department of Surgery, Belgrade, Serbia;

⁴Institute for Biological Research "Siniša Stanković", University of Belgrade, Belgrade, Serbia

SUMMARY

Introduction Direct pulp capping procedure is a therapeutic application of a drug on exposed tooth pulp in order to ensure the closure of the pulp chamber and to allow the healing process to take place.

Objective The aim of this study was to examine the histological effects of Emdogain® on exposed tooth pulp of a Vietnamese pig (*Sus scrofa verus*).

Methods The study comprised 20 teeth of a Vietnamese pig. After class V preparation on the buccal surfaces of incisors, canines and first premolars, pulp was exposed. In the experimental group, the perforations were capped with Emdogain® (Straumann, Basel, Switzerland), while in the control group pulp capping was performed with MTA® (Dentsply Tulsa Dental, Johnson City, TN, USA). All cavities were restored with glass-ionomer cement (GC Fuji VIII, GC Corporation, Tokyo, Japan). The observational period was 28 days, after which the animal was sacrificed and histological preparations were made. A light microscope was used to analyze dentin bridge formation, tissue reorganization and inflammation, and the presence of bacteria in the pulp.

Results The formation of dentin bridge was observed in the experimental and control groups. Inflammation of the pulp was mild to moderate in both groups. Angiogenesis and many odontoblast-like cells, responsible for dentin bridge formation, were observed. Necrosis was not observed in any case, nor were bacteria present in the pulp.

Conclusion Histological analysis indicated a favorable therapeutic effect of Emdogain® Gel in direct pulp capping of Vietnamese pigs. Pulp reaction was similar to that of MTA®.

Keywords: direct pulp capping; enamel protein; Vietnamese pig

INTRODUCTION

Direct pulp capping is a therapeutic procedure of great importance with the intention of preserving pulp vitality, especially in carious teeth of young patients and in cases with complicated canal systems [1, 2].

Although calcium hydroxide was introduced into the dental practice in 1929 by Hermann, it still represents the gold standard in direct pulp capping [3, 4]. However, because of an inadequate bond of calcium hydroxide with exposed pulp, degradation over time, the manifestation of internal resorption and porosity of newly formed dentin bridge, there is a necessity to find a more efficient material [5].

For the past twenty years great attention has been focused on the mineral trioxide aggregate (MTA®) which in direct pulp capping leads to complete dentin bridge formation, without signs of inflammation [6, 7]. Numerous studies have confirmed its biocompatibility, antimicrobial effect, good sealing and good physical and chemical properties [8, 9]. In wet conditions, MTA® releases calcium hydroxide as the main chemical component [10], does not cause local necrosis of the pulp, while

chronic inflammation of dental pulp is absent or rare [11]. However, MTA® has poorer antibacterial efficacy than calcium hydroxide. The instability of powder immediately after opening, high market price, and long setting time (between two and four hours) are well known disadvantages of this material [12]. There is a large randomized clinical trial, conducted for up to two years within a practice based research network, provided confirmatory evidence for a superior performance of MTA® compared to calcium hydroxide in direct pulp capping [13].

It is also known that enamel matrix derivative (EMD) has a biological role in dentin, acellular cementum and alveolar bone formation during embryonic tooth development [14]. EMD is composed primarily of amelogenin and amelin, and these proteins play an important role in dentinogenesis, increasing the level of mineralization markers in odontoblasts [15]. It has been shown that during the embryonic formation of the tooth crowns in cats and rodents, amelogenins reposition from the enamel organ to the site of future predentin and differentiating odontoblasts [16]. Clinical and experimental studies dealing with the effects of EMD on dental pulp in the therapeutic process

Correspondence to:

Marijana POPOVIĆ BAJIĆ
Department of Restorative
Odontology and Endodontics
School of Dental Medicine
University of Belgrade
Rankeova 4, 11000 Belgrade
Serbia

dr.marijanapopovic@gmail.com

of direct capping revealed beneficial effects in the formation of reparative dentin [17-22], but with some concerns about the results. Based on these facts, Emdogain® (Straumann, Basel, Switzerland) was synthesized.

Despite the fact that this new material has already been widely used in reconstructive surgery for regeneration of periodontal tissues, its effect on human pulp tissue is not yet fully understood considering that there are few published articles on this subject.

OBJECTIVE

The aim of this study was to examine the effects of EMD (Emdogain®) on exposed pulp of a Vietnamese pig (*Sus scrofa verus*).

METHODS

The experimental research was conducted at the Faculty of Veterinary Medicine, University of Belgrade. The experiment included 20 teeth of a Vietnamese pig (*Sus scrofa verus*), aged 24 months, weighing 25 kg. The experimental process was in accordance with good laboratory practice compliance (86/609/EEC), which involves the implementation of main principles of asepsis and antisepsis, the realization of the experiment in the minimum required time without the physical and mental suffering of animals (International Organization for Standardization, 1997).

The experimental material used in the research was EMD, and the control material was MTA® (Table 1).

Experimental procedure

Premedication was done with atropine 0.03–0.04 mg/kg i.m., and after 15 minutes the animal was introduced into general anesthesia using xylazine 1.5–2 mg/kg i.m. and ketamine 20–25 mg/kg i.m. After anesthesia and rubber dam insulation, the teeth were cleaned with 70% ethanol. On the buccal surfaces of incisors, canines and first premolars, class V cavities were prepared using a round carbide bur. This was done under continuous cooling with saline. The pulp chamber was exposed using a small round bur, and bleeding was controlled with sterile cotton pellets.

Then, the material was applied on the perforation according to the manufacturer's instructions. EMD was applied to the teeth in the right quadrant of the upper and lower jaw (a total of six incisors, two canines and two premolars), while the same number of teeth in the left quadrant of the upper and lower jaw was covered with MTA®. All cavities were restored with glass-ionomer cement (GC Fuji VIII, GC Corporation, Tokyo, Japan). The observational period was 28 days.

The animal was given an analgesic dose of butorphanol (0.1–0.2 mg/kg) during the termination of the anesthesia. The pig was kept and fed at a farm. After four weeks, the animal was sacrificed by inducing general anesthesia and administering sodium pentobarbital i.v. at a dose of 100 mg/kg. The jaws were cut into block sections and the tissue was fixed and prepared for microscopic analysis.

Histological procedure

The tissue for histological analysis was taken in blocks containing experimental tooth with surrounding bone tissue. Samples were collected 28 days after exposure and direct pulp capping, following ISO guidelines (Technical Report 7405). The material for histological analysis was fixed in 10% formalin, decalcified in 10% formic acid (pH=5) and embedded in paraffin. Serial sections in mesio-distal direction with the thickness of 4 µm were made and placed on glass slides. The slides were stained with hematoxylin and eosin, Goldner trichrome and Gram methods (for microscopic identification of bacteria). The material was analyzed using a light microscope (Carl Zeiss Inc., Oberkochen, Germany) with magnification 40×, 100× and 200×.

Histological criteria used for the evaluation of pulp reactions were based on the methodology of Shayegan et al. [23]. Dentin bridge formation (A), morphological reorganization of pulp cells (B), inflammatory reaction of pulp (C) and the presence of bacteria (D) were analyzed according to the following scale:

A. Dentin bridge formation (thickness, localization, structure, continuity with the surrounding dentin): 0 – no presence of dentin bridge; 1 – presence of an incomplete dentin bridge in the area of exposed pulp; 2 – presence of lateral dentin bridge; 3 – presence of dentin bridge with complete closure of dental pulp chamber;

Table 1. Comparison of materials used in the study

Pulp capping material	Material composition	Mechanism of action	Indications	Common features
Emdogain® (Straumann, Basel, Switzerland)	Enamel Matrix Proteins(Amelogenin) <i>Biological role in the formation of dentine, acellular cementum and alveolar bone during tooth development</i>	Biomimetic biology based product, which promotes the regrowth of hard and soft tissues	1-, 2-, and 3-wall intrabony defects; Class II mandibular furcation defects; Recession defects	Activate growth factors (TGFβ1 and a morphogenetic bone protein) which are involved in cell signaling and stimulating the formation of tissue matrix and its mineralization
ProRoot MTA® (Dentsply Tulsa Dental, Johnson City, TN, USA)	50–75% CaO 15–25% SiO ₂ , BiO ₂ <i>Releases Ca(OH)₂ in water as its main chemical component</i>	Bioactive material; Induction of reparative dentinogenesis	Pulp capping; Furcal repair; Root resorption; Repair of root perforation; Apexification; Root-end filling	

Table 2. Histological analysis of dental pulp after direct capping using different materials

Pulp-capping material	Number of teeth	Score															
		Dentin bridge				Tissue reorganization				Pulp inflammation				Bacterial presence			
		0	1	2	3	0	1	2	3	0	1	2	3	0	1	2	3
Emdogain®	10	0	5	3	2	3	7	0	0	1	8	1	0	6	4	0	0
MTA®	10	0	6	0	4	2	8	0	0	0	7	3	0	7	3	0	0

B. Morphological reorganization of the pulp: 0 – normal pulp tissue; 1 – disorganization of the odontoblast-like cells, odontoblasts' hyperactivity and proliferation of blood vessels beneath the exposed pulp; 2 – complete disorganization of the pulp tissue; 3 – pulp necrosis;

C. Inflammatory reaction of the pulp (chronic or acute, intensity and localization of the inflammation). Inflammatory reaction of the pulp was monitored with regard to the ISO guidelines as well as the published criteria by Mjör [24]: 0 – no inflammation or few inflammatory cells in the area of the exposed pulp; 1 – mild inflammation and the presence of inflammatory cells only at the site of the exposed pulp; 2 – moderate inflammation, more than one third of the pulp tissue infiltrated with inflammatory cells; 3 – severe inflammation, dental pulp diffusely infiltrated with mononuclear cells, with complete disorganization of the pulp tissue;

D. Presence of bacterial cells: 0 – no presence of bacteria either in the pulp tissue or dentinal tubules; 1 – bacteria present in the dentinal tubules, but not in the pulp; 2 – bacteria present along lateral dentin surfaces; 3 – bacteria present in the dental pulp and along lateral dentin surfaces.

RESULTS

Results of the histological analysis showed that dentin bridge was formed in all samples of both experimental and control groups (Table 2). The newly formed dentin had the characteristics of reparative dentin without any or with a small number of irregularly positioned dentinal tubules that were in continuity with the surrounding dentin. Dentin bridge that completely covered pulp space in the area of perforation was noted in two cases with EMD (Figure 1), and in four cases with MTA® (Figure 2). Odontoblast-like cells, related with the newly formed dentin, were observed below complete dentine bridges. The original odontoblasts were positioned peripherally. They were identified through their regular palisade arrangement, eosinophilic cytoplasm and basally positioned nucleus.

An incomplete dentin bridge in the form of dentinal islets was observed in five teeth in the EMD group (Figure 3) and in six teeth in the MTA® group. Lateral dentin formation was recorded in three cases in the EMD group, while this form of dentin was not registered in the samples of the MTA® control group (Figure 4).

Fully preserved pulp tissue was observed in three cases in the EMD group and in two cases in the MTA® group. Disorganization of the pulp tissue by emergence of cells similar to odontoblasts and their hyperactivity was observed in the majority of samples (seven teeth in the experi-




Figure 1. Almost complete closure of the pulp chamber by the newly formed dentin bridge (A). After covering with EMD, signs of angiogenesis in the form of newly formed blood vessels just below the dentin bridge were observed (B). (Goldner trichrome, magnification 40×)




Figure 2. Complete healing and closure of pulp chamber by the dentin bridge after capping with MTA® (A). In the area of perforation, the material particles were observed (B). The pulp morphology was preserved with a presence of a mild inflammatory reaction (C). (Goldner Trichrome, magnification 40×)

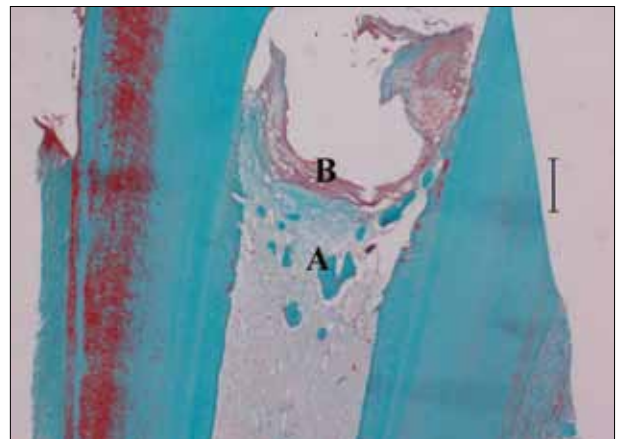


Figure 3. The newly formed dentin in the form of dentin islets (A) beneath the EMD covering the pulp exposure. The material covers the entire surface of the exposure (B) (Hematoxylin eosin, magnification 40×)



Figure 4. Newly formed dentin bridge that extends along the lateral walls of dentin (A) after pulp capping with EMD. Note clearly visible line of demarcation between the tubular and new atubular dentin (B). In the area of perforation, a small islet can be seen surrounded by preserved dentin pulp tissue (C). In the central part of the pulp, signs of venous stasis are observed (D). (Hematoxylin eosin, magnification 40 \times)

mental group and eight in the control group). In the central part of the pulp the presence of venous stasis, hemorrhage, and inflammation was observed. In most cases signs of angiogenesis with proliferation of existing and creation of new blood vessels indicating the healing process and complete revascularization was observed (Figure 5). Complete disorganization of the pulp or tissue necrosis was not observed in any sample of the experimental and control groups.



Figure 5. Complete dental pulp, perforation area and the placement of EMD on the exposure. Complete healing by dentin bridge formation (A) and obvious neoangiogenesis (B) and venous stasis (C) can be seen. (Goldner Trichrome, magnification 40 \times)

The results of histological analysis after four weeks revealed that pulp capping with the experimental material in most cases caused mild to moderate chronic inflammation. Inflammation was not observed in one sample only. Mild inflammation was present in eight samples of the experimental group and in seven samples of the MTA[®] group. Moderate inflammation with cellular infiltration of the coronal and radicular pulp was present in one sample of the EMD group and three in the group of MTA[®]. Severe inflammation with a variety of inflammatory cells and the appearance of abscess was not observed in any sample.

Gram staining confirmed the absence of gram-positive bacteria in all samples. A minimal number of bacteria in dentinal tubules was observed in four teeth of the experimental group and three teeth of the control group.

DISCUSSION

Previous studies with new materials were conducted on dog teeth [12, 25], primary and permanent teeth of pigs [18, 23] and monkeys [26]. An important advantage in working with experimental animals is that the experiment can be carried out on a large number of teeth and the effects of various materials can be assessed at the same time.

In the current study similar results were obtained in both groups. The process of reparative dentinogenesis and complete or partial closure of pulp perforations by a dentin bridge was considered a good therapeutic result. All teeth capped by EMD showed the presence of some form of dentin bridge. Similar results were confirmed by the study of Nakamura et al. [18]. In their study favorable therapeutic effects of EMD were explained by the ability of amelogenin and amelin to induce reparative dentinogenesis and stimulate pulp cells and their secretory activity. In the study of Olsson et al. [27] in humans, where EMD and calcium hydroxide were applied after pulpotomy, a lateral dentin bridge was observed in all cases where EMD was used for pulp capping. Those results were explained by possible existence of differences in the structure and morphology of dentin in humans and animals.

Human studies on premolars where pulp capping was done with calcium hydroxide and EMD have shown that both materials have the ability to induce tertiary dentin formation, wherein EMD still has lower potential for pulpal wound closure [28]. The study made by Kiatwateeratana et al. [29] was conducted on 15 pairs of contralateral premolars in humans where the effects of EMD and calcium

hydroxide were compared. Teeth treated with EMD in the first two weeks showed less sensitivity. There was no statistically significant difference in the radiographic parameters (formation and thickness of the dentin bridge). Histological results after 6 months showed favorable effects of calcium hydroxide in terms of less inflammation and greater thickness of dentin bridge [29]. In the current study when MTA[®] was applied directly to the pulp, the presence of dentin bridge was observed in all cases, which is consistent with a similar experimental study on pigs done by Shayegan et al. [23]. Just below the newly formed dentin bridge odontoblasts with minor or major structural changes that ranged from mild changes to complete disorganization were observed in most teeth of both groups. It is most likely these are not true odontoblasts, but odontoblast-like cells (for the definitive identification additional immunohistochemical analysis is required). These cells, as well as true odontoblasts have an elongated shape, palisade orientation and basally positioned nucleus [23]. They have the ability to secrete extracellular matrix and after its mineralization a reparative dentin in the form of complete or incomplete dentin bridge is created. Incomplete dentin bridge in the form of islets is an attempt to establish contact with the side walls of the dentin to close and preserve the exposed pulp.

In most of the samples of the MTA[®] group in the current study a reorganization of the tissue below the perforation was observed. This was detected as hyperactivity of odontoblast-like cells and altered cell morphology compared to odontoblasts. Similar results were reported in the study of Tziafas et al. [12] performed on dogs. There was a correlation between the number of odontoblast-like cells, the bridge thickness and the preservation of deeper parts of the pulp. As the number of these cells increased, so did the thickness of the dentin bridge, while the radicular pulp retained its physiological morphology [24].

Necrosis was not observed in any sample in the MTA[®] group in the present study. In the experimental study on dogs by Tabarsi et al. [25] after direct pulp capping, necrosis was present in 22.7% of samples. Different findings can be explained by the fact that in that study MTA[®] was applied after pulpotomy, while in our study MTA[®] was applied directly on a small perforation of the pulp.

In the present study the application of EMD in most teeth caused mild inflammation suggesting the biocompatibility of materials. Acute inflammation and necrosis of the pulp was not observed in any of examined samples. This can be explained by good cavity sealing using glass-ionomer cement in aseptic working conditions, as well as good immune status of experimental animals. However,

in the study done by Olsson et al. [27] on humans where EMD and calcium hydroxide were applied after pulpotomy, the presence of abscess was noted in one sample of each group.

The results of our experimental study demonstrated the presence of inflammatory cells in the coronal and radicular pulp. In the control group, where the pulp was capped with MTA[®], only a few samples showed the presence of lymphocytes, plasma cells and macrophages, which is consistent with the findings of other authors [23, 25]. The therapeutic effect of EMD and MTA[®] was very similar in the current study, suggesting that EMD has a favorable effect on the reparative activities of Vietnamese pigs' pulp primarily due to its physical and chemical properties.

After the application of these materials in the present study, angiogenesis in the pulp was observed, indicating regenerative processes in the pulp and successful tissue remodeling. Similar effects of EMD were obtained by Nakamura et al. [18], where the presence of newly formed blood vessels just below the zone of odontoblast-like cells was observed. However, the presence of blood vessels and venous stasis was detected in the central parts of the pulp, indicating complete remodeling of the pulp tissue.

Murray et al. [30] suggested that for the initiation of dentinogenesis, pulp and odontoblasts preservation is of primary importance, as well as the absence of infection and necrosis, but not the type of material used for pulp capping. Similar results in our study may be partially explained by the fact that the procedure was performed under aseptic conditions with minimal pulp perforation and good cavity sealing.

CONCLUSION

Pulp capping of artificially made perforations in teeth of a Vietnamese pig (experimental and control groups) was successful. In most teeth dentin bridge formation and preservation of the functional and morphological integrity of the pulp in the process of reparative dentinogenesis was observed. Histological analysis confirmed favorable therapeutic effect of EMD in direct pulp capping of Vietnamese pig teeth which was similar to MTA[®].

ACKNOWLEDGMENT

The work was supported by the project ON172026, of the Ministry of Education, Science and Technological Development of the Republic of Serbia.

REFERENCES

- Witherspoon DE, Small JC, Harris GZ. Mineral trioxide aggregate pulp potomies: a case series outcomes assessment. *J Am Dent Assoc.* 2006; 137:610-8. [DOI: 10.14219/jada.archive.2006.0256] [PMID: 16739540]
- McDonald R, Avery D, Dean J. Treatment of deep caries, vital pulp exposure and pulpless teeth. In: *Dentistry for the Child and Adolescent.* 8th ed. St. Louis: Mosby Co; 2004. p.389-412.
- Sangwan P, Sangwan A, Duhan J, Rohilla A. Tertiary dentinogenesis with calcium hydroxide: a review of proposed mechanisms. *Int Endod J.* 2013; 46:3-19. [DOI: 10.1111/j.1365-2591.2012.02101.x] [PMID: 22889347]
- Goldberg M, Farges JC, Lacerda-Pinheiro S, Six N, Jegat N, Decup F, et al. Inflammatory and immunological aspects of dental pulp repair. *Pharmacol Res.* 2008; 58:137-47. [DOI: 10.1016/j.phrs.2008.05.013] [PMID: 18602009]
- Schuurs AH, Gruythuysen RJ, Wesslink PR. Pulp capping with adhesive resin-based composite vs. calcium hydroxide: a review. *Endod Dent Traumatol.* 2000; 16:240-50. [DOI: 10.1034/j.1600-9657.2000.016006240.x] [PMID: 11202889]
- Faraco IM Jr, Holland R. Histomorphological response of dogs' dental pulp capped with white mineral trioxide aggregate. *Braz Dent J.* 2004; 15:104-8. [DOI: 10.1590/S0103-64402004000200004] [PMID: 15776191]
- Simon S, Cooper P, Smith A, Picard B, Ifi CN, Berald A. Evaluation of a new laboratory model for pulp healing: preliminary study. *Int Endod J.* 2008; 41:781-90. [DOI: 10.1111/j.1365-2591.2008.01433.x] [PMID: 18798922]
- Parirokh M, Torabinejad M. Mineral trioxide aggregate: a comprehensive literature review – Part I: Chemical, physical, and antibacterial properties. *J Endod.* 2010; 36:16-27. [DOI: 10.1016/j.joen.2009.09.006] [PMID: 20003930]
- Torabinejad M, Parirokh M. Mineral trioxide aggregate: a comprehensive literature review – Part II: Leakage and biocompatibility investigations. *J Endod.* 2010; 36:190-202. [DOI: 10.1016/j.joen.2009.09.010] [PMID: 20113774]
- Fridland M, Rosado R. Mineral trioxide aggregate (MTA) solubility and porosity with different water-to-powder ratios. *J Endod.* 2003; 29:814-7. [DOI: 10.1097/00004770-200312000-00007] [PMID: 14686812]
- Nair PN, Duncan HF, Pitt Ford TR, Luder HU. Histological, ultrastructural and quantitative investigations on the response of healthy human pulps to experimental capping with mineral trioxide aggregate: a randomized controlled trial. *Int Endod J.* 2008; 41:128-50. [DOI: 10.1111/j.1365-2591.2009.01558.x] [PMID: 17956562]
- Tziafas D, Pantelidou O, Alvanou A, Belibasakis G, Papadimitriou S. The dentinogenic effect of mineral trioxide aggregate (MTA) in short-term capping experiments. *Int Endod J.* 2002; 35:245-54. [DOI: 10.1046/j.1365-2591.2002.00471.x] [PMID: 11985676]
- Hilton TJ, Ferracane JL, Mancl L. Comparison of CaOH with MTA for direct pulp capping: a PBRN randomized clinical trial. *J Dent Res.* 2013; 92(7 Suppl):16S-22S. [DOI: 10.1177/0022034513484336] [PMID: 23690353]
- Hammarström L. Enamel matrix, cementum development and regeneration. *J Clin Periodontol.* 1997; 24:658-68. [DOI: 10.1111/j.1600-051X.1997.tb00247.x] [PMID: 9310870]
- Weishaupt P, Bernimoulin JP, Trackman P, Hägewald S. Stimulation of osteoblasts with Emdogain increases the expression of specific mineralization markers. *Oral Surg Oral Med Oral Pathol Oral Radiol Endod.* 2008; 106:304-8. [DOI: 10.1016/j.tripleo.2008.02.033] [PMID: 18547835]
- Spahr A, Lyngstadaas SP, Slaby I, Haller B, Boeckh C, Tsoufidou F, et al. Expression of amelin and trauma-induced dentin formation. *Clinical Oral Investigations.* 2002; 6:51-7. [DOI: 10.1007/s00784-001-0139-y] [PMID: 11996163]
- Ishizaki NT, Matsumoto K, Kimura Y, Wang X, Yamashita A. Histopathological study of dental pulp tissue capped with enamel matrix derivative. *J Endod.* 2003; 29:176-9. [DOI: 10.1097/00004770-200303000-00003] [PMID: 12669875]
- Nakamura Y, Hammarström L, Matsumoto K, Lyngstadaas SP. The induction of reparative dentine by enamel proteins. *Int Endod J.* 2002; 35:407-17. [DOI: 10.1046/j.1365-2591.2002.00556.x] [PMID: 12059910]
- Veis A, Tompkins K, Alvares K, Wei K, Wang L, Wang XS, et al. Specific amelogenin gene splice products have signaling effects on cells in culture and in implants in vivo. *J Biol Chem.* 2000; 275:41263-72. [DOI: 10.1074/jbc.M002308200] [PMID: 10998415]
- Kawase T, Okuda K, Yoshie H, Burns DM. Anti-TGF- β antibody blocks enamel matrix derivative-induced upregulation of P21WAF1/cip1 and prevents its inhibition of human oral epithelial cell proliferation. *J Periodontol Res.* 2002; 37:255-62. [DOI: 10.1034/j.1600-0765.2002.01615.x] [PMID: 12200968]
- Nebgen DR, Inoue H, Sabsay B, Wei K, Ho CS, Veis A. Identification of the chondrogenic inducing activity from bovine dentin (bCIA) as a low molecular mass amelogenin polypeptide. *J Dent Res.* 1999; 78:1484-94. [DOI: 10.1177/00220345990780090201] [PMID: 10512382]
- Al-Hezaimi K, Javed F, Al-Fouzan K, Tay F. Efficacy of the enamel matrix derivative in direct pulp capping procedures: a systematic review. *Aust Endod J.* 2013; 39:171-5. [DOI: 10.1111/j.1747-4477.2012.00357.x] [PMID: 24279667]
- Shayegan A, Petein M, Vanden Abbeele A. The use of beta-tricalcium phosphate, white MTA, white Portland cement and calcium hydroxide for direct pulp capping of primary pig teeth. *Dent Traumatol.* 2009; 25:413-9. [DOI: 10.1111/j.1600-9657.2009.00799.x] [PMID: 19519859]
- Mjör IA. Biological and clinical properties. In: Mjör IA, editor. *Dental Materials, Biological Properties and Clinical Evaluation.* Boca Raton: CRC Press; 1983. p.91-121.
- Tabarsi B, Parirokh M, Eghbal MJ, Haghdoost AA, Torabzadeh H, Asgary S. A comparative study of dental pulp response to several pulpotomy agents. *Int Endod J.* 2010; 43:565-71. [DOI: 10.1111/j.1365-2591.2010.01711.x] [PMID: 20456516]
- Danilović V, Petrović V, Marković B, Aleksić Z. Histological evaluation of platelet rich plasma and hydroxiapatite in apexogenesis: study on experimental animals. *Vojnosanit Pregl.* 2008; 65(2):128-34. [DOI: 10.2298/VSP0802128D] [PMID: 18365669]
- Olsson H, Davies JR, Holst KE, Schröder U, Petersson K. Dental pulp capping: effect of Emdogain® Gel on experimentally exposed human pulps. *Int Endod J.* 2005; 38(3):186-94. [DOI: 10.1111/j.1365-2591.2004.00932.x] [PMID: 15743422]
- Fransson H, Petersson K, Davies JR. Dentine sialoprotein and Collagen I expression after experimental pulp capping in humans using Emdogain Gel. *Int Endod J.* 2011; 44:259-67. [DOI: 10.1111/j.1365-2591.2010.01824.x] [PMID: 21166828]
- Kiatwateeratana T, Kintarak S, Piwat S, Chankanka O, Kamaolmatyakul S, Thearomontree A. Partial pulpotomy on caries-free teeth using enamel matrix derivative or calcium hydroxide: a randomized controlled trial. *Int Endod J.* 2009; 42:584-92. [DOI: 10.1111/j.1365-2591.2009.01552.x] [PMID: 19467054]
- Murray PE, Hafez AA, Smith AJ, Windsor LJ, Cox CF. Histomorphometric analysis of odontoblast-like cell numbers and dentine bridge secretory activity following pulp exposure. *Int Endod J.* 2003; 36(2):106-16. [DOI: 10.1046/j.1365-2591.2003.00632.x] [PMID: 12657154]

Хистолошки ефекти глеђних протеина на експонирану пулпу зуба

Маријана Поповић Бајић¹, Весна Даниловић², Бранислав Прокић³, Богомир Болка Прокић³, Милица Манојловић⁴, Славољуб Живковић¹

¹Универзитет у Београду, Стоматолошки факултет, Клиника за болести зуба, Београд, Србија;

²Универзитет у Београду, Стоматолошки факултет, Институт за хистологију, Београд, Србија;

³Универзитет у Београду, Факултет ветеринарске медицине, Катедра за хирургију, Београд, Србија;

⁴Институт за биолошка истраживања „Синиша Станковић“, Универзитет у Београду, Београд, Србија

Увод Директно прекривање пулпе је важан терапијски поступак примене лека на експонирану пулпу зуба, чији је циљ да обезбеди затварање пулпне коморе и омогући процес зарастања.

Циљ рада Циљ овог рада је био да се хистолошки испита ефекат глеђног емдогаина на експонирану пулпу зуба вијетнамске свиње (*Sus scrofa domestica*).

Методе рада Истраживање је урађено на 20 зуба вијетнамске свиње. На вестибуларним површинама секутића, очњака и првих премолара урађене су препарације кавитета V класе с експонирањем комора пулпе. У експерименталној групи перфорација је прекривана производом *Emdogain*[®] (*Straumann*, Базел, Швајцарска), а у контролној са *MTA*[®] (*Dentsply Tulsa Dental*, Џонсон Сити, Тенеси, САД). Сви кавитети су рестаурирани гласјономер-цементом (*GC Fuji VIII*, *GC Corporation*, Токио, Јапан). Период посматрања трајао је 28 дана, а након жртвовања животиња, направљени су хи-

столошки препарати на којима су анализирани постојање дентинског мостића, запаљењска реакција пулпе, реорганизација пулпног ткива и постојање бактерија.

Резултати На свим зубима експерименталне и контролне групе уочено је стварање дентинског мостића. Упала пулпе је била блага до умерена и у експерименталној и у контролној групи. Уочени су знаци неоангиогенезе и мноштво ћелија сличних одонтобластима које су одговорне за стварање дентинског мостића. Некроза није забележена ни у једном случају, као ни присуство бактерија у пулпи.

Закључак Хистолошка анализа је указала на повољне терапијске ефекте емдогаина у директном прекривању пулпе зуба вијетнамских свиња. Реакција пулпе била је слична онима које је изазвао МТА.

Кључне речи: директно прекривање пулпе; глеђни протеини; вијетнамске свиње

Примљен • Received: 22/01/2015

Прихваћен • Accepted: 23/03/2015