

## Red foxes (*Vulpes vulpes*) as reservoirs of respiratory capillariosis in Serbia

Tamara Ilić<sup>1</sup>, Zsolt Becskei<sup>2\*</sup>, Aleksandar Tasić<sup>3</sup>,  
Predrag Stepanović<sup>4</sup>, Katarina Radisavljević<sup>5</sup>, Boban Đurić<sup>6</sup>, Sanda Dimitrijević<sup>1</sup>

<sup>1</sup>Department for Parasitology, Faculty of Veterinary Medicine, University of Belgrade, 11000 Belgrade, Serbia

<sup>2</sup>Department for Animal Breeding and Genetics, Faculty of Veterinary Medicine,  
University of Belgrade, 11000 Belgrade, Serbia

<sup>3</sup>Public Health Institute “Niš”, 18000 Niš, Serbia

<sup>4</sup>Department for Equine, Small Animal, Poultry and Wild Animal Diseases,

<sup>5</sup>Department of Animal Hygiene,

Faculty of Veterinary Medicine, University of Belgrade, 11000 Belgrade, Serbia

<sup>6</sup>Veterinary Directorate, Regional Veterinary Inspection Office of Braničevo District, 12222 Braničevo, Serbia  
beckeizolt@gmail.com

Received: October 28, 2015    Accepted: May 16, 2016

### Abstract

**Introduction:** The aim of the study was to determine the prevalence of respiratory capillariosis in red foxes (*Vulpes vulpes*) in some regions of Serbia. **Material and Methods:** The study was conducted on 102 foxes in six epizootiological regions of Serbia, during the hunting season between 2008 and 2012. **Results:** The presence of respiratory capillariosis in all tested epizootiological regions was confirmed. The *E. aerophilus* nematode was detected with overall prevalence of 49.02%. The diagnosis of *E. aerophilus* infection was confirmed by the determination of morphological characteristics of adult parasites found at necropsy and the trichurid egg types collected from the bronchial lavage and the content of the intestine. **Conclusion:** The presented results contribute to better understanding of the epidemiology of this nematodosis in Serbia. However, the high prevalence of capillaries in tested foxes, demonstrated in all explored areas, might suggest that foxes from other regions in Serbia may also be infected. The fact that domestic carnivores and humans can also be infected enhances the importance of the overall epidemiological status. To establish the relevant prevalence of respiratory capillariosis, further investigations and continuous monitoring of parasitic fauna of carnivores are needed in the whole country.

**Keywords:** foxes, *Eucoleus aerophilus*, epidemiology, Serbia.

### Introduction

Respiratory capillariosis is a zoonotic disease, affecting both domestic and wild animals, as well as humans. The most common causative agent is the *Eucoleus aerophilus* (4) syn. *Capillaria aerophila* or *Thominx aerophilus* (11). This nematode is epidemically the most important species from the *Capillaria* genus. It can be found in the trachea and in the great bronchi, scarcely in the nasal cavity and frontal sinuses of cats (17), dogs (27), foxes (1, 25), coyotes (13), wolves (19), raccoons (23), bears, and other carnivores (6).

Male nematodes are about 32 mm long, while females are of 20-24 mm (26). The adult lungworms

are parasites in the bronchioles, bronchi, and trachea of the definitive host. The females lay eggs that are coughed, swallowed, and released *via* faeces into the environment. The eggs reach the infective stage in about 30-45 d. Alternatively, development to the infective larval stage may occur in earthworms (*i.e.* facultative intermediate hosts). Animals become infected by ingesting the embryonated eggs or the earthworms. After ingestion, the larvae migrate to the lungs, where they evolve into adult and reach their sexual maturity after about 3-6 weeks post infection (*p.i.*) (26).

A respiratory infection of the dogs and cats with *E. aerophilus* occurs sporadically and has a subclinical course. However, in the last decade there have been

many detected cases with clinical manifestation in animals (10), as well as infections in humans (15). Respiratory capillariosis has wide geographical distribution with cases described in North and South America, Europe, Asia, North Africa, and Australia (18). In Europe, it was most frequently diagnosed in wild canids (2, 9, 16, 21, 25). There are data on affected cats and dogs in Italy (10, 27), and also in cats in Portugal (17). Investigations conducted in Serbia indicated high prevalence (84%) of *E. aerophilus* in foxes in West Bačka region, Vojvodina (16). The epizootiological/epidemiological data on the dissemination and distribution of *E. aerophilus* in Europe are scarce and incomplete. It is assumed that climate change with global warming and geoclimatical changes are of great importance to the expansion of the disease (28). As the data on the occurrence of respiratory parasitic infections of wild carnivores in the region are insufficient (7, 8, 12, 20, 29), the aim of this survey was to establish the presence, distribution, and prevalence of respiratory capillariosis in fox populations in six different epizootiological regions in Serbia.

## Material and Methods

**Study period and area.** The study was conducted on 102 foxes, between 2008 and 2012. The foxes were culled during the hunting season in six epizootiological areas in Serbia: the West-Bačka, South-Banat, Kolubara, Braničevo, Raška, and Zaječar districts (Fig. 1).

**Sampling.** In order to determine the prevalence of infection with *E. aerophilus*, parasitic necropsy of the foxes was conducted, and adult and developmental stages of the parasites were assessed. All the tested foxes were adults with body weight ranging from 5.5 to 8.5 kg. Twenty foxes were culled in West-Bačka, 8 in Southern-Banat, 16 in Kolubara, 12 in Braničevo, 19 in Raška, and 27 in Zaječar districts.

The trachea, bronchi, and lungs were examined macroscopically; 25 g of lung parenchyma was examined by Baermann's method, and a tracheal lavage was performed as well. The trachea was opened and examined throughout its length with the larynx until the bifurcation under binocular microscope at 50× magnification. The material was examined fresh or preserved in 30% ethyl alcohol. A detailed morphometric and morphological analysis of trichurid egg types (3) and adult forms of the parasites found (22) was performed, and the obtained characteristics confirmed the presence of *E. aerophilus*.

In order to determine other helminthes (trematodes, cestodes, and other nematodes), morphological identification of the parasites was performed after necropsy. The mucosa of the small intestine was scraped and the intestinal contents were washed with tap water into 500 µm and 212 µm sieves by means of a water jet. Based on the shape, size, and

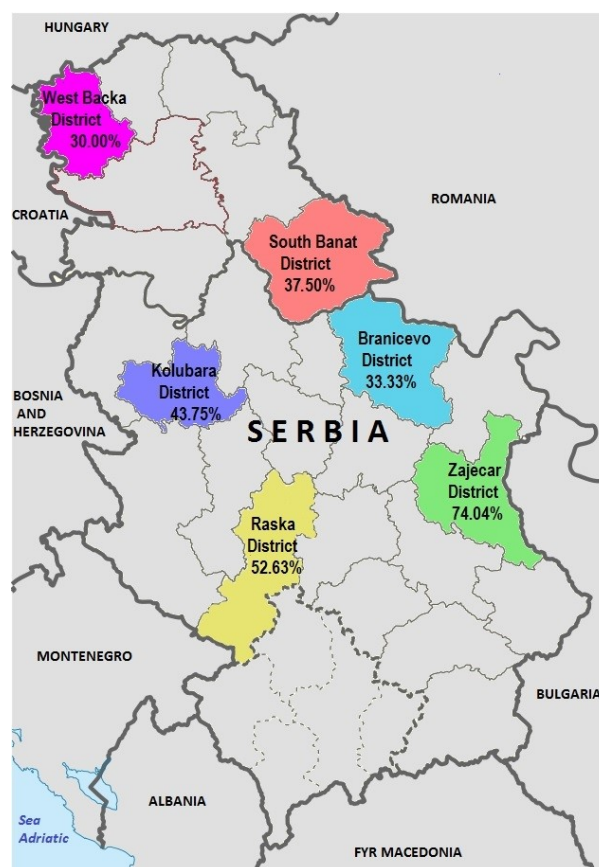
number of rostellar hooks of the parasites (30), they were initially diagnosed at the genus level as taenia worms.

The content of the intestine was examined by qualitative methods for the presence of helminth eggs and coccidia oocysts. The method applied was flotation in saturated aqueous NaCl solution (specific gravity of 1.200 at 20°C) and saturated aqueous ZnSO<sub>4</sub> solution (specific gravity 1.300 to 1.400 at 20°C).

The intensity of the infection was classified on the basis of the number of adult forms of *E. aerophilus* in the lungs: no worms, slight (1-5 adults), mild (5-20), and moderate (more than 20) infection.

## Results

The adult form of *E. aerophilus* lungworm was diagnosed in 50 out of 102 tested foxes from the territory of northern and central Serbia. In six districts analysed, the following prevalence of respiratory capillariosis was noted: in West-Bačka – 6 out of 20, in Southern-Banat – 3 out of 8, in Kolubara – 7 out of 16, in Braničevo – 4 out of 12, in Raška – 10 out of 19, and in Zaječar – 20 out of 27 (Fig. 1).



**Fig. 1.** Survey of distribution and prevalence of *E. aerophilus* in some districts of Serbia

Differences were detected ( $P < 0.05$ ) in the prevalence of capillariosis among different districts,

with the highest prevalence in Zajecar District (74.04%) (Table 1).

The intensity of infection varied from slight to moderate (range 1-34), with an average of nine adult worms detected. In 24 out of 102 foxes a moderate intensity of infection was established, slight intensity was detected in 20 out of 102, while moderate in 6 out of 102 (Fig. 2).

Using light microscopy, *E. aerophilus* barrel-like eggs (length 60-65  $\mu\text{m}$ , width 25-40  $\mu\text{m}$ ) with asymmetry of bipolar plugs and walls with a network of anastomosing ridges were detected (Fig. 3A). The parasite eggs were found in bronchial lavage and intestinal content. Differential diagnosis between similar eggs of *E. aerophilus* and *Trichuris vulpis*

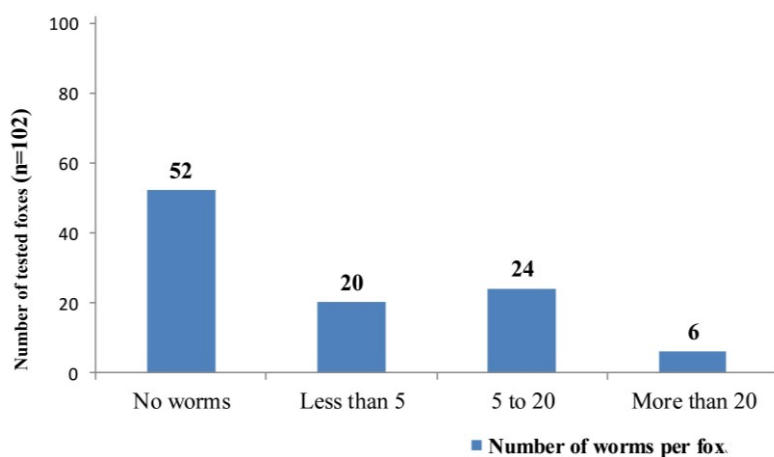
(Fig. 3B) was performed on the basis of the differences in size and symmetry of the polarities (*T. vulpis* eggs are 70-80  $\mu\text{m}$  long, 30-50  $\mu\text{m}$  wide and have symmetrically placed poles).

Seven species of endoparasites were detected in the intestinal contents of the infected foxes (Table 2), with the highest prevalence of *A. alata* species (47.05%) and *T. canis* (41.17%). In mixed infections, the most common was polyparasitism *A. alata* – *T. vulpis* and *T. canis* – *A. caninum* (18.62%). A slightly higher prevalence of trichiuriosis (28.43%) was diagnosed in relation to the prevalence of respiratory capillariosis (22.55%). No intestinal parasites were detected in 14.70% of the examined foxes.

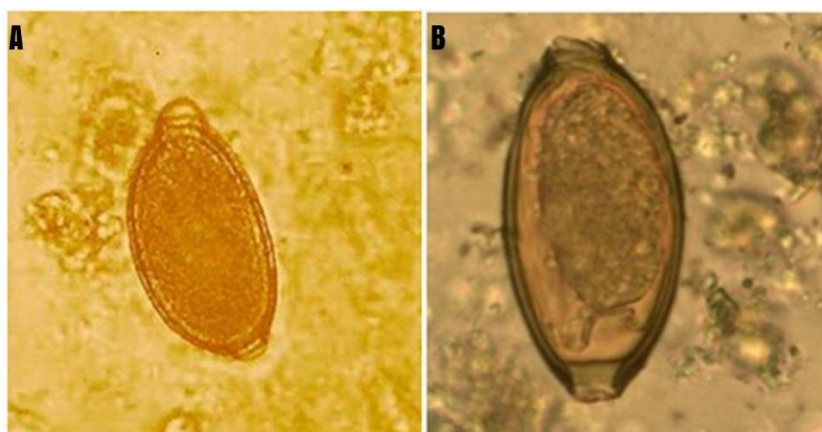
**Table 1.** The prevalence of respiratory capillariosis in foxes in six districts of Serbia between 2008 - 2012

District	Number of examined foxes	Number of positive foxes	Prevalence (%)	95% CI	$\chi^2$	P
West Backa	20	6	30.0%	9.92-50	11.56	0.04*
South Banat	8	3	37.5%	4-71		
Kolubara	16	7	43.75%	19.7-68		
Branicevo	12	4	33.33%	6.7-59.90		
Raska	19	10	52.63%	30.1-75.05		
Zajecar	27	20	74.04%	57.54-90.58		

\* P < 0.05



**Fig. 2.** Number of *E. aerophilus* adult nematodes per foxes



**Fig. 3.** Eggs of *Eucoleus aerophilus* (A) and *Trichuris vulpis* (B) detected in the content of the intestine (400 $\times$  magnification)

**Table 2.** Endoparasites detected in the content of the intestine of the tested foxes (N - number of foxes scored positive for endoparasites; % - infection rate)

Endoparasite species	Number of foxes		Mixed infections	Number of foxes	
	N	%		N	%
<i>Isospora</i> spp.	3	2.94	<i>A. alata</i> <i>T. vulpis</i>	19	18.62
<i>Alaria alata</i>	48	47.05	<i>A. alata</i> <i>E. aerophilus</i>	14	13.72
<i>Taenia</i> spp.	2	1.96	<i>T. canis</i> <i>A. caninum</i>	19	18.62
<i>Toxocara canis</i>	42	41.17	<i>A. alata</i> <i>T. canis</i> <i>T. vulpis</i>	7	6.86
<i>Ancylostoma caninum</i>	35	34.31	<i>A. alata</i> <i>E. aerophilus</i> <i>T. canis</i>	9	8.82
<i>Trichuris vulpis</i>	29	28.43	<i>T. canis</i> <i>T. vulpis</i> <i>A. caninum</i>	3	2.94
<i>Eucoleus aerophilus</i>	23	22.55	<i>T. canis</i> <i>A. caninum</i> <i>Isospora</i> spp.	2	1.96

## Discussion

*Eucoleus aerophilus* mainly affects the respiratory system of foxes, but it can also be found in dogs, cats, and other carnivores in some regions of Europe, as well as North and South America. The infection with this nematode is very frequent in wild carnivores, so the fact that infections of humans are not common may be surprising. Wild carnivores, usually highly infected foxes and jackals, are infection reservoirs for dogs and cats in urban areas (predominantly suburbs). As the disease has a zoonotic character, the risk of human infection, through cats and dogs is heightened (25, 28).

In different European countries, different prevalence of the infection was found in red foxes, e.g.: 5% in Zagreb county in Croatia (21), 66% in Hungary (25), 88% in Norway (9), and 0.3% in central Poland (2).

After the first human case of *E. aerophilus* infection in Serbia, there is an increased interest in the prevalence and distribution of the nematode in wild and domestic carnivores. The results of the present survey proved the presence of the *E. aerophilus* infection in all six examined districts of Serbia, with the overall prevalence of 49.02%. The highest prevalence was detected in Zaječar and Raška districts, where it reached 74.04% (95% CI: 57.54-90.58) and 52.63% (95% CI: 30.1-75.05), respectively. Zapadno-Bački and Braničevski districts showed a prevalence at 30.0% (95% CI: 9.92-50) and 33.33% (95% CI: 6.7-59.90), respectively. The prevalence of the infection in Južno-Banatski and Kolubarski districts reached 37.50% (95% CI: 4-71) and 43.75% (95% CI: 19.7-68) respectively. According to Lalošević *et al.* (16) who screened respiratory capillariosis of red foxes in the northern part of Serbia, the prevalence of this nematodosis was at the level of 84%. Our results showed a significantly lower prevalence in the majority of the tested districts, except Zaječar region. In other European countries, the prevalence of respiratory capillariosis of red foxes varied

in wide range from 0.3% to 88%. The most similar prevalence, compared to our results, was detected in Hungary 66% (25). In the suburbs of cities and villages, wild carnivores often share the habitat with cats and dogs. These observations are very valuable epizootiological data. It can be assumed that during more intensive urbanisation of cities, the contact between populations of cats, stray dogs, and foxes is going to be more frequent, proving that the epizootiology of respiratory capillariosis is becoming significantly important. It is obvious that the population of foxes is a constant reservoir of infection of domestic carnivores in the suburban areas. The survey conducted by Ilić *et al.* (14) on cats between 2003 and 2007 on the territory of Belgrade, including its suburbs, demonstrated that 8.03% of the cats were infected with *E. aerophilus*. The results of this research contribute to a better understanding of the epidemiology of respiratory capillariosis in Serbia.

To predict the spread of some zoonoses in certain regions of Serbia, for which foxes are the source of infection, it is crucial to monitor the parasitic fauna of these wild animals. Pulmonary capillariosis in humans has also been documented in France, Russia, Ukraine, and Iran (5). Due to the fact that a very limited number of human infections have been documented so far, the incubation period is unknown; however, some authors believe that it could be similar to the prepatent period in animals (5, 15). Since respiratory capillariosis is a potential threat to humans, preventive measures are of high importance (24).

This study contributes to a better understanding of the epizootiological situation of respiratory capillariosis of foxes in six investigated regions in Serbia. As wild carnivores are considerable reservoirs for infection of dogs and cats, the obtained data could promote some new strategies for the monitoring of parasitic infections of the hunted foxes. Such monitoring could be carried out in the future as a part of the routine diagnostic procedure.

**Conflict of Interests Statement:** The authors declare that there is no conflict of interests regarding the publication of this article.

**Financial Disclosure Statement:** The research and the article were financed with the Authors' own funds, with the support of the Ministry of Science and Technological Development of Republic of Serbia.

**Animal Rights Statement:** The survey was conducted on culled foxes.

## References

- Al-Sabi S.N.M., Halasl T., Kapel O.M.: Infections with cardiopulmonary and intestinal helminths and sarcoptic mange in red foxes from two different localities in Denmark. *Acta Parasitol* 2014, 59, 98–107.
- Borecka A., Gawor J., Malczewska M. Malczewski A.: Prevalence of zoonotic helminth parasites of the small intestine in red foxes from central Poland. *Med Weter* 2009, 65, 33–35.
- Conboy G.A.: Helminth parasites of the canine and feline respiratory tract. *Vet Clin North Am Small Anim Pract* 2009, 39, 1109–1126.
- Creplin F.C.H.: Eingeweidewürmer, Finnenwürmer, Thierwürmer, Allg. In: *Encycl. d. Wissensch u. Kunst. Ersch & Gruber. Leipzig*, 1839, 1 Sect. pp. 277–302.
- Cross J.H.: Capillariosis. In: *Zoonoses. Biology, Clinical Practice, and Public Health Control*. Edited by Palmer S.R., Lord Soulsby, Simpson D.I.H., Oxford University Press, 1998, pp. 789–802.
- Crum J.M., Nettles V.F., Davidson W.R.: Studies on endoparasites of the black bear (*Virus americanus*) in the south eastern United States. *J Wild Dis* 1978, 14, 178–186.
- Ćirović D., Pavlović I., Penezić A.: Intestinal helminth parasites of the grey wolf (*Canis lupus* L.) in Serbia. *Acta Vet Hung* 2015, 63, 189–198.
- Ćirović D., Penezić A., Pavlović I., Kulišić Z., Čosić N., Burazerović J., Maletić V.: First records of *Dilofilaria repens* in wild canids from the region of Central Balkan. *Acta Vet Hung* 2014, 62, 481–488.
- Davidson R.C., Gjerde B., Vihoren T., Lillehaug A., Handerland H.: Prevalence of *Trichinella* larvae and extra-intestinal nematodes in Norwegian red foxes (*Vulpes vulpes*). *Vet Parasitol* 2006, 136, 307–316.
- Di Cesare A., Castagna G., Otranto D., Meloni S., Milillo P., Latrofa S.M., Paoletti B., Bartolini R., Traversa D.: Molecular diagnosis of *Capillaria aerophila*, an agent of canine and feline pulmonary capillariosis. *J Clin Microbiol* 2012, 50, 1958–1963.
- Dujardin F.: Histoire naturelle des helminthes ou vers intestinaux. In: *Encyclopedie de Roret*. Paris, France, 1845, p. 654.
- Gavrilović P., Blitva-Robertson G., Özvegy J., Kiskároly F., Beeskei Z.: Case report of dirofilariasis in grey wolf in Serbia. *Acta Parasitol* 2015, 60, 175–178.
- Gompper M.E., Goodman R.M., Kays R.W., Ray J.C., Fiorello C.V., Wade S.E.: A survey of parasites of coyotes (*Canis latrans*) in New York based on fecal analysis. *J Wild Dis* 2003, 39, 712–717.
- Ilić T., Dimitrijević S., Mitrović S., Džamić A., Djurić B.: Capillariosis - opportunistic zoonosis. In: *Proc book of the XIV Annual X Conference of Veterinarians of the Republic of Srpska Jahorina. Bosnia and Herzegovina*. 2009, p. 78.
- Lalošević D., Lalošević V., Klem I., Stanojev-Jovanović D., Pozio E.: Pulmonary capillariosis miming bronchial carcinoma. *Am J Trop Med Hyg* 2008, 78, 14–16.
- Lalošević V., Lalošević D., Čapo I., Simin V., Galfi A., Traversa D.: High infection rate of zoonotic *Eucoleus aerophilus* infection in foxes from Serbia. *Parasite* 2013, 20, 1–5.
- Madeira de Carvalho L.M., Pereira da Fonseca L.M., Gomes L., Meireles J.M.: Lungworms in domestic and wild carnivores in Portugal: rare parasites or rarely diagnosed? *Proceedings of 19<sup>th</sup> Annual Congress of the European College of Veterinary Internal Medicine, Porto, Portugal, 2009*, p. 28.
- Mc Carthy J., Moore T.A.: Emerging helminth zoonoses. *Int J Parasitol* 2000, 30, 1351–1360.
- Pence D.B., Bryant F.C.: Effect of short term coyote removal on populations of coyote helminths. *J Wild Dis* 2002, 38, 54–67.
- Penezić A., Selaković A., Pavlović I., Ćirković D.: First findings and prevalence of adult heartworms (*Dirofilaria immitis*) in wild carnivores from Serbia. *Parasitol Res* 2014, 113, 3281–3285.
- Rajković R., Marinculić A., Bosnić S., Benić M., Vinković B., Mihaljević Ž.: Prevalence and seasonal distribution of helminth parasites in red foxes (*Vulpes vulpes*) from the Zagreb County (Croatia). *Z Jagdwiss* 2002, 48, 151–160.
- Romashov B.V.: Three capillariid species (Nematoda, Capillariidae) of carnivores (Carnivora) and discussion of system and evolution of the nematode family Capillariidae. 1. Redescription of *Eucoleus aerophilus* and *E. boehmi*. *Zool Zh* 2000, 79, 1379–1391.
- Schuster R., Nöckler K., Mix H.: Helminth findings in indigenous racoon dogs *Nyctereutes procyonoides* (Gray, 1834). *Berl Munch Tierarztl Wochenschr* 2001, 114, 273–276.
- Stanojev-Jovanović D., Kuruc V., Pavlović S., Perin B., Klem I., Lalošević D.: *Eucoleus (Capillaria) aerophila* i eozinofilna pneumonija, Zbornik Radova Majski Pulmolški Dani, 2006, 229–233.
- Szell Z., Marucci G., Pozio E., Vorgi I.: Extraintestinal nematode infections of red foxes (*Vulpes vulpes*) in Hungary. *Vet Parasitol* 2003, 115, 329–334.
- Traversa D., Di Cesare A., Li R.P., Castagn G., Meloni S., Heine J., Strube K., Milillo P., Otranto D., Meckes O., Schaper R.: New insights into morphological and biological features of *Capillaria aerophila* (Trichocephalida, Trichuridae). *Parasitol Res* 2011, 109, 97–104.
- Traversa D., Di Cesare A., Milillo P., Iorio R., Otranto D.: Infection by *Eucoleus aerophilus* in dogs and cats: is another extra-intestinal parasitic nematode of pets emerging in Italy *Res Vet Sci* 2009, 87, 270–272.
- Traversa D., Di Cezare A., Conboy G.: Canine and feline cardiopulmonary parasitic nematodes in Europe: emerging and underestimated. *Parasit Vectors* 2010, 3, 62.
- Vengušt G.: Intestinal parasites of the red fox (*Vulpes vulpes*) in Slovenia. *Acta Vet Hung* 2013, 61, 454–462.
- Verster A.: A taxonomic revision of the genus *Taenia* Linnaeus, 1758. *Onderstepoort J Vet Res* 1969, 36, 3–58.