

HISTOCHEMICAL CHARACTERISTICS AND DISTRIBUTION OF LIPOFUSCIN AND POLYGLUCOSAN BODIES IN THE BRAIN OF DOGS MORE THAN 10 YEARS OLD

NEŠIĆ Sladjan^{1*}, VUČIĆEVIĆ Ivana¹, MARINKOVIĆ Darko¹, KUKOLJ Vladimir¹, ANIČIĆ Milan¹, RISTOSKI Trpe², NIKOLIĆ Sonja³, ALEKSIĆ KOVAČEVIĆ Sanja¹

¹University of Belgrade, Faculty of Veterinary Medicine, Serbia;

²Cyrl and Methodius University, Faculty of Veterinary Medicine, Skopje, North Macedonia;

³PI Vaso Butozan Veterinary Institute of the Republic of Srpska, Banja Luka, Bosnia and Herzegovina

Received 02 October 2020; Accepted 14 January 2021

Published online: 23 February 2021

Copyright © 2021 Nešić et al. This is an open-access article distributed under the Creative Commons Attribution License, which permits unrestricted use, distribution, and reproduction in any medium, provided the original work is properly cited

How to cite: Nešić Sladjan, Vučićević Ivana, Marinković Darko, Kukolj Vladimir, Aničić Milan, Ristoski Trpe, Nikolić Sonja, Aleksić Kovačević Sanja. Histochemical characteristics and distribution of lipofuscin and polyglucosan bodies in the brain of dogs more than 10 years old. *Veterinarski Glasnik*, 2021. 75 (1): 57-68. <https://doi.org/10.2298/VETGL201002001N>

Abstract

The ageing process is accompanied by numerous changes in the brain of dogs, such as accumulation of amyloid, fibrosis of blood vessel walls and meninges, accumulation of lipofuscin, and the presence of polyglucosan bodies (PGBs), satellitosis and neuronophagia. In this study, the presence of lipofuscin and PGBs in various parts of the brain in dogs of different sexes and ages was examined. For this purpose, brain samples were stained using haematoxylin eosin, modified Ziehl Neelsen and Periodic acid Schiff (PAS) methods. Lipofuscin was visualised by Ziehl Neelsen and PAS methods of specific staining on the same brain tissue segments. Lipofuscin had accumulated in 93% of old (more than 10 years old) dog brains, mostly in neurons of the medulla oblongata. The percentage of age-related lipofuscin pigment in other examined brain tissue segments was lower than in the medulla oblongata. There was a small difference in the percentage of lipofuscin-positive individuals between the two staining methods. The presence of PGBs was established by the PAS method for the vast majority (about 93%) of the old dogs (more than 10 years old), while PGBs were not detected in the group of young dogs (up to 5 years old). However, PGBs occurred in all examined segments of the dog's brain tissues (for each of the tissue types, from 90% to 93% of dogs were positive for PGBs). The results obtained the oldest dogs (15 years old) harboured PGBs both extracellularly and intracellularly, while

*Corresponding author – e-mail: sladjan@vet.bg.ac.rs

in other dogs, only extracellular PGBs were seen. Lipofuscin was accumulated mostly in large neurons of olivary nuclei of the medulla oblongata. PGBs were confirmed in all examined segments of the brain tissue of dogs more than 10 years old. This is one of the numerous indications that old dogs could be a very good animal model for studying the normal ageing process or neurodegenerative diseases.

Key words: dog, ageing process, brain, lipofuscin, polyglucosan bodies

INTRODUCTION

The ageing process is a phenomenon that has been studied for centuries, but even today there is no complete and unique definition of age, nor a comprehensive explanation of the ageing process. During the ageing process, amyloid accumulates as extracellular deposits in the dog brain, while lipofuscin granules can be observed intracellularly in the neurons of dog brain (Torp et al., 2000, Rofina et al., 2003, Papaioannou, 2014, Nešić et al., 2017).

Lipofuscin accumulates slowly over time, more intensely in the final stages of the ageing process (Jung et al., 2010). Lipofuscin is an ageing pigment that accumulates in greater amounts in non-dividing cells (muscle cells, heart muscle cells and neurons) (Porta, 2002, Gray and Woulfe, 2005, Terman et al., 2007, Gilissen et al., 2016).

Intracellular lipofuscin production is a very complex process, as biochemical reactions affecting production occur in lysosomes, cytoplasm and mitochondria (Jung et al., 2010). Lipofuscin accumulates due to incomplete degradation of proteins, lipids and damaged organelles. The accumulation of metabolic products and damaged intracellular components is the result of insufficient and reduced autophagy in postmitotic cells (Kurz et al., 2007, Kurz et al., 2010). Factors that promote oxidative processes in the cell increase accumulation of metabolic products, leading to an increased amount of lipofuscin (Brunk and Terman, 2002a). Lipofuscin can occupy a major portion (40 to 75%) of the cell volume. Such a large amount of pigment fills the cytoplasm and initially results in a decrease of functional capacity, but later leads to apoptotic cell death (Jung et al., 2007).

Polyglucosan bodies (PGBs) occur in the brain and other organs of humans and animals. There are several forms of PGBs, such as corpora amylacea (CA), Lafora bodies, Lafora-like bodies, and others (Gredal et al., 2003, Márquez et al., 2010). CA in humans are analogous with PGBs in dogs, and they occur physiologically in humans during the ageing process. Lafora bodies are intracellular bodies found in patients with myoclonic epilepsy. PGBs, both intracellular and extracellular, occur normally in the ageing process of dog and cat brains, and are designated as Lafora-like bodies (Cavanagh, 1999, Borrás et al., 1999, Lohi et al., 2005).

The aim of this study was, for the first time, to prove the presence and distribution of lipofuscin and PGBs in the brain of dogs over 10 years old in Serbia, as well as to determine some of the histochemical characteristics of these pigment and inclusions.

MATERIALS AND METHODS

In this study, 36 dogs were necropsied. The dogs were randomly selected and divided into two groups (Table 1). The group of young dogs (group A) consisted of six dogs of different breeds and sexes (three males, three females) under five years old. The old dogs (group B) consisted of 13 males and 17 females over ten years old. During necropsy, the brain was removed, macroscopically examined and fixed in 10% neutral buffered formalin for six days. Coronal sections of the frontal cerebral cortex, parietal cerebral cortex, hippocampus, cerebellum and medulla oblongata were routinely processed, embedded in paraffin, cut into 4-6µm thick sections and stained using the haematoxylin and eosin (HE), long Ziehl Neelsen (Bancroft and Cook, 1984) and Periodic acid Schiff (PAS) methods. The stained tissues were analysed by light microscopy (Olympus, BX51) and sections with characteristic findings were captured by a digital camera (Olympus ColorView III).

Table1. Necropsied dogs and distribution of lipofuscin and PGBs in examined dog brains

No	Group	Breed	Gender	Age (years)	Lipofuscin	PGB (P/N)	Euthanised (E) / Died (D)
1	A	Mongrel	Male	0.8	-	N	U
2	A	Boxer	Female	2	-	N	U
3	A	American Staffordshire Terrier	Male	2.5	-	N	U
4	A	West Highland White Terrier	Male	1.9	-	N	U
5	A	Mongrel	Female	5	Mo	N	E
6	A	Chow Chow	Female	4.5	-	N	U
7	B	Pekingese	Female	12	-	P	D
8	B	Irish Setter	Female	13	Fc, Mo	P	D
9	B	Mongrel	Male	15	+	P	E
10	B	English Cocker Spaniel	Female	12	Mo	N	E
11	B	Mongrel	Male	17	+	P	E
12	B	Yugoslavian Shepherd Dog	Female	15	+	P	E
13	B	Pekingese	Female	14	Fc, Pc, Hc, Mo	P	E
14	B	Mongrel	Male	18	+	P	E
15	B	Mongrel	Female	12	Mo	N	E
16	B	Poodle	Male	14	Fc,Hc,C	P*	D
17	B	Mongrel	Female	14.5	Fc, Pc, Hc, Mo	P	E
18	B	Rottweiler	Male	13	Pc, Mo	P	D
19	B	Mongrel	Male	15	Fc, Hc, Mo	P	E

cont. Table 1.

20	B	Mongrel	Female	12	Fc, Hc, Mo	Hc, C, Mo	E
21	B	American Staffordshire Terrier	Female	12	+	P	E
22	B	Mongrel	Female	18	Fc, Pc, C, Mo	P*	E
23	B	English Cocker Spaniel	Female	10	Pc, Mo	P	E
24	B	Irish Setter	Female	14	Fk, Pm, Mm	P	E
25	B	Mongrel	Female	15	+	P	E
26	B	Labrador	Male	13	+	P*	E
27	B	Mongrel	Male	12	+	P	E
28	B	Mongrel	Female	16	+	P*	E
29	B	German Shepherd	Male	13	-	P	D
30	B	Mongrel	Female	14	+	P	E
31	B	Mongrel	Female	13	Pm	P	E
32	B	Poodle	Male	16	+	P	E
33	B	Mongrel	Male	16.5	+	P	E
34	B	Mongrel	Male	16	+	P	E
35	B	Mongrel	Female	12	-	P	E
36	B	Mongrel	Male	17	+	P	D

Legend: + (Lipofuscin in all examined segments of the brain, stained by one or both methods), - (lipofuscin not detected in any examined segments of brain, stained by both methods), P (PGBs in all examined segments of the brain, extracellular accumulation), P* (PGBs in all examined segments of the brain, extracellular and intracellular accumulation), N (PGBs not detected in any of examined segments of the the brain), Fc (Frontal cortex), Pc (Parietal cortex), Hc (Hippocampus), C (Cerebellum), Mo (Medulla oblongata)

RESULTS

Lipofuscin occurred in several large neurons of the medulla oblongata of only one group A dog (Figure 1a and 2a), accumulated in a small amount in the cytoplasm and conventionally arranged around the nucleus in the form of fine granules, which stained red using PAS method. In group B dogs, tissue stained with HE showed the granular

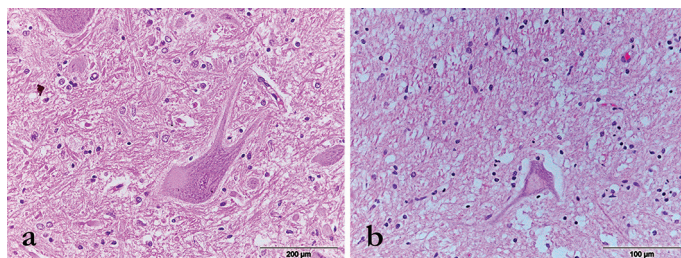


Figure 1. Lipofuscin (red granules) in neurons from the medulla oblongata of young and old dogs, **a)** 5-year-old dog; **b)** 18-year-old dog. Haematoxylin-eosin staining.

structure of light brown to brown lipofuscin that was easily distinguished from the eosinophilic cytoplasm (Figure 1b). The presence of lipofuscin was considerably more common in group B than in group A dog brains (Figure 2). In all examined brain tissue segments, various percentages of the studied dogs had accumulated lipofuscin in neurons (Figure 3) and lipofuscin granules were located perinuclearly as well as in the dendritic tree and the axon. The presence of lipofuscin pigment was demonstrated in large neurons of olivary nuclei of the medulla oblongata in 28 dogs (93.33%) using both methods of specific lipofuscin staining (Figure 2b and 4a). In addition to the medulla oblongata, in all other examined segments, the presence of lipofuscin granules in the neurons of group B dogs was confirmed using the long Ziehl Neelsen method (56% -74%) and the PAS staining method (60% -76%) (Figure 3).

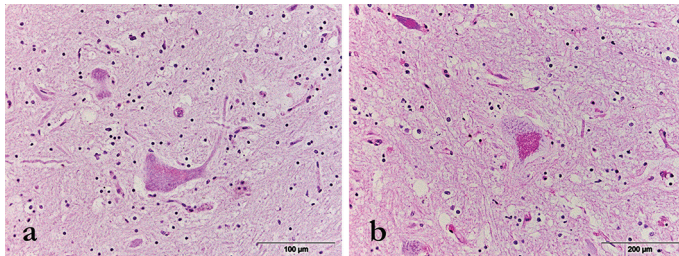


Figure 2. Lipofuscin in neurons (arrows) of medulla oblongata, **a)** 5-year-old dog; **b)** 18-year-old dog. Periodic acid Schiff staining.

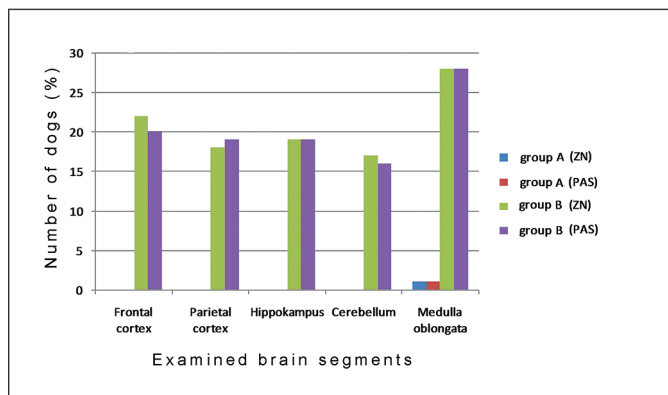


Figure 3. Distribution of lipofuscin in examined brain segments. Long Ziehl Neelsen and Periodic acid Schiff staining.

PGBs were present as PAS-positive spheroids and were mainly located in the neuropil in all examined brain tissue segments (Figure 5). Morphologically, they appeared, either as oval-shaped structures with central parts of a dark-purple to violet colour with light pink to pink halo, or as a homogeneous pink spheroid (Figure 5). PGBs were demonstrated in almost all group B dogs, but they were not present in group A dogs (Figure 6). PGBs in all examined brain tissue segments of group B dogs occurred

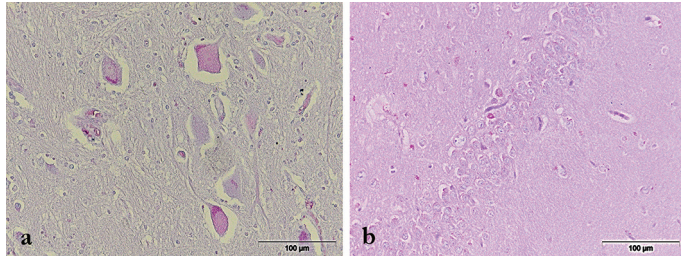


Figure 4. Lipofuscin (red granules) in neurons from different brain regions, **a)** medulla oblongata, 12-year-old dog, **b)** hippocampus (Ammon horn), 18-year-old dog. Long Ziehl Neelsen staining.

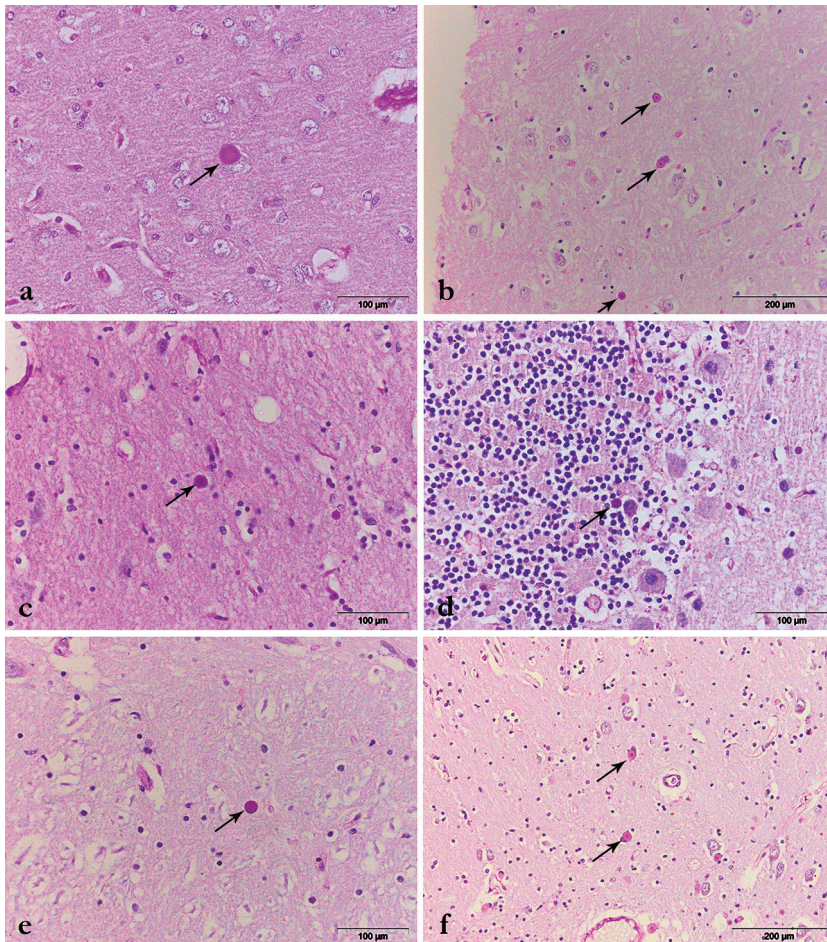


Figure 5. Polyglucosan bodies (arrows) in different brain regions, **a)** intracellular, frontal lobe, 18-year-old dog, **b)** extracellular and intracellular, hippocampus, 16-year-old dog, **c)** extracellular, hippocampus, 12-year-old dog, **d)** extracellular, cerebellum, 12-year-old dog, **e)** extracellular, medulla oblongata, 15-year-old dog, **f)** intracellular, parietal lobe, 16-year-old dog. Periodic acid Schiff staining.

intracellularly only in individual cases, in the hippocampus, parietal lobe, and in a cerebellum of dogs more than fifteen years old. Moreover, PGBs in the cerebellum, and frontal and parietal cortices were most often localised in molecular layers, while in the medulla oblongata, they were diffusely distributed. The number of PGBs depended on the age of the group B dogs. The presence of a large number of PGBs in the neuropil and intracellularly was observed in older dogs (more than 15 years old).

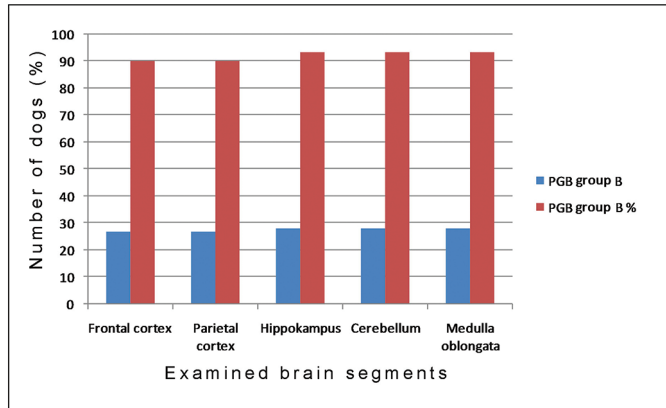


Figure 6. Distribution of polyglucosan bodies in different brain segments. Periodic acid Schiff staining.

DISCUSSION

Some authors believe that dogs can be divided into three groups based on several criteria clinical evidence and morphological changes in the brain according to age. The three dog groups were: young dogs up to 5 years old, middle-aged dogs (5 to 10 years old) and old dogs (more than 10 years old). Dogs more than 10 years old show symptoms of cognitive dysfunction caused by morphological changes in the brain (Rofina et al., 2003, Youssef et al., 2016).

In this study, the presence of lipofuscin in neurons from specific parts of the brain in dogs of different ages was examined. The results obtained with both specific staining methods indicated that lipofuscin was accumulated mostly in large neurons of the olivary nuclei of medulla oblongata (in 93% of dogs), while less lipofuscin occurred in other examined segments. Using both methods of specific staining on the same brain tissue segments, a small difference in the percentages of lipofuscin-positive individuals was observed. The percentage of positive cases stained by the long Ziehl Neelsen method ranged from 56% to 70%, while the PAS-positive cases ranged from 60% to 76% of all examined segments except for medulla oblongata. This indicates the PAS staining method is more sensitive for lipofuscin detection than the long Ziehl Neelsen staining method.

PAS staining of lipofuscin is thought to be due to insoluble lipid components, since PAS-positive substances are glycolipids or glycoproteins. The intensity of lipofuscin staining with carbol fuchsin increases with age, but the cause of this phenomenon is not yet clarified. It is known that acid resistance in *Mycobacterium* spp. is due to the high molecular weight of mycolic acid, which is composed of a large number of hydroxylated fatty acids. Therefore, the positivity of lipofuscin to Ziehl Neelsen staining could be a consequence of the presence of polymerised fatty acids (Benavides et al., 2002). We believe the long Ziehl Neelsen staining method was less sensitive to lipofuscin than the PAS method in our study precisely because of the polymerised fatty acid component of lipofuscin.

The amount of accumulated lipofuscin in the brain of group B dogs varied, but the most intensive accumulation was found in the oldest dogs, which is consistent with the literature data (Borras et al., 1999). We observed various amounts of accumulated lipofuscin in different brain segments, while the most significant accumulation was in the medulla oblongata, which is in accordance with other author's data (Double et al., 2008).

According to the literature, lipofuscin has been characterised as PAS-positive, acid resistant (stained by long Ziehl-Neelsen technique), argyrophilic and it can be stained with lipid stains such as Sudan Black and Oil-red-O. The tinctorial properties of lipofuscin increase in older dogs. Lipofuscin contains autofluorescent granules (golden yellow). In unstained tissue samples, lipofuscin can be visualised using fluorescence or laser scanning microscopy with the help of excitation light of different wavelengths and using different filters (Brunk and Terman, 2002b).

Similar to the literature data, the results of this study show the presence of PGBs in the brain of old dogs is a common finding, and the PGBs appear extracellularly and/or intracellularly.

Some authors have noted PGBs are present in astrocytes as corpora amylacea (CAs), and in neurons as Lafora bodies. In the human population, CAs and Lafora bodies are normally present in the brain during the ageing process, while their number significantly increases in patients with Alzheimer's disease and myoclonic epilepsy (Borras et al., 1999, Lohi et al., 2005). The two types of PGBs observed in the human brain are well defined immunohistochemically. Unlike in humans, PGBs in animals are not fully defined, i.e., various results were obtained in numerous studies (Borras et al., 1999, Gredal et al., 2003). Immunohistochemical analysis of multiple markers showed different immuno-positive reactions in various brain segments. Therefore, some authors consider that PGBs in a cerebellum originate from neurons, and in other parts of the brain are derived from neurons and glial cells (Gredal et al., 2003).

In this study, the presence of PGBs in brain tissue was proven by PAS staining. PGBs occurred in the vast majority (93%) of old dogs, but were not observed in young dogs. Among the old dogs, PGBs were found in all examined brain tissue segments. Moreover, PGBs were observed extracellularly and intracellularly in the brains of the

oldest dogs, but in other dogs were only extracellular. Since in the examined brain segments of dogs, PGBs were primarily located extracellularly, they could not be corpora amylacea or Lafora bodies. Some authors have found that PAS-positive PGBs produced during the ageing process were ubiquitin- and neurofilament-negative. Taking into consideration the obtained results of double-staining by the PAS and immunohistochemical methods on glial fibrillary acid protein, as well as the absence of an immuno-positive reaction on ubiquitin in their research, other authors labelled these PGBs as Lafora bodies. The results obtained by double-staining indicated the PGBs were not related to the astrocytic processes (Borras et al., 1999).

CONCLUSION

The results obtained show, for the first time, the presence and characteristics of lipofuscin and PGBs in the brain of dogs more than 10 years old in Serbia. Lipofuscin occurred more frequently in the medulla oblongata than in other brain tissue segments. Most PGBs in all examined brain tissue segments of dogs more than 10 years old were extracellular. The results show the changes we found in the old dog brain were similar to those reported in the literature. Also, the results obtained indicate some similarity between all the changes we found in the old dog brain and changes described as normal in the process of human ageing, and in patients with neurodegenerative disorders like Alzheimer's disease. This is one of numerous indications that old dogs could make a very good animal model for studying the normal ageing process or neurodegenerative diseases. Similarly, future research could give an answer as to what extent the relative age (age of the individual in regard to the lifespan of the breed) affects the development of changes in the brain and the effect of these changes on the individual's cognitive abilities.

Acknowledgement

The study was supported by the Ministry of Education, Science and Technological Development of the Republic of Serbia (Contract number 451-03-68/2020-14/200143).

Authors' contributions

SladjanN carried out experimental work and contributed to laboratory work and to drafting the manuscript. DM, IV, MA contributed to the experimental work and performed pathohistological analyses. DM, VK, TR, SonjaN contributed to drafting the manuscript. SAK contributed to drafting the manuscript and gave his final approval. All authors read and approved the final manuscript.

Competing interests

The authors declare they have no potential conflicts of interest with respect to the research, authorship and/or publication of this article.

REFERENCES

- Benavides S.H., Monserrat A.J., Fariña S., Porta E.A. 2002. Sequential histochemical studies of neuronal lipofuscin in human cerebral cortex from the first to the ninth decade of life. *Archives of Gerontology and Geriatrics*, 34(3):219-231. [http://dx.doi.org/10.1016/s0167-4943\(01\)00223-0](http://dx.doi.org/10.1016/s0167-4943(01)00223-0)
- Borras D., Ferrer I., Pumarola M. 1999. Age-related changes in the brain of the dog. *Veterinary Pathology*, 36:202-211. <http://dx.doi.org/10.1354/vp.36-3-202>
- Brunk U.T., Terman A. 2002a. Lipofuscin: mechanisms of age-related accumulation and influence on cell function. *Free Radical Biology and Medicine*, 33(5):611-619. [http://dx.doi.org/10.1016/s0891-5849\(02\)00959-0](http://dx.doi.org/10.1016/s0891-5849(02)00959-0)
- Brunk U.T., Terman A. 2002b. The mitochondrial-lysosomal axis theory of aging: accumulation of damaged mitochondria as a result of imperfect autophagocytosis. *European Journal of Biochemistry*, 269(8):1996-2002. <http://dx.doi.org/10.1046/j.1432-1033.2002.02869.x>
- Cavanagh J.B. 1999. Corpora-amyloacea and the family of polyglucosan diseases. *Brain Research. Brain Research Reviews*, 29(2-3):265-295. [http://dx.doi.org/10.1016/s0165-0173\(99\)00003-x](http://dx.doi.org/10.1016/s0165-0173(99)00003-x)
- Double L.K., Dedov N.V., Fedorov H., Kettle E., Halliday M.G., Garner B. Brunk T.U. 2008. The comparative biology of neuromelanin and lipofuscin in the human brain. *Cellular and Molecular Life Sciences*, 65(11):1669-1682. <http://dx.doi.org/10.1007/s00018-008-7581-9>
- Gilissen E.P., Leroy K., Yilmaz Z., Kövari E., Bouras C., Boom A., Poncelet L., Erwin J.M., Sherwood C.C., Hof P.R., Brion J.P. 2016. A neuronal aging pattern unique to humans and common chimpanzees. *Brain Structure and Function*, 221(1):647-664. <http://dx.doi.org/10.1007/s00429-014-0931-5>
- Gray D.A., Woulfe J. 2005. Lipofuscin and aging: a matter of toxic waste. *Science of Aging Knowledge Environment*, 2005(5):re1. <http://dx.doi.org/10.1126/sageke.2005.5.re1>
- Gredal H., Berendt M., Leifsson P.S. 2003. Progressive myoclonus epilepsy in a beagle. *Journal of Small Animal Practice*, 44(11):511-514. <http://dx.doi.org/10.1111/j.1748-5827.2003.tb00113.x>
- Jung T., Bader N., Grune T. 2007. Lipofuscin – formation distribution and metabolic consequences. *Annals of the New York Academy of Sciences*, 1119:97-111. <http://dx.doi.org/10.1196/annals.1404.008>
- Jung T., Höhn A., Grune T. 2010. Lipofuscin: detection and quantification by microscopic techniques, *Methods in Molecular Biology*, 594:173-193. http://dx.doi.org/10.1007/978-1-60761-411-1_13
- Kurz T., Eaton J.W., Brunk U.T. 2010. Redox activity within the lysosomal compartment: implications for aging and apoptosis. *Antioxidants and Redox Signaling*. 13(4):511-523. <http://dx.doi.org/10.1089/ars.2009.3005>
- Kurz T., Terman A., Brunk U.T. 2007. Autophagy, ageing and apoptosis: the role of oxidative stress and lysosomal iron. *Archives of Biochemistry and Biophysics*. 462(2):220-230. <http://dx.doi.org/10.1016/j.abb.2007.01.013>
- Lohi H., Ianzano L., Zhao X.C., Chan E.M., Turnbull J., Scherer S.W., Ackerley C.A., Minassian B.A. 2005. Novel glycogen synthase kinase 3 and ubiquitination pathways in progressive myoclonus epilepsy. *Human Molecular Genetics*, 14:2727-2736. <http://dx.doi.org/10.1093/hmg/ddi306>

- Márquez M., Pérez L., Serafín A., Teijeira S., Navarro C., Pumarola M. 2010. Characterisation of Lafora-like bodies and other polyglucosan bodies in two aged dogs with neurological disease. *Veterinary Journal*, 183(2):222-225. <http://dx.doi.org/10.1016/j.tvjl.2008.10.002>
- Nešić S., Kukulj V., Marinković D., Vučićević I., Jovanović M. 2017. Histological and immunohistochemical characteristics of cerebral amyloid angiopathy in elderly dogs. *Veterinary Quarterly*, 37(1):1-7. <http://dx.doi.org/10.1080/01652176.2016.1235301>
- Papaioannou N. 2014. Principles of age-related changes in the canine and feline brain. *Acta Veterinaria-Beograd*, 64(1):1-9. <http://dx.doi.org/10.2478/acve-2014-0001>
- Porta E.A. 2002. Pigments in aging: an overview. *Annals of the New York Academy of Sciences*, 959:57-65. <http://dx.doi.org/10.1111/j.1749-6632.2002.tb02083.x>
- Rofina J., Van Andel I., Van Ederen A.M., Papaioannou N., Yamaguchi H., Gruys E. 2003. Canine counterpart of senile dementia of the Alzheimer type: amyloid plaques near capillaries but lack of spatial relationship with activated microglia and macrophages. *Amyloid*, 10:86-96. <http://dx.doi.org/10.3109/13506120309041730>
- Terman A., Gustafsson B., Brunk U.T. 2007. Autophagy, organelles and ageing. *Journal of Pathology*, 211(2):134-143. <http://dx.doi.org/10.1002/path.2094>
- Torp R., Head E., Cotman C.W. 2000. Ultrastructural analyses of β -amyloid in the aged dog brain: neuronal β -amyloid is localized to the plasma membrane. *Progress in Neuro-psychopharmacology and Biological Psychiatry*, 24(5):801-10. [http://dx.doi.org/10.1016/S0278-5846\(00\)00107-X](http://dx.doi.org/10.1016/S0278-5846(00)00107-X)
- Youssef S.A., Capucchio M.T., Rofina J.E., Chambers J.K., Uchida K., Nakayama H., Head E. 2016. Pathology of the aging brain in domestic and laboratory animals, and animal models of human neurodegenerative diseases, *Veterinary Pathology*: 53(2)327-348, DOI: 10.1177/0300985815623997.
- Bancroft J.D., Cook H.C. 1984. *Manual of Histological Techniques*. Churchill Livingstone, New York, USA.

HISTOHEMIJSKE KARAKTERISTIKE I DISTRIBUCIJA LIPOFUSCINA I POLIGLUKOZANSKIH TELA U MOZGU PASA STARIJIH OD 10 GODINA

NEŠIĆ Sladjan, VUČIĆEVIĆ Ivana, MARINKOVIĆ Darko, KUKOLJ Vladimir, ANIČIĆ Milan, RISTOSKI Trpe, NIKOLIĆ Sonja, ALEKSIĆ KOVAČEVIĆ Sanja

Kratak sadržaj

Proces starenja prate brojne promene u mozgu pasa kao što su nagomilavanje amiloida, fibroza zida krvnih sudova i moždanih ovojnica, nakupljanje lipofuscina i prisustvo poliglukoznih tela (PGB), satelitoza i neuronofagija. U ovom radu ispitivano je prisustvo lipofuscina i PGB u različitim delovima centralnog nervnog sistema kod pasa različitog pola i starosti. Uzorci mozga obojeni su hematoksilin-eozinom, modifikovanom Ziehl-Neelsen metodom i perjodna kiselina-Schiff (PAS) metodom. Lipofuscin je modifikovanom Ziehl-Neelsen i PAS metodom specifično dokazan u istim segmentima moždanog tkiva. Dobijeni rezultati pokazuju da je lipofuscin akumuliran

uglavnom u neuronima produžene moždine kod 93% pasa. Zastupljenost pigmenta u ostalim segmentima mozga bio je niži u poređenju sa produženom moždinom. Korišćenjem obe metode bojenja, ustanovljena je mala razlika u procentu pozitivnih jedinki. Prisustvo PGB dokazano je PAS metodom kod velikog broja (oko 93%) pasa eksperimentalne grupe, dok u kontrolnoj grupi njihovo prisustvo nije ustanovljeno. U svim ispitivanim segmentima moždanog tkiva kod pasa iz eksperimentalne grupe, dokazana su PGB i to od 90% do 93%. Dobijeni rezultati ukazuju da su kod najstarijih pasa iz eksperimentalne grupe PGB bila lokalizovana i van ćelije i unutar nje, a kod drugih samo ekstracelularno.

Lipofuscin je akumuliran uglavnom u velikim neuronima olivarnih jedara produžene moždine. PGB su dokazana u svim ispitivanim segmentima moždanog tkiva pasa starijih od 10 godina. Ovo je jedan od brojnih dokaza da stari psi predstavljaju dobar animalni model za proučavanje normalnog procesa starenja ili neurodegenerativnih bolesti.

Ključne reči: pas, proces starenja, mozak, lipofuscin, poliglukozanska tela