

ROENTGENCRANIOMETRIC AND ROENTGENCEPHALOMETRIC DETERMINATION OF LINEAR PARAMETERS IN DOGS OF THE GERMAN SHEPHERD BREED

KRSTIĆ N*, MILOSAVLJEVIĆ Ž **and TEPAVČEVIĆ ZVEZDANA **

* Faculty of Veterinary Medicine, Belgrade, Yugoslavia; ** Orthodontic clinic, Faculty of Dental Medicine, Belgrade, Yugoslavia

(Received 23. December 2001)

After roentgenocraniometric and roentgencephalometric analysis of the most significant reference points for dogs of the German Shepherd breed aged 12 months, we considered it would be of importance, both from the scientific and cynologic point of view, to determine all linear parameters which might be used in the exact type classification of the neuroviscerocranium of these animals. Correct proportions of certain regions of the face and head were exactly determined by defining and numerically specifying the following lines; line N (Nasion)- S (Sella), bispalatine or palatine plane alpha (SnA- SnP), occlusal plane- beta, plane gamma (Go- Me) and line N-A. The line N-Iv denotes the middle height of the face which is specific for the mesocephalic type of dog's head. In addition to these, there are also the lines Co (Condylion) - Go (Gonion), Go (Gonion) - Me (Menton) and line S (Sella) - Go (Gonion). A full inspection of the harmony and anatomic balance in the proportions of the neuroviscerocranium skeleton was achieved by specifying the following linear parameters for the frontal photograph: the lines Zy- Zy (Zygion), Eu- Eu (between the Eurion points), the lines Em- Em, ecm- ecm, Eim- Eim, Go- Go, the distances En- En, Ein- Ein, Ecm- Ecm, Ecp- Ecp and Ecl- Ecl:

Key words: dog, radiocephalometry, radiocraniometry, radiology, teleroentgen.

INTRODUCTION

A large group of authors have tested the reactions of the alveolar bone, periodontal membrane and other associated structures of the orofacial system to different effects of forces, which may cause intrusions and changes in jaw shape (Broadbent, 1937, Moyers and Bawer, 1950, Macapanpan, 1954, Reitan, 1957 and Huettner and Witman, 1958, Cousin 1965). Their way of diagnosing these pathological disturbances was based on applying their knowledge of anthropology, histological technique and some roentgenological methods. Collected and analyzed results that had been obtained in this way could mostly give replies to the problem of disturbed development of the stomatognathous

system, but two important disadvantages of the then existing research technology had to be admitted as well. They related to both the inability to place correctly and always in the same manner the animal's head in a specified position during X-ray photographing and to the remarkable diversity in explanations of different morphometric points which were taken into account for estimation of either harmony or disharmony of the orrhofacial region. Localization and exact determination of these parameters differed from one author to another and this uncertainty lasted until a new method of roentgenography craniometry and cephalometry- was invented both by Broadbent (1931) in the United States and Hofrath (1931) in Europe. By constructing a special roentgen unit, cephalostat, they succeeded in always placing a patient's head in a specified position and this resulted in reproducible production of the same roentgenograms of the head, which neither showed blow-ups or distortions of the image, nor had unclear shade borders. However, even after its presentation in public, this method was not accepted significantly, which could be explained by its highly sophisticated technical characteristics and established habits as well. However, rapid development in human orthodontics contributed to its becoming irreplaceable in the diagnostics of different face and head malformations, selection of the therapy and observations of changes on the orrhofacial system during orthodontic correction. Numerous achievements that were made in research work should not be neglected neither.

Craniometry, i.e. cephalometry, denotes measurement of the linear and angular parameters on the bones of the cranium, i.e. on the head, with its all soft tissues. Anthropologic craniometry includes measuring the head skeleton without soft tissues and it is the oldest method that has established the foundation for further research work in this branch. Head bones were initially analyzed in a descriptive way and only later the exact determination of their numerical parameters was approached taking into account the existence of individual variations which made the basis for the entire osteometry. However, prepared head bones could only be observed and analyzed as unchangeable, excluding the possibility of alterations in the numerical values during growing up and lifetime. The shape and size of a dog's head skeleton, varies more than with any other animal. Therefore certain points and lines in the craniometry were introduced which could characterize a specific type of dog's head by creating desired angular and linear values. Using this method, dolicocephalic, mesocephalic and brachycephalic craniums can be classified.

After roentgenocraniometric and roentgencephalometric analyses of the most significant reference points for dogs of the German shepherd breed aged 12 months, (Krstić, 1997), we considered it would be extremely important, both from the scientific and cynological point of view, to define all linear parameters which resulted from the already mentioned points. They would be used as standard lines or planes important for the exact description and explanation of the correct and harmonious proportions of the face and cranium, i.e. for analysis of the craniofacial morphology. The term "line" denoted a straight line which connected two points and the term "plane" was used when at least three points were connected. These linear parameters were determined both for the bone elements and soft tissues of the viscerocranium and neurocranium on profile and frontal photographs.

By introducing different roentgenocraniometric and roentgencephalometric parameters in veterinarian small animal practices, we can contribute to the positive selection of dogs, because all relevant elements which define correct proportions of the skeletal structures of the head and teeth in relation to other osseous elements will be included.

MATERIALS AND METHODS

Animals and Procedures

Since clinical experience and every day practice indicated that malocclusions are most frequently found in highly selected dog breeds, as an experimental model we used 15 dogs of the German shepherd breed taken from a homogenous group, at 12 months old. They were the same sex and 24 to 30 kilograms in body weight.

All photographing was made on animals in general anesthesia.

Teleradiography was used for obtaining isometric roentgenograms as the best method. This procedure can provide the most reliable particulars of the actual sizes of some structures and especially of some head and jaw parameters. X-rays for photographing the neuroviscerocranium of the German shepherd dogs were as follows: 65kV, 25 mA and Ffo= 1,5m. In order to prevent lateral inclination of the head, the animals were placed in the costoabdominal position and only the position of the central X-ray was changed depending whether profile or frontal photographs were required. Care was taken that the median of the dog's body always coincided with the mean white line on the photographic table. After technological film processing those bones and skin contours that were necessary for the correct and valid roentgenocraniometric and roentgencephalometric analysis were drawn on the acetate paper which had been fixed to the photograph.

RESULTS

Linear Radiocraniometric and Radiocephalometric Parameters in the Profile Projection

The point N (Nasion) and the point S (Sella) denoted the direction of the N-S line which was used in our analyses both as a reference line and a deep penetration line. We introduced it as a basic line or plane of the front cranium pit, i.e. of the part of the cranium base (Fig.2).

The bispinal or palatine plane - alpha (the basic plane of the upper jaw) was specified in our drawings by connecting the points SnA and SnP, denoting a border between the jaw part or dentoalveolar system and other face or head elements. Since we had difficulties in determining the SnP point in some photographs because of deep penetration of different bone shades, we determined the SnA-SnP line structurally and by determining the tangent line at the top of the convex shade of the hard palate. The values of the SnA-SnP line were 82-112 mm (Fig.2).

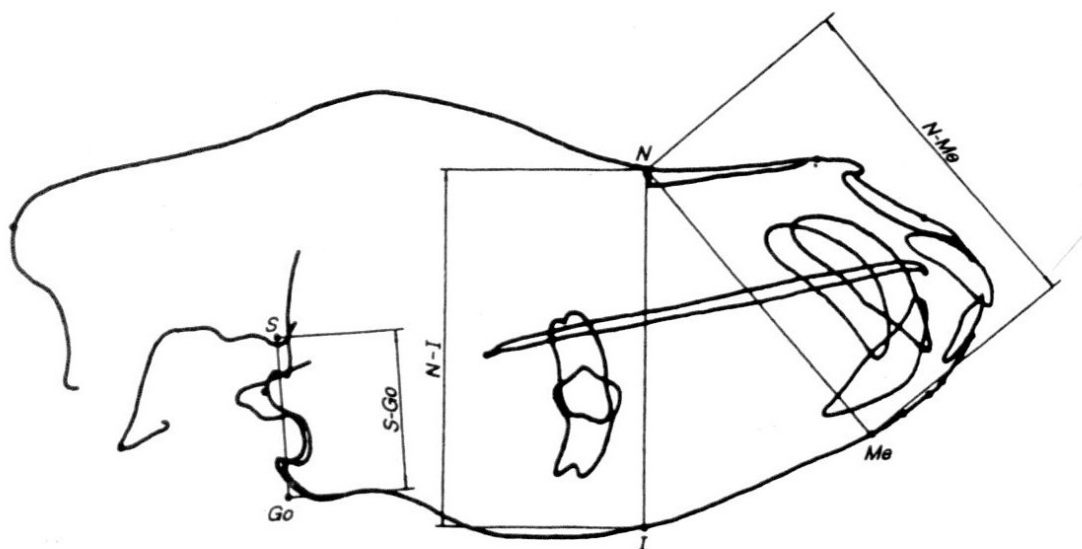


Fig 1. Profile radiocraniometric lines

To define the rear height of the face, a line was determined that connected the points S-Go, the length of which ranged from 37 mm to 44 mm (41 mm). The mean height of the face denoted by the N and I points had values from 80 to 88 mm (84 mm). The front height of the face between the N and Me points ranged from 81 mm to 88 mm with the mean value of 84 mm (tab. 1, 2). In order to study the course of growth and the changes in face harmony and cranium base, we defined a ratio between the rear and front face heights on the basis of the following formula

$$\frac{S-Go \times 100}{N-Me}$$

The mean value expressed as a percentage was 45% (Tables 1 and 2) (Fig.1).

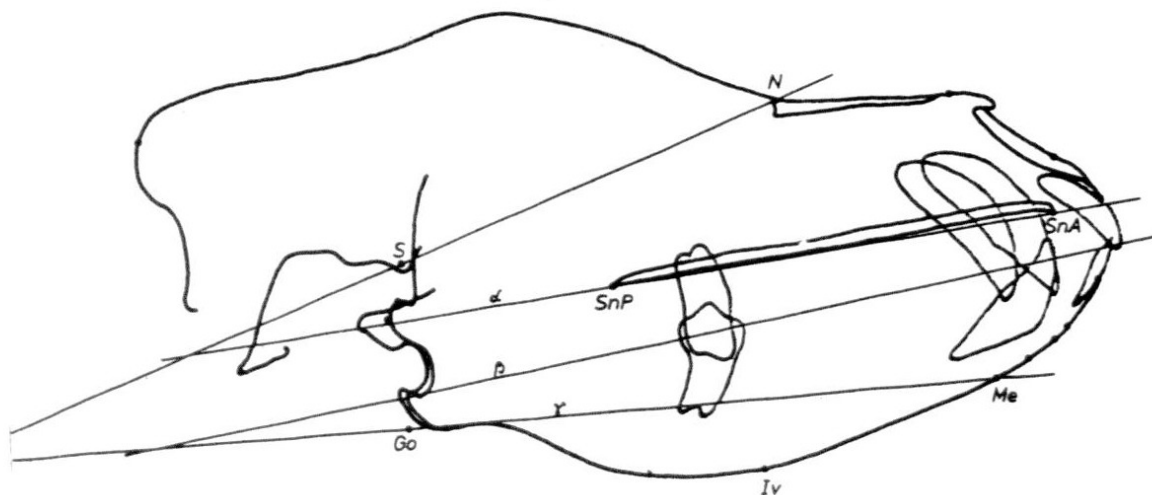


Fig 2. Some radiocraniometric lines in profile projection (a)

Table 1: Individual numerical values for length of certain lines in the profile roentgencraniometry

Dog No	1	2	3	4	5	6	7	8	9	10	11	12	13	14	15
Line Marks	Values in millimeters (mm)														
Snp-SnA	110	106	82	104	90	100	95	99	100	110	103	105	95	112	105
Go-Me	165	145	126	155	132	147	140	146	150	160	151	149	130	163	149
Co-Go	30	26	36	48	37	38	40	30	34	35	33	35	31	45	36
S-Go	3,7	3,8	4,3	4,3	3,9	4,1	4,1	4,2	4,3	4,3	3,7	4,4	3,8	4,3	4,1
N-Me	8,8	8,3	8,3	8,6	8,6	8,2	8,1	8,2	8,6	8,6	8,6	8,3	8,3	8,2	8,6
N-lv	8,8	8,4	8,2	8,5	8,5	8,1	8,1	8,0	8,6	8,6	8,5	8,2	8,2	8,2	8,6

Table 2: Statistical interpretation of the results for the line values (Table 1.) in the roentgencraniometry LL-projection)

Line Marks	Variable parameters						
	X	SD	SE	CV (%)	RV	Min-Max	Med
Snp-SnA	101,1	8,0	2,1	7,9	30,0	82-112	103,0
Go-Me	147,2	11,5	2,9	7,8	39,0	126-165	149,0
Co-Go	35,6	5,7	1,5	16,0	22,0	25-48	35,0
S-Go	40,85	2,44	0,63	6,0	7,0	37-44	41,0
N-Me	84,20	2,14	0,55	2,5	7,0	81-88	83,0
N-lv	83,73	2,34	0,60	2,8	8,0	80-88	84,0

The occlusive plane - beta - This line was drawn only when the teeth had been already in complete occlusion. Its position was such that it divided in half the bone shades of overlaps of incisors and crowns of the upper and lower jaws as well as last premolars and molars. (Fig. 2).

On the basis of the already mentioned roentgenocraniometric points in this study, placed on the mandible, we determined the *gama plane*- the basic plane of the lower jaw. We compared two ways of constructing this plane. One was by connecting the Gnathion points with two Gonion points while the other was when by drawing the plane between the Menton point and, again, the even Gonion points. Both these lines cut the bone shade of the mandible because of the prominent convex feature of the ventral edge of its body that (due to its anatomical shape) prevented us from drawing the tangent line along its entire length. Its values ranged from 126 to 165 mm (Tables 1 and 2) (Fig. 2).

It was also necessary to indicate two more lines that were used for determination of the prognathous position of either upper or lower jaw. The first line was obtained by joining the points N (Nasion) and A, similarly to the line joining the N (Nasion) points and the Iv point.

When we had drawn a line through the light part of the incisors and eyetooth root canals that connected the tooth root top with its crown, we obtained an axis of the upper and lower incisors and eyeteeth (Fig. 3).

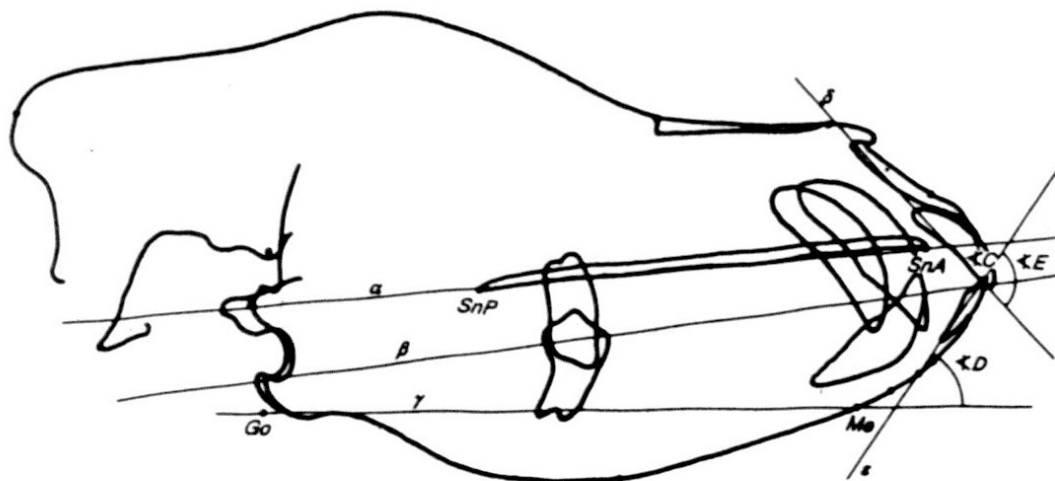


Fig 3. Some radiocraniometric lines in profile projection (b)

The line that joined the Co (Condilion) and Go (Gonion) points determined the length of the mandible branch. Its values were 36- 48 mm (tab. 1) (Fig. 4).

To show linear measures of the entire length of head of the German shepherd dogs, we directly measured the distance from the skin point Jn', which was located in the most prognathous part of the occipital bone and skin point Dorsum D'. Indirectly, using the already mentioned points, the length of the entire viscerocranium Jn' D' (207- 230 mm) was determined by adding the distance between the Jn' and N' points (147-165 mm) to the distance between the Nasion' and Dorsum' points- N'-D' (58-68 mm) (Tab. 3 & 4) (Fig. 5).

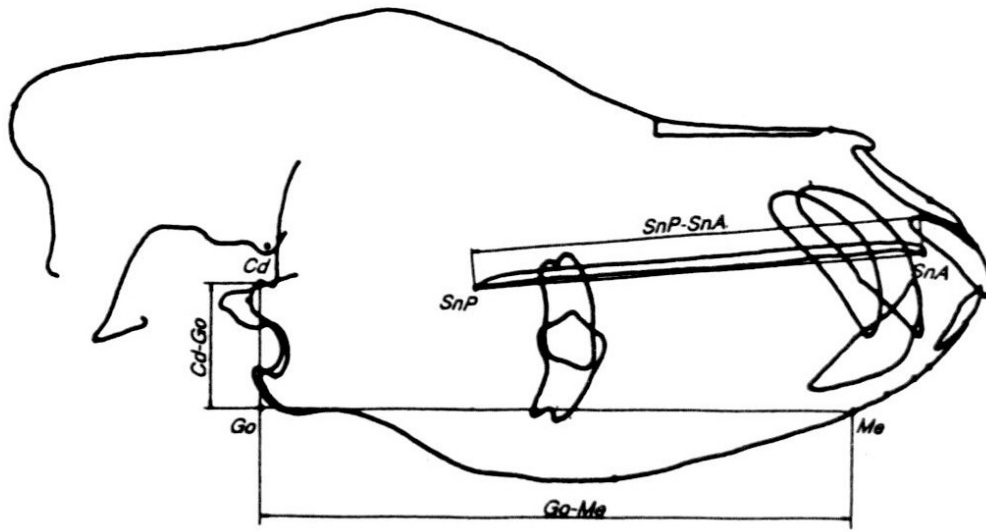


Fig 4. Some radiocraniometric lines in profile projection (c)

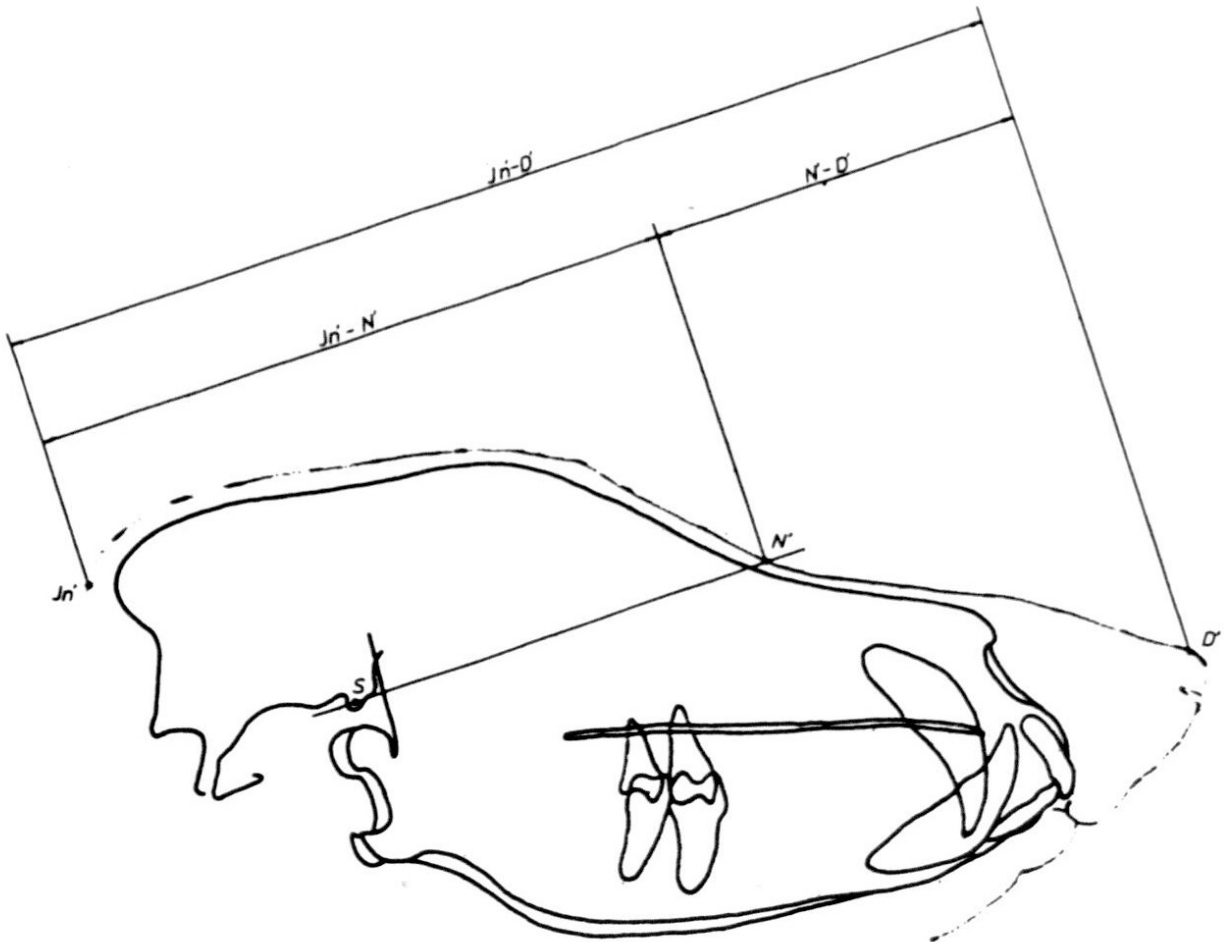


Fig 5. Some radiocraniometric lines in profile projection (d)

Table 3: Individual numerical values for lengths of certain lines in the roentgencephalometry

Dog No	1	2	3	4	5	6	7	8	9	10	11	12	13	14	15
Line Marks	Values in millimeters (mm)														
Jh-n-	148	148	150	160	147	149	150	155	156	148	153	155	149	165	159
N-D-	61	63	60	63	62	61	64	65	64	62	66	65	58	65	68
Jh-D-	209	211	210	233	223	210	214	220	220	210	219	270	207	230	227

Tab. 4: Statistical interpretation of the results for the line values (Table 3.) in the roentgencephalometry (LL-projection)

Line Marks	Variable parameters						
	x	SD	SE	CV (%)	RV	Min-Max	Med
Jh-N	158,2	5,4	1,4	3,5	18,0	147-165	150,0
N-D-	63,1	2,5	0,6	4,0	10,0	58-68	63,0
Jh-D-	215,9	7,2	1,8	3,3	23,0	207-230	214,0

The line that joins the skin points N' and D' with the tangent line of the upper and lower lips (t) was important for construction of the angle of the nose mushroom.

Linear radiocraniometric measurements in DV projection

On DV, i.e. on the frontal photograph of the head, between the even points, we determined those lines which would provide the most complete presentation of the harmony and anatomic balance of skeletal proportions of the neuroviscerocranium (Tab. 5 & 6) (Fig. 6).

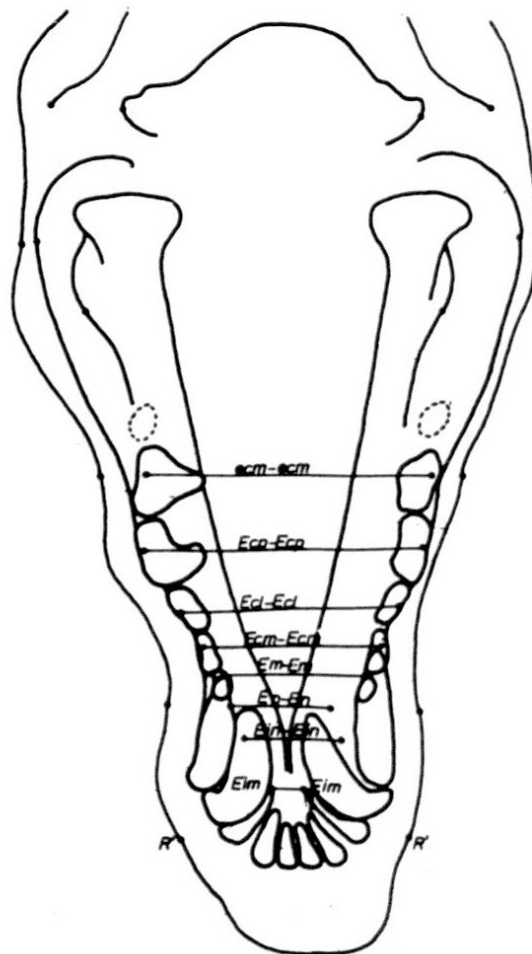


Fig 6. Radiocraniometric lines in saggital projection

A line between the even points Zygon (Zy-Zy) defined the upper width of the face. Its mean value amounted to 119 mm (112-124 mm).

The largest cranium width (72-83 mm) (\bar{x} = 79 mm) occurred between the Eurion points (Eu-Eu) in the most lateral part of the parietal bones.

The Em-Em line denoted the least width of the upper jaw body (31-39 mm) (\bar{x} = 34 mm) (Fig. 6).

The greatest width of the upper jaw body (ecm-ecm) was measured between the means of the first permanent molars of the maxilla at the most lateral points of the vestibular area of the alveolar extensions (55-63 mm) (\bar{x} = 60 mm).

Table 5: Individual numerical values for lengths of certain lines in roentgenocraniometry (DV-projections)

Dog No	1	2	3	4	5	6	7	8	9	10	11	12	13	14	15
Line Marks															
Zy-Zy	12	118	112	119	121	116	116	120	124	123	121	118	119	116	121
Eu-Eu	0														
Em-Em	80	75	72	74	8	79	8	81	83	78	77	8	81	73	77
ecm-ecm	36	32	31	34	37	36	38	39	37	32	31	33	35	34	34
Eim-Eim	63	60	59	62	63	62	61	63	60	57	55	58	59	61	60
En-En	31	33	31	30	33	32	30	35	29	26	25	30	32	34	33
Ein-Ein	22	23	21	22	25	25	19	19	18	25	27	28	29	23	22
Ecm-Ecm	20	23	22	20	24	24	17	16	16	25	24	26	27	21	20
Ecp-Ecp	58	59	57	53	55	54	50	49	50	59	58	60	59	55	56
Ecl-Ecl	68	69	66	63	64	63	62	60	61	69	67	70	69	66	67
Go-Go	52	54	53	50	51	49	48	47	49	54	53	55	55	53	52
	83	82	80	78	81	82	83	85	83	84	80	79	82	81	80

Table 6: Statistical interpretation of results for the line values (Table 5.) in the roentgencephalometry (DV-projections)

Line Marks	Variable parameters										
	x	SD	SE	CV(%)	RV	Min-Max	Med				
Zy-Zy	118,93	3,08	0,79	2,6	12,0	112-124	119,0				
Eu-Eu	78,00	3,25	0,83	4,2	11,0	72-83	79,0				
Em-Em	34,60	2,52	0,65	7,3	8,0	31-39	34,0				
ecm-ecm	60,20	2,33	0,60	3,9	8,0	55-63	60,0				
Eim-Eim	30,93	2,76	0,71	8,9	10,0	25-35	31,0				
En-En	23,20	3,29	0,85	14,2	11,0	18-29	23,0				
Ein-Ein	21,66	3,49	0,90	16,1	11,0	16-27	22,0				
Ecm-Ecm	55,46	3,62	0,93	6,5	11,0	49-60	56,0				
Ecp-Ecp	65,60	3,22	0,83	4,9	10,0	60-70	66,0				
Ecl-Ecl	51,66	2,55	0,65	4,9	8,0	47-55	52,0				
Go-Go	81,53	1,92	0,49	2,3	7,0	78-85	82,0				

Tab. 7: Individual numerical values for lengths of certain lines in the roentgencephalometry (DV-projection)

Dog No	1	2	3	4	5	6	7	8	9	10	11	12	13	14	15
Eu-Eu	125	127	123	130	122	124	128	120	130	131	129	132	133	130	129
ZyZy	148	150	147	155	151	153	157	150	160	161	158	159	160	150	148
ecm-ecm	120	122	121	125	123	125	124	120	130	130	129	129	131	125	124
en-en	71	73	72	75	72	71	75	74	77	78	76	77	76	74	72
R-R	65	67	63	66	60	61	67	67	69	68	67	66	66	65	64

Table 8: Statistical interpretation of results for line values (Table 7) in the roentgencephalometry (DV-projections)

Line Marks	Variable parameters						
	x	SD	SE	CV(%)	RV	Min-Max	Med
Eu-Eu	127,53	3,88	1,00	3,0	13,0	120-133	129,0
Zy-Zy	153,80	5,00	1,29	3,2	14,0	147-161	153,0
ecm-ecm	125,53	3,87	0,99	3,1	11,0	120-131	125,0
en-en	74,20	2,30	0,59	3,1	7,0	71-78	74,0
R-R	65,40	2,50	0,64	3,8	9,0	60-69	66,0

The Eim-Eim line- denoted the greatest width of the dental arc of the maxilla incisive bone (25-35 mm) (\bar{x} =31 mm).

The angular distance (Go-Go) provided us with the mandible ramus width of the left and right side (78-85 mm) (\bar{x} =82 mm).

The En-En line denoted the least width of the lower jaw body (18-29 mm) (\bar{x} =23 mm) in the arc of the alveolar extensions of the first premolars.

The Ein-Ein line- denoted the greatest width of the dental arc of the mandible incisive bone (16-27 mm) (\bar{x} =22 mm) (Fig. 6).

The Ecm-Ecm line denoted the distance between alveolar extensions of the second premolars. Its range was 49-60 mm, with the mean value of 56 mm.

The Ecp-Ecp line defined the biggest distance between the maxilla teeth and it was situated between alveolar extensions of the fourth premolars of the left and right side. Values of this parameter were 60-70 mm and mean value was 66 mm.

The line between the even points Ecl-Ecl denoted the distance between the alveolar extensions of the third maxilla premolars. The range was 47-55 mm and the mean value was 51,5 mm (Fig. 6).

Linear Radiocephalometric Parameters in DV projections

The measured values of linear cephalometric parameters of the positions which corresponded to their anatomic-osseous entities, were as follows: the Eu'-Eu' distance was 129 mm, with a 120-130 mm range. The Zy'-Zy' line had the mean value of 153 mm (147-161 mm). The line that joined the ecm'-ecm' points denoted the greatest (skin) width of soft tissues on the upper jaw body and its mean value was 125 mm (120-131 mm). The shortest "skin" distance in the area of the lower jaw was between the en'-en' points (71-78) (\bar{x} =74 mm). The widest part of the nose mushroom was denoted by the R'-R' line the mean value of which was 66 mm (60-69 mm) (Tables 7 and 8)

DISCUSSION

In the profile photograph of the dog's head, all bilateral, even points came down to the median plane which means that, in roentgenocraniometric and roentgencephalometric research, i.e. in our drawings both the lines and planes were represented by lines only. This is analogous with human medicine (Korkhaus, 1930,1936; Rakosi, 1979, 1982; Ness. et al., 1975).

The line, i.e. plane, of the front cranium pit extended from the Sella point (S) to the Nasion point (N). The S point almost did not move during development of the cranium, while the N point, which was located in the exocranial area of the nasal bone, changed its position in a horizontal direction depending on the size of the front sinuses and the stage of development but much less on endocranial parameters. Therefore, its mobile position put in question the determination of the longitudinal parameter of the NS line, although, even in such a mode, it has been used in human jaw orthopedics for various analyses (Koski, 1964; Ballard, Bond, 1960).

The bispinal or palatin plane (alpha-the basic plane of the upper jaw in humans) changed depending on whether the bone shade of the hard palate was either horizontal or concave or convex (Krogman, 1957, 1973).

To determine the stage of angularity of the upper and lower incisors, a line was used which joined the top of the tooth root with its crown (teta or eta), (Lusterman, 1963; Ross, 1968; Kyle, 1988).

If the length of the line SnA-SnP ($x = 101,1$ mm) was increased, a pathological change occurred- maxilla prognathism. Reducing the value resulted in maxilla retrognathism.

If the occlusive plane (beta) descended ventrally it affected the relation of the lower jaw towards the upper jaw by steepening its position. Lowering the gamma plane between the Go and Me points also led to a steep position of the lower jaw base.

The protrusion level of the upper jaw depended on the position of the NA line in relation to the occlusive plane. If the points A approached the beta plane the protrusion became more expressed.

Three lines; S-Go, N-Iv and N-Me, denoted the rear, middle and front heights of the facial part of the head. The values measured on 15 dogs could be very important data for establishing standards for the visceral (facial) part of the head of the German shepherd dog (Krstić, 1997).

Data on head form and a cranium shape are required, first of all, because there is interdependence between them and the numerical values which could characterise a certain dog breed. In addition to measures obtained from the profile photographs, it must be taken into account that photographs made in the (DV) frontal projection. Both projections are required for determination of dimensions of the teeth arcs which correspond to the craniometric parameters of the viscerocranium. A wider cranial part of the head matches a wider jaw and thus the teeth as well, a narrower one- the opposite (Bodmer, 1976; Dixon and Stewart, 1976).

Data on cranium shape, obtained by DV projection, were created by introduction of the even point Eurion (Eu), the most lateral and prominent part of the parietal or temporal bone in relation to the individual characteristics of the widest neurocranial part.

The width of the visceral part of the head was defined by the line between the even points Zygon (Zy), which were located on the most lateral part of the zygomatic arcs.

In the mesocephalic type of dog's head (German shepherd) the width of the visceral part (120 mm) was in a 3:2 ratio to the cranial part (Eu-Eu was 79 mm). A line that connected the even points ecm-ecm-, i.e. the widest part of the upper jaw (60 mm), had half the value of the upper face width (Zy-Zy is 120 mm). As the upper jaw was orally narrowed up to the bilateral points (Em), the measured line (Em-Em) had the value of 34 mm.

The greatest width of the dental arc (Eim-Eim) of the incisive bone of the upper jaw amounted approximately to 31 mm, which is of importance for the correct arrangement and interrelations of the incisors.

The lower facial width was represented by the length of the Go-Go line (82 mm) which was one third shorter than the upper facial width (Zy-Zy- 120 mm). Comparing the value of the widest part of the upper jaw body (ecm-ecm- 60 mm) with the value of the width between the second premolars (Ecm-Ecm-56mm) it can be stated that they are almost identical.

The results of measuring the greatest width of the dental arc of the incisive bone of the maxilla Eim-Eim (31 mm) and mandible Ein-Ein (22 mm) showed a normal interrelation of the upper wider and lower narrower parts of these bones, which also conditions a regular bite (scissors- like teeth).

CONCLUSIONS

1. Regular proportions of certain regions of the face and head were exactly determined by defining and numerically specifying the following lines: the N(Nasion)-S (Sella) line, the bispinal or palatine plane alpha SnA-SnP (82-112 mm), the occlusive plane-beta, the gamma plane Go-Me (126-165 mm) and the N-A line, while the N-lv line (80-88 mm) denotes the mean facial height specific for the mesocephalic type of dog's head. In addition to these, there are also the following lines: Condylon-Gonion, Co-Go (26-48 mm), Gonion-Menton, Go-Me (126-165 mm) and Sella-Gonion, S-Go (37-44 mm).

2. The distance from the skin point In' to the skin point D' (207-230 mm) was used to show linear dimensions of the entire head length of dogs of the German shepherd breed in the profile projection. Indirectly, this distance can be found out by adding the value of the In'N' line (147-165 mm) to the value of N'D' line (58-68 mm).

3. A full inspection of the harmony and anatomic balance of skeletal proportions of the neuroviscerocranium was achieved by determination of the following linear parameters in the frontal photograph: the line Zy-Zy (Zygon) (112-124 mm), Eu-Eu (between the Eurion points) (72-83 mm), the line Em-Em (31-39 mm), ecm-ecm (55-63 mm), Eim-Eim (25-35 mm), Co-Go (78-85 mm), the distance En-En (18-29 mm), Ein-Ein (16-27 mm), Ecm-Ecm (49-60 mm), Ecp-Ecp (60-70 mm) and Ecl-Ecl (47-55 mm).

4. The linear radiocephalometric parameters in the DV- frontal projection, which determine the richness of the skin cover and the thickness of the subcutaneous tissues and muscles, were as follows: Eu'-Eu' (120-133 mm), Zy'-Zy' (147-161 mm), ecm'-ecm' (120-131 mm), en'-en' (71-78 mm) and R'-R' (60-69 mm).

Address for correspondence:
Dr Nikola Krstić
Department of radiology
Faculty of Veterinary Medicine,
Bul. JNA 18, Belgrade, Yugoslavia

REFERENCES

1. Ballard CF, Bond EK, 1960. Clinical observations on the correlation between variations of orofacial behaviour, including those for articulation, *Speech path therap*, 55-63.
2. Bodmer WF, Cavalli-Sforza LL, 1976. Genetics, Evolution and Man, W.H. Freeman and Co., San Francisco.
3. Broadbent BH, 1937. Bolton standards and technique in orthodontic practice, *Angle Orth*, 7: 209-33.
4. Broadbent HB, 1931. A new X-ray technique and its application to orthodontia, *Angle orth*, 1, 45-6.
5. Cousin MRP, 1965. A propos de la valeur de certains points utilises en cephalometrie teleradiographique, *Orthod. franc*, 36, 167-81

6. Dixon GH, Stewart RE, 1976, Genetic Aspects of anomalous tooth development, VRE Stewart and GH Prescott, Oral Facial Genetics, C.V. Mosby Co., St. Louis,
7. Hofrath H, 1931, Die Bedeutung des Röntgenfern und Abstandsaufnahme für die Diagnostik der Kieferanomalien, *Fortschr Der Kieferorth*, Bd. 2, 232-58.
8. Huettner RJ, Withman CL, 1958, Tissue changes in the macaque Rhesus monkey during orthodontic movement, *Am J Orthodontics*, 44: 328-45.
9. Korkhaus G, Antropological and odontologic studies of twins, *Int J Orthodonts*, 16, 1930.
10. Korkhaus G, 1936, Die Auswertung des Fernröntgenbilds in der Kieferorthopädie, *Deutsche Zahne-Mund u. Kieferheilk.*, Bd. 3, 715-29.
11. Korkhaus G, 1936, L'utilisation des teleradiographies dans le diagnostic des malformations dento-faciales, *Ortho Franc*, 131-52.
12. Koski K, 1964, The Finish female face in norma lateralis, *Trans EOS*, 463-469.
13. Krogman WM, 1973, Forty years of growth research and orthodontics, *AJO*, 63, 4, 357-60.
14. Krogman WM, Sassouni V, 1957, Syllabus in Roentgenographic Cephalometry, Philadelphia,
15. Krstić N, 1997, Rendgenkranometrijska i rendgenkefalometrijska ispitivanja pasa rase nemački ovčar, Doktorska disertacija, Fakultet veterinarske medicine, Univerzitet u Beogradu.
16. Kyle MA, 1988, Canine Periodontal Disease, *J Vet Dent*, 5, 10-11.
17. Lusterman EA, 1963, The esthetics of the occidental face: A study of dentofacial morphology based upon anthropological criteria, *A J O*, 49, 11, 826-50.
18. Macapanpan LC, Weinmann JP, Brodie AG, 1954, Early Tissue Changes Following Tooth Movement in Rats, *Angle Orthodontist*, 24:79.
19. Moyers RE, Bauer JL, 1950, The Periodontal Response to Various Tooth Movements, *Am J Orthodontics*, 36:572,
20. Ness AL, Merrill OM, Hansel JR, 1975, Cephalometric roentgenography for nonhuman primates utilizing a surgically implanted head positioner, *Am J Phys Anthropol*, 43:141-7.
21. Rakosi Th, 1982, An Atlas and Manual of Cephalometric Radiography, Wolfe Medical Publications Ltd.
22. Rakosi Th, 1979, Atlas und Anteilung zur Practischen Fernröntgenanalyse, Carl Hanser Verlag, München,
23. Reitan K, 1957, Some Factors Determining the Evaluation of Forces in Orthodontics, *Am J Orthodontics*, 43:32.
24. Ross DL, 1986, Orthodontics for the dog. Treatment methods, *Vet Cli. North A. Small Ani. Prac*, 16, 939-54,

RENDGENKRANIOMETRIJSKO I RENDGENKEFALOMETRIJSKO ISPITIVANJE LINEARNIH PARAMETARA PASA RASE NEMAČKI OVČAR

KRSTIĆ N, MILOSAVLJEVIĆ Ž I TEPAVČEVIĆ ZVEZDANA

SADRŽAJ

Rendgenkranometrijskom i rendgenkefalometrijskom analizom najznačajnijih referentnih tačaka kod pasa rase nemački ovčar starosti 12 meseci, određivani su linearni parametri koji bi se mogli koristiti u egzaktnoj tipizaciji neuroviscerokranijuma ovih životinja.

Pravilni odnosi pojedinih regija lica i glave egzaktno su utvrđeni definisanjem i numeričkim određivanjem sledećih linija: linija N (Nasion)- S (Sella), bispinalna ili palatinalna ravan alfa (SnA- SnP), okluzana ravan- beta, ravan gama (Go- Me) i linija N-A. Linija N-lv predstavlja srednju visinu lica osobenu za mezocefalni tip glave psa. Pored ovih postoje još i linije Co (Condylion)- Go (Gonion)- Me (Menton) i linija S (Sella)- Go (Gonion). Potpuni uvid u skladnost i

anatomsku ravnotežu skeletnog odnosa neuroviscerokranijuma dobijen je određivanjem sledećih linearnih parametara na frontalnom snimku: linija Zy-Zy (*Zygion*), Eu-Eu (između tačaka *Eurion*), linija Em-Em, ecm-ecm, Eim-Eim, Go-Go, rastojanje En-En, Ein-Ein, Ecm-Ecm, Ecp-Ecp i Ecl-Ecl.