

PNEUMONIA IN CATS ASSOCIATED WITH *Neisseria* sp.

Herica MAKINO¹, Alessandra Tammy HAYAKAWA ITO DE SOUSA¹, Lucas Avelino DANDOLINI PAVELEGINI¹, Yolanda Paim ARRUDA TREVISAN², Edson MOLETA COLODEL², Valéria Régia FRANCO SOUSA², Valéria DUTRA², Luciano NAKAZATO^{2*}

¹Graduate Program in Veterinary Sciences, Federal University of Mato Grosso (UFMT), Cuiaba, MT, Brazil; ²Faculty of Veterinary Medicine (FAVET), UFMT, Cuiaba, MT, Brazil.

(Received 14 February, Accepted 24 May 2021)

Neisseria sp. is a Gram-negative diplococcus bacterium usually present on the mucosal surfaces of animals without causing an obvious pathology. The objective of this study was to report the isolation of *Neisseria* sp. from severe cases of pyogranulomatous pneumonia with the formation of a Splendore-Hoeppli structure in two cats treated at a veterinary hospital. This paper suggests that the *Neisseria* genus members may be involved in lower respiratory tract infections in cats, with the molecular diagnosis being a necessary method for the correct identification of this bacteria in animals.

Key words: *Neisseria* sp., pneumonia, feline, molecular diagnosis

INTRODUCTION

The *Neisseria* genus is comprised of 32 species of gram-negative diplococci bacteria that are usually present on the mucous surfaces of humans and animals [1]. *Neisseria gonorrhoeae*, which causes gonorrhoea [2], and *N. meningitidis*, which causes sepsis and meningitis [3], are the most prominent pathogenic species in humans.

In addition to these pathogens, it is recognized that this genus includes a wide variety of species such as *Neisseria weaver*, *Neisseria dumasiana*, *Neisseria zoodegmatidis*, *Neisseria shayegani* and *Neisseria canis* [4]. Some of them can induce disease [5], but most are identified as commensals in the oral cavity and respiratory tract of humans and animals [4,6].

Few studies have been dedicated to the detection and characterization of *Neisseria* sp. in animals. More recent studies have reported the isolation of this bacteria in a case

*Corresponding author: e-mail: lucnaka@gmail.com

of deep dermatitis in a dog and of a nasofacial infection in a cat, and in the brains of geese and porpoises [7-10].

The objective of this study was to report the isolation of *Neisseria* sp. in severe cases of pneumonia in two cats treated at Hospital Veterinário, Brazil.

CASE PRESENTATION

Case 1. A cat, male, mixed breed, one-year-old, with a complaint of anorexia and dyspnea for approximately three days, was presented to a veterinary hospital. Chest radiography showed radiopacity with an interstitial and alveolar appearance in the lungs. The patient died on the same day.

Lung fragments were collected and sent to the microbiology laboratory where they were sown on 8% sheep blood agar (Sigma - Aldrich, Darmstadt, Germany), MacConkey agar (Neogen Corporation, São Paulo, Brazil), and Sabouraud Dextrose agar with and without chloramphenicol in aerobiosis, incubated at 37 °C, 30 °C, and 25 °C for up to 14 days for microbial and fungal isolation. Colonies were identified according to a procedure described by Quinn et al. [11] by Gram stain, catalase, oxidase tests, and biochemical methods (Triple Sugar Iron- TSI, Indole Sulfide Motility- YES, OF-GOF Test, Citrate) (Sigma-Aldrich, Darmstadt, Alemanha).

After isolation, each sample colony was inoculated into brain and heart infusion broth (Himedia Labs. Mumbai, India), incubated at 37 °C overnight, and genomic DNA was extracted using the phenol / chloroform method [12].

The extracted DNAs were subjected to polymerase chain reaction (PCR) for the 16S rRNA gene. The sequence of used primers were 27F: AGAGTTTGATCCTGGCTCAG [13] and 1492R: GGTTACCTTGTTACGACTT [14]. Each reaction was composed of 10 ng of DNA (0.5 µl), 0.4 pmol of each oligonucleotide, 0.2 mM of deoxynucleoside triphosphates (dNTPs, Sigma-Aldrich, Germany) (5µl), 3 mM of MgCl₂ (1.5µl), 1x PCR buffer (2.5 µl), 1 U of Taq DNA polymerase (Invitrogen by Thermo Fisher Scientific, Carlsbad, Califórnia, EUA) (0.2µl), and ultrapure water q.s.p. (14.8µl) for a final volume of 25 µL. The PCR products were fractionated on a 1.0% agarose gel, stained with Gel Red™ (Biotium®, UK) at 10 V/cm and visualized on a photo-documenter.

Subsequently, the product obtained by PCR (Figure 1) was purified and sequenced using the ABI 3500 Genetic Analyzer (Applied Biosystems Foster, CA, USA). The sequence was analyzed by DECIPHER and compared to the GenBank database using BLAST (www.ncbi.nlm.nih.gov/BLAST) with access number MW354907. The sequence was similar to that of *Neisseria* sp. 97.35% (GenBank KC675471.1) and *N. subflava* 96.34% (GenBank LT689485.1). Phylogenetic analysis was performed on the Phylogeny.fr platform using the MUSCLE program (v3.8.31). After alignment, the ambiguous regions were removed with Gblocks (v0.91b) and the phylogenetic tree for the isolate was inferred by the maximum likelihood method (Figure 2).

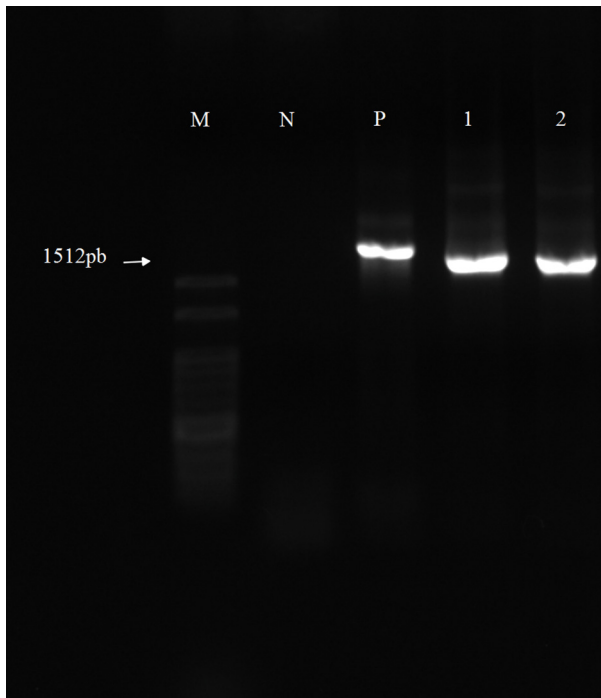


Figure 1. Agarose gel (1.5%) electrophoresis of Polymerase chain reaction (PCR) for the 16S rRNA gene of bacteria isolates from lung of cats. Lane M: molecular marker; N: negative control; P: positive control (*E. coli* DNA); 1: DNA from bacterial isolate from case 1; 2: DNA from bacterial isolate from case 2.




Figure 2. Maximum likelihood phylogenetic tree based on 16S rRNA sequence of *Neisseria* sp. (GenBank MW354907) isolate from cat lung (case 1). *Moraxella canis* was used as an outgroup

Case 2. A cat, female, mixed breed, five years old, had a complaint of anorexia, dyspnea, and diarrhea for two days. On physical evaluation, mild jaundice, pulmonary crepitation, and moderate dehydration were observed, and replacement fluid therapy

was instituted. Abdominal ultrasonography revealed hepatomegaly with homogeneous and hypoechoic parenchyma, septate gallbladder with repletion of anechoic content, and cellularity presence. Radiographic examination of the chest showed pulmonary fields with marked alveolar radiopacity.

The patient died on the same day, and a diffuse dark red lung was observed at necropsy, with raised irregular and multifocal areas in the lung parenchyma (Figure 3). Microscopically, a lung with marked changes in the parenchyma was observed, characterized by the respiratory tissue's replacement by a marked inflammatory pyogranulomatous reaction. These were characterized by an aggregate of bacteria surrounded by degenerate polymorphonuclear cells with the Splendore-Hoeppli structure formation (Figure 3). Macrophages with a distended cytoplasm containing bacteria, similar to those that are aggregated outside the cell structure were observed. In almost all respiratory structures, the alveoli were distended, containing hyaline material, mononuclear cells, light infiltrates of neutrophils, and bacterial colonies.

A macroscopic diffuse lobular pattern and a microscopic mononuclear, periportal and chronic infiltrate with moderate fibrosis, along with proliferation of bile ducts,

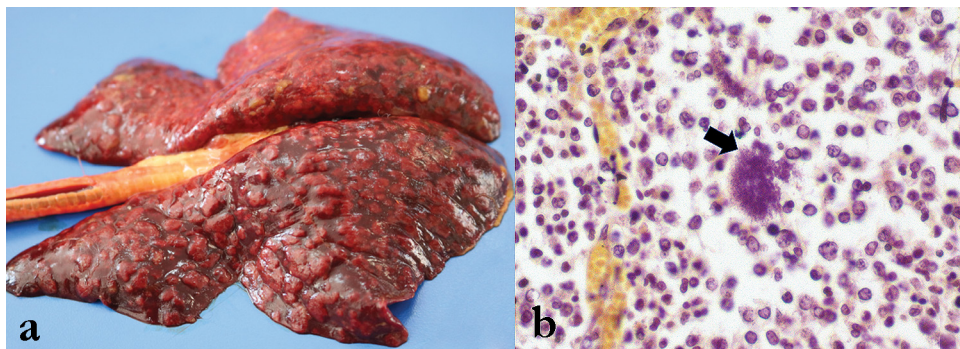


Figure 3. *Neisseria pneumonia*, cat, male/female, five years-old. **A-** multiple nodules scattered throughout parenchyma. **B-** Lung nodule with Infiltration of neutrophils and macrophages with presence of Splendore-Hoeppli (arrow), Gram stain, 600X




Figure 4. Maximum likelihood phylogenetic tree based on 16S rRNA sequence of *Neisseria* sp. (GenBank MW349688) isolate from cat lung (case 2). *Moraxella canis* was used as an outgroup

were observed in the liver. In the bile ducts, morphological structures compatible with *Platynosomum* sp. and microabscesses were occasionally observed. There was microvascular hepatocellular degeneration, especially in the centrilobular region, and random individual coagulative necrosis of hepatocytes.

Microbiological analysis and molecular characterization of the isolate were similar to those described in the first case (GenBank access number MW349688). The product generated by PCR showed a similarity of 99.22% with *N. animaloris* (MH166779.1) and 98.56% with *N. canis* (AY426974.1). Phylogenetic analysis is shown in Figure 3.

DISCUSSION

Species of the *Neisseriaceae* family remain part of the commensal microbiota of humans' and animals' upper respiratory tracts, usually without causing evident pathology [1,15]. In this study, we reported the isolation of *Neisseria* sp. in two cats with severe pyogranulomatous pneumonia.

In general, the diagnosis of bacterial pneumonia in felines occurs less frequently than in dogs [16]. The main microorganisms related to pathologies of the lower respiratory tract of cats include *Pasteurella* spp., *Escherichia coli*, *Staphylococcus* spp., *Streptococcus* spp., *Pseudomonas* spp., *Bordetella bronchiseptica*, and *Mycoplasma* spp. [17].

Chest radiographs are commonly the first test ordered when pneumonia is suspected [18]. In one of the animals in this study, the alveolar pattern was observed. In the other, the mixed pattern (interstitial and alveolar) suggested a picture of bacterial pneumonia as described by Levy *et al.* [19].

Initially, fungal pneumonia was considered in both cases as these patterns can also be seen in such conditions such as *Pneumocystis canis* and *Penicillium brevicompactum* infection [20, 21]. Chest radiography is an auxiliary diagnostic tool; however, different diseases may reveal similar radiographic patterns [22].

The macroscopic and histological changes observed in this study were compatible with those described by Foster *et al.* [10], who investigated the infection by *N. animaloris* in porpoises (*Phocoena phocoena*). In both the cats, this multiple foci pattern indicated a hematogenous spread as described in porpoises after bites by gray seals (*Halichoerus grypus*).

Corroborating with other authors [7,9], confirmation of the diagnosis was carried out through the isolation and sequencing of the 16S rRNA gene. According to Cobiella *et al.* [9], infection by *Neisseria* sp. should be considered whenever there is an isolation of gram-negative, catalase-positive bacteria that do not belong to the Enterobacteriaceae family, with a molecular diagnosis being a necessary method in the identification and correct diagnosis of bacteria in humans and animals.

This study suggests that *Neisseria* genus members may be involved in lower respiratory tract infections (pyogranulomatous pneumonia) in cats.

Authors' contributions

HM, ATHIS, LADP, YPAT, EMC, VRFSVD, LN collaborated with the manuscript. HM, ATHYS, VD, LN participated in microbial isolation and the molecular genetic studies. LADP, EMC performed necropsy. YPAT, VRFS carried out animal clinical service. LN, VD participated in its design and coordination and helped to draft the manuscript. All authors read and approved the final manuscript.

Declaration of conflicting interests

The author(s) declared no potential conflicts of interest with respect to the research, authorship, and/or publication of this article.

Statement of Informed Consent

The owner understood procedure and agrees that results related to investigation or treatment of their companion animals, could be published in Scientific Journal Acta Veterinaria-Beograd.

REFERENCES

1. Liu G, Tang CM, Exley RM: Non-pathogenic *Neisseria*: members of an abundant, multi-habitat, diverse genus. *Microbiol* 2015, 161:1297-1312.
2. Centers for Disease Control and Prevention. Sexually transmitted diseases treatment guidelines. *Morb Mortal Wkly Rep* 2015, 64:1–137.
3. Cohn AC, Harrison LH. Meningococcal vaccines: current issues and future strategies. *Drugs* 2013, 73:1147-1155.
4. Ujvári B, Orbán B, Incze Z, Psáder R, Magyar T. Occurrence of Pasteurellaceae and Neisseriaceae bacteria in the pharyngeal and respiratory tract of dogs and cats—Short communication. *Acta Vet Hung* 2020, 30;68(3):231-235.
5. Hurst CJ: Opportunistic bacteria associated with mammalian livestock disease. In: *The Connections between Ecology and Infectious Disease*. Springer: Cham; 2018, 185–238.
6. Volokhov DV, Amselle M, Bodeis-Jones S, Delmonte P, Zhang S, Davidson MK, Gulland FM, Chizhikov, VE. *Neisseria zalophi* sp. nov., isolated from oral cavity of California sea lions (*Zalophus californianus*). *Arch Microbiol* 2018, 200:819-828.
7. Wang C, Luo J, Wang H, Amer S, Ding H, Dong Y, He H. Isolation and characterization of a *Neisseria* sp. from the captive wild goose (*Anser anser*). *Integr Zool* 2016, 11:128-133.
8. Carr SV, Martin PA, Keyes S L, Tong LJ, Talbot JJ, Muscatello G, Barrs VR. Nasofacial infection in a cat due to a novel bacterium in Neisseriaceae. *JFMS Open Reports* 2015, 1: 2055116915597240.
9. Cobiella D, Gram D, Santoro D. Isolation of *Neisseria dumasiana* from a deep bite wound infection in a dog. *Vet Dermatol* 2019, 30:556-e168.
10. Foster G, Whatmore AM, Dagleish MP, Malnick H, Gilbert MJ, Begeman L, Macgregor SK, Davison NJ, Roest HJ, Jepson P, Howie F, Muchowski J, Brownlow AC, Wagenaar JA, Kik MJL, Deaville R, ten Doeschate MTI, Barley J, Hunter L, Ijseldijk LL. Forensic

- microbiology reveals that *Neisseria animaloris* infections in harbour porpoises follow traumatic injuries by grey seals. *Sci Rep* 2019, 9:1-8.
11. Quinn PJ, Carter ME, Markey BK, Carter GR. General procedures in microbiology. *Clinical Veterinary Microbiology*. 2th ed, St. Louis: Mosby; 2013, 920p.
 12. Sambrook J, Russel DW: Molecular cloning: a laboratory manual. 3th ed. New York: Cold Spring Harbor Laboratory Press; 2001, 2028p.
 13. Lane DJ: 16S/23S rRNA sequencing. *Nucleic acid techniques in bacterial systematics*. New York: John Wiley & Sons; 1991,125-175.
 14. Turner S, Pryer KM, Miao VPW, AMP Palmer JD. Investigating deep phylogenetic relationships among cyanobacteria and plastids by small subunit rRNA sequence analysis. *J Eukaryot Microbiol* 1999, 46: 327-338.
 15. Whyte A, Gracia A, Bonastre C, Tejedor M T, Whyte J, Montegudo LV, Simón C. Oral disease and microbiota in free-roaming cats. *Top Companion Anim M* 2017, 32: 91-95.
 16. Dear JD. Bacterial Pneumonia in Dogs and Cats: An Update. *The Veterinary Clinics of North America. Small Animal Practice* 2020, 50: 447.
 17. Foster SF, Martin P, Allan GS, Barrs VR, Malik R. Lower respiratory tract infections in cats: 21 cases (1995–2000). *J Feline Med Surg* 2004, 6:167-180.
 18. Cohn LA: Pulmonary parenchymal disease. In: *Textbook of Veterinary Internal Medicine*. 7th ed. Saunders: St Louis; 2009, p.78-144.
 19. Levy N, Ballegeer E, Koenigshof A. Clinical and radiographic findings in cats with aspiration pneumonia: retrospective evaluation of 28 cases. *J Small Anim Pract* 2019, 60:356-360.
 20. Dear JD. Bacterial pneumonia in dogs and cats: an update. *Vet Clin N AM-Small* 2020, 50(2), 447.
 21. Caro-Vadillo A, Payá-Vicens MJ, Martínez-Merlo E, García-Real I, Martín-Espada C. Fungal pneumonia caused by *Penicillium brevicompactum* in a young Staffordshire bull terrier. *Vet Rec* 2007, 160(17), 595.
 22. Thrall DE. The canine and feline lung. In: *Textbook of Veterinary Diagnostic Radiology*. 6th ed. Saunders Elsevier: St Louis; 2013, p.608-631.

PNEUMONIJA KOD MAČAKA POVEZANA SA *Neisseria* sp.

Herica MAKINO, Alessandra Tammy HAYAKAWA ITO DE SOUSA, Lucas Avelino DANDOLINI PAVELEGINI, Yolanda Paim ARRUDA TREVISAN, Edson MOLETA COLODEL, Valéria Régia FRANCO SOUSA, Valéria DUTRA, Luciano NAKAZATO

Neisseria spp. je Gram pozitivna diplokokna bakterija koja je prisutna na mukoznim površinama životinja, pri čemu ne dovodi do uočljivih patoloških promena. Cilj ove studije bio je da opiše izolaciju *Neisseria* spp. kod teških slučajeva piogranulomatozne pneumonije sa formiranjem Splendore-Hoeppli strukture kod dve mačke lečene u veterinarskoj bolnici. Ovaj rad sugerše da su članovi roda *Neisseria* možda uključeni u

infekcije donjih disajnih puteva kod mačaka, s tim što je molekularna dijagnoza neophodan metod za tačnu identifikaciju ove bakterije na životinjama.