

## **CORRELATION OF BONE STRENGTH IN AN ANIMAL MODEL (RABBIT) AFTER FRACTURE AND DURING THE PERIOD OF FIXATION WITH A TITANIUM MICRO PLATE**

Risto DUČIĆ<sup>1</sup>, Bogomir Bolka PROKIĆ<sup>1</sup>, Milan HADŽI-MILIĆ<sup>1\*</sup>, Nikola KRSTIĆ<sup>2</sup>, Vera TODOROVIĆ<sup>3</sup>, Nikola RADMANOVIĆ<sup>4</sup>, Maja ĐORĐEVIĆ<sup>5</sup>, Marko DAKOVIĆ<sup>6</sup>, Farah HAMZAGIĆ<sup>7</sup>, Srblav PAJIĆ<sup>8</sup>

<sup>1</sup>University of Belgrade, Faculty of Veterinary Medicine, Department of Surgery, Orthopedics and Ophthalmology; <sup>2</sup>University of Belgrade, Faculty of Veterinary Medicine, Department of Radiology and Radiation Hygiene; <sup>3</sup>University of Zenica, Faculty of Medicine, Department of Histology and Embryology, Bosnia and Herzegovina; <sup>4</sup>General Hospital Euromedik 2, Belgrade, Serbia; <sup>5</sup>University Clinical Centre of Serbia, Clinic for Plastic and Reconstructive Surgery, Zvečanska no.6, Belgrade, Serbia; <sup>6</sup>University of Belgrade, Faculty of Physical Chemistry, Studentski trg 3, Belgrade, Serbia; <sup>7</sup>Faculty of Medical Sciences of the University of Kragujevac, Svetozar Markovića 69, Kragujevac, Serbia; <sup>8</sup>University Clinical Centre of Serbia, Emergency Center, Center for Emergency Care and Neurotrauma, Pasterova 2, Belgrade, Serbia;

(Received 01 June, Accepted 11 November 2022)

The period of bone healing after trauma goes through certain physiological processes. In situations where a bone fracture occurs, our intention is to surgically position in an appropriate morpho-anatomical position. For osteosynthesis we used vipla wire and micro plates with corresponding screws.

The aim of our research was to evaluate the optimal time for the removal of the osteosynthetic material, fracture site biomechanical stability, and measurement of the callus thickness.

For this research ten 4 months old rabbits with right leg femur fracture were used. Osteosynthesis was done with titanium micro plates, corresponding screws and vipla wire. Experimental animals were observed through the post-operative period at the first and seventh postoperative day and there on at 2, 4, 6, 9, 12 weeks. Further additional fixation was needed in one of the rabbits in the second week.

The postoperative period provided us information about the optimal moment for the removal of titanium micro plates. It showed that over a period of six weeks, the bone had almost all normal biomechanical properties. Significantly greater strength and rigidity of the recovered femur were obtained after 12 weeks. Micro plates that were removed after 4, 6 or 9 weeks, did not need further fixation and therefore fixation was not applied, compared to those placed during the 12 weeks. X Ray evaluation provided us with follow up results of fracture healing.

---

\*Corresponding author: e-mail: mmilic@vet.bg.ac.rs

The results suggest that it is acceptable to remove titanium micro plates after a period of healing, that is, after the formation of the callus and bridging of the fracture gap and diastasis with newly formed bone.

**Keywords:** rabbit, femur, osteotomy, microplates, bone strength

## INTRODUCTION

The need for osteosynthesis for fractures of long animal bones occurs in 25% cases, based on data and analysis of the used osteosynthetic material at the Clinic for Surgery, Orthopedics and Ophthalmology of the Faculty of Veterinary Medicine in Belgrade. In such cases, we use a rigid connection in order not to allow micro movements of fragments of fractures, which would cause them not to heal or to create pseudoarthrosis at the ends, thereby prolonging the suffering and post-traumatic stress of the animals.

Previous research into internal fixation with metal plates stands in the view that it provides satisfactory conditions for healing bone diaphysis fractures [1-11]. However, the effect of the rigid plate over time leads to a remodeling of its effect, primarily to protect against stress, causing osteopenia and reduced strength of the newly created bone [12-16]. Therefore, it is imposed in itself, in order for this phenomenon of secondary bone weakening to be prevented, shortly after the repair of the fracture, the view is that it is desirable to remove metal plates, as this has proven rational, as reported by Uhthoff and Finnegan [17], believing that early removal of plates made restoration of bone physiology into normal bone. Their position on the timely removal of the plate was not explicit and/or noted for a period of time. A similar experiment was designed as part of a study, where external fixation was applied [18].

In our study, we wanted to focus the research on collecting data and information about the optimal time for the removal of the rigid osteosynthetic connection, in this case metal titanium micro plates on bone diaphysis.

## MATERIAL AND METHODS

Ten rabbits of both sexes whose weight ranged from 3,000 to 3,650 grams were included in the study. Before the surgical procedure, 10 Chinchilla rabbits (*Oryctolagus cuniculus*) underwent the standard accommodation protocol of 14 days.

Induction of anesthesia was done with 35 mg/kg Ketamidol 10%, (Ketamine Hydrochloride), Richter Pharma AG, Austria, and 5 mg/kg Xylazine 2%, 20 mg/ml (Xylased), Bioveta, Czech Republic) administered intramuscularly and maintained with Sevorane®, 100%, AbbVie Biopharmaceuticals GmbH, Belgrade.

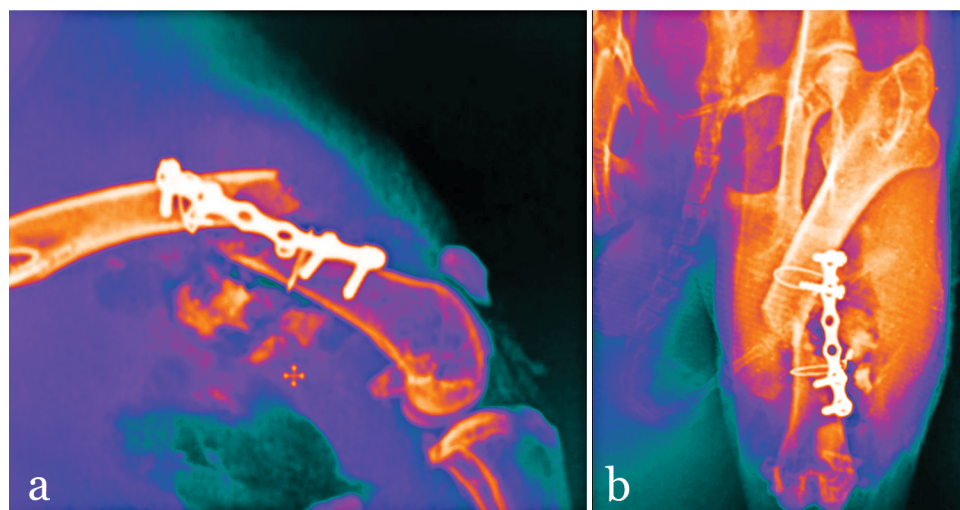
With the premedication and during 5 postoperative days, Baytril 2.5% (enrofloxacin, Bayer, Germany) 10 mg/kg i.m. and Butorfanol subcutaneously 0.5 mg/kg (Richter Pharma Ag, Austria) were used.

Operations were performed on the right leg while the left leg was used as the control. Transverse femur osteotomy in the middle bone portion we made with an oscillating saw. The osteotomized femur was fixed with a flat titanium micro plate with seven openings of 45 x 5 x 1 mm (Zimmer Biomet, Palm Beach Gardens, Florida, USA). The plate was placed with orthopedic screws (diameter of 2.0 x 7 mm) on the antero-posterior aspect of the femur. Osteotomies were exactly reduced, but without compression at the junction point. Both endings of the femur were immediately recorded with X ray imaging after surgery (Table 1). The rabbits tolerated the procedure well.

**Table 1.** Display values in percentages with a range of mineral content in the bones, its thickness and elastic rigidity relative to the control group in osteotomized parts of femur. The median mineral content in the bone is determined between two drilled and distant screw holes, whereby the first-middle and second is 1.5 cm away from the plate-distal.

Weeks postoperative			Bone mineral content		Deformation	
Group	Weeks	Follow up ending	Central	Distal	Deformatio thickness	Elastic thickness
1	4	6	172	108	65 (51-115)	123 (80-139)
2	6	12	169	112	118 (108-148)	215 (135-228)
3	9	12	203	102	124 (90-135)	112 (88-221)
4	12	12	132	100	66 (51-91)	135 (73-170)

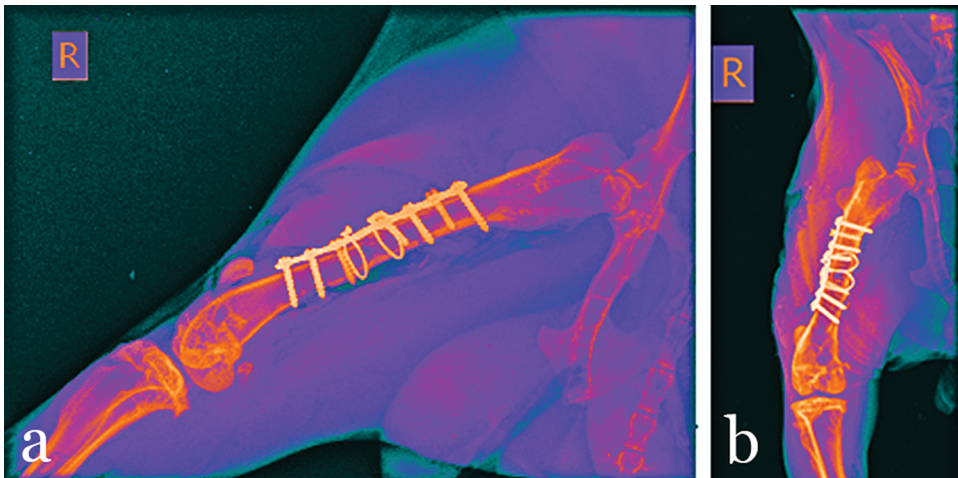
Each group consisted of two animals. The removal period of titanium micro plates is given in groups of 1-4, where both femurs were recorded by radiogram (Figure 1). All surgical procedures were performed in the first act during internal fixation.



**Figure 1.** A postoperative radiograph of fracture site after stability testing

## Bone healing assessment

To determine the amount of periosteal callus, the external antero-posterior and transverse diameter were measured at the place of the osteotomy and at the appropriate level of the control bones. Radiograms were studied according to the method used to assess the position of bone fragments. The mineral content in the bones was measured by photon absorption using a  $^{241}\text{Am}$  gamma radiation scanning device (AB Gambro, Lund) (Figure 2). The scan was performed over the bones in two levels: between two distant screw holes and 15 mm away from the distant end of the micro plate. In the control group, healthy leg bones were scanned at the corresponding levels.



**Figure 2.** Lateral, after 4 weeks **(a)** and antero-posterior, after 6 weeks **(b)** radiography.

## Biomechanical tests

The femurs were tested in three deformation points in an antero-posterior direction using the Interrogation Machine (Instron) [19].

## Statistical analysis

We used Wilcoxon's two-sample (two-point test) to calculate statistical differences between the groups. The differences were considered significant for P-values  $<0.05$ .

## RESULTS

There was no difference in the amount of periosteal callus between the femur where the micro plate was removed before euthanasia and the one that was positioned in the animal until the very moment of euthanasia, either at 6 or 12 weeks. The mineral content at the level between the distant screw holes was greater in the femur with

micro plates removed after 4, 6 or 9 weeks compared to those where micro plates remained until the 12<sup>th</sup> week ( $p < 0.05$ , Table 1). The level in mineral content on the sites where the micro plates were placed was not different among the groups.

There was no significant difference in firmness with the removal of micro plates after 4 weeks and the one where the plate remained for up to 6 weeks (Table 1). However, the strength of the bones with the removal of micro plates at 4, 6 or 9 weeks was greater than that of the bone where the plates were positioned for 12 weeks ( $p < 0.01$ ).

The median values of the osteotomized bone strength in groups 2, 3 and 4 were greater than those of their corresponding control bones.

Rigidity (Table 1) is higher in femur with micro plates removed after 6 weeks compared to those that were positioned up to the 12<sup>th</sup> week ( $p < 0.05$ ). When micro plates are removed from the bone after 4, 6 and 9 weeks, they are considered one large group compared to those where the continuous presence of the plate was for 12 weeks. Bone thickness was greater in the bones with the micro plate where the removal was done before the euthanasia ( $p < 0.05$ ). The stiffness of all the osteotomized tibiae in groups 2-4 was greater than the corresponding control bones.

Deformation due to fracture was greater in Group 4 in contrast with tibiae in Group 6 ( $p < 0.05$ ). For the rest, there was no difference in deformation.

## DISCUSSION

If the results of experimental healing fractures using micro plate fixation are intended to shed light on the healing process of long bone fractures in humans, the place and role of rigidity fixation should be comparable, which should be a guide to fixation and healing periods of corresponding human bones. In previous *in vitro* studies, the average rigidity of bending was defined by about 40% related to rigidity.

The experimental healing of the intact tibiae fracture was obtained after fixation of the osteotomy of rabbit tibiae using steel plates of the same size as done in the research in 1983 Terjesen and Benum [19]. This corresponded to a medium rigidity of about 50% obtained after fixation with a tibial plate, fixations using a self-compression plate (DCP) on osteotomized human tibiae. Thus, fixation with an adjusted plate seemed a suitable model for studying bone healing in the long bones of rabbits.

There are no significant differences in the formation of the periosteal callus between animals where the plates remained until the end of the follow up period, and those where plates were removed before the end of the follow-up. The radiographic study also showed no differences between the groups regarding the combination of osteotomized ends of bone fragments. Therefore, differences in biomechanical qualities between some groups can hardly be due to different patterns of healing. The mineral content under the plate was higher when the plate was removed early, compared to those on which the plate was present for 12 weeks. This is probably due

to the effect of micro-stress protection plates [18, 20-22]. Distal from the place of the placed micro plate, no differences were observed in the mineral content. So, there was no osteoporosis in the healing bones, only an inflammation was present for several days postoperatively.

The strength of bone healing was slightly higher where the micro plates remained for six weeks compared to the ones where bones were only drilled and screws were put in, that were removed after four weeks.

Although, there was a difference, it is not relevant. This is consistent with previous observations that the initial stages of bone healing healed more quickly with rigid fixation [23-25].

During the remodeling phase, the bone was therefore weakened by the effect of stress protection [26-28].

Hence, it seems rational to remove the plate before this harmful effect on bone integrity. This was confirmed by experimental research [20-22, 25, 30]. The same morphometry of bone healing after femur osteotomy in dogs, Uthoff and Finnegan [17, 30] found a rise in bone mass when the plate was removed weeks before follow up ended, and a reduction when the plate remained until the end of follow up. The observation time was extended to 60 weeks and the early removal of the plates at 8 weeks followed more pronounced remodeling and physiological bone renewal before late removal in the 40<sup>th</sup> week. Our results of this study of biomechanical examination of the effects of micro plates and their time presence in the process of healing tibia bone fractures are consistent with previous studies.

Uthoff and Finnegan [17, 31, 33] have argued that the duration of the return to normal bone architecture, and therefore the return of full power, is not yet known and seems to be longer than previously believed. That's probably true of bone architecture, but the results of this research show that the return of normal strength and bone rigidity is a much faster process. Even after six weeks, biomechanical properties reached almost normal values. Most of the treated bones were stronger and firmer than the controls when the plate was removed at 4, 6 or 9 weeks followed by the follow up ending at 12 weeks. These results show that fracture healing is triggered by the early removal of plates, which allows the bone to be exposed to normal functional loads.

Premature removal of the plates involves the risk of re-fracture. In a previous study, the median strength of osteotomized rabbit tibias after approximately 40 percent of the normal value of the presence of osteosynthetic material after 4 weeks [18, 24]. The risk of re-fracture appears to have dropped significantly after removing plates from the healing site.

Therefore, it seems that the optimal time to remove the plates in the rabbit's tibia is about 6 weeks. In larger animals such as dogs, the plate is removed after 8 weeks, which seems rational; after the removal of the plate, there was no refracture [17-19, 24, 25, 28]. This applies only to osteotomies and fractures where blood flow is

not too severely damaged, where there is good bone contact and where there are no interfragments in the fracture.

In more severe fractures with multiple fragments and insufficient vascularization of the blood, bone healing progresses more slowly, and the plate should probably stay a little longer. The healing of most simple tibia fractures in patients takes approximately 3-4 months. Removal of tibial plates 18-24 months post-operative is recommended by the AO Group [1,2,34-38].

## **CONCLUSION**

The results suggest that it is expedient to remove titanium micro plates after a period of healing, that is, after the formation of the callus and the bridging of the fractured crack and diastasis of the newly formed bone, since we believe that the healing period has reached its full extent of osteoconduction, and the bone in this part has reached its full biomechanical properties. This is also the moment when the micro plate can prevent and protect the bone from re-fracture. The findings tell us, contrary to clinical practice, that this is significantly before the period of complete healing occurs, that the activity of individuals would result in physiological failure without the possibility of secondary stress.

### **Ethics approval and consent to participate**

The study (its segment) was approved by the Ethics Committee of the Faculty of Veterinary Medicine, University of Belgrade and the Ministry of Agriculture, Forestry and Water Management - Veterinary Administration of the Republic of Serbia, decision No. 323-07-06340 / 2019-05 / 2 of July 10, 2019. (This experiment was part of the project for implementing artificial bone on animal model. Consequence of the large artificial defect and animal weight was femur fracture).

### **Availability of data and materials**

The data sets used and analyzed during the current study are available from the corresponding author on reasonable request.

### **Acknowledgment:**

“The study was supported by the Ministry of Education, Science and Technological Development of the Republic of Serbia (Contract number 451-03-9/2021-14/200143).” And projects III 45006.

### Authors' contributions

RD, SP, BP and MHM participated in the study design, analyzed the data, and drafted the manuscript. RD, NR and SP carried out the experimental part of the study and made a substantial contribution to conception, design and analysis, acquisition and interpretation of data. BP and MDJ were responsible for animal care and welfare. RD,SP,FH,MDJ,NR ,BP and MHM performed the surgical procedures. FH and MDJ performed the statistical analysis. NK and MD technical processing of radiological images. RD, BP, MHM,VT,NR,MDJ,MD,FH and SP were involved in the final drafting of the manuscript and revised it critically for important intellectual content. All authors discussed the results and contributed to the final manuscript.

### Declaration of conflicting interests

The author(s) declared no potential conflicts of interest with respect to the research, authorship, and/or publication of this article.

## REFERENCES

1. Garcia-Pertierra S, Ryan J, Richardson J. et al. Presentation, treatment and outcome of long-bone fractures in pet rabbits (*Oryctolagus cuniculus*). *J Small Anim Pract* 2020; 61 (01) 46-50
2. Shapiro F. Bone development and fracture repair: The role of mesenchymal osteoblasts and surface osteoblasts, *European Cells and Materials* Vol. 15 2008 (pages 53-76) DOI: 10.22203/eCM.v015a05 ISSN 1473-2262
3. Sasai H, Fujita D, Tagami Y. et al. Characteristics of bone fractures and usefulness of micro-computed tomography for fracture detection in rabbits: 210 cases (2007-2013). *J Am Vet Med Assoc* 2015; 246 (12) 1339-1344
4. Zehnder A, Kapatkin AS. Orthopedics in Small Mammals. In: Carpenter J, Ferrets, Rabbits, and Rodents. Elsevier;. 2012: 472-484
5. Ciwko E, Sadar MJ, Bennett K, Linn K. Transfixation pin splinting as an alternative external coaptation method in domestic rabbit (*Oryctolagus cuniculus*) long bone fractures. *J Small Anim Pract* 2018; 27 (04) 31-37
6. Terjesen T, Benum P. Mechanical effects of metal plate fixation. In vitro investigation on intact and osteotomized human and rabbit tibiae. *Acta Orthop Scand* 1983; 54 (02) 256-262
7. Massie AM, Kapatkin AS, Garcia TC, Guzman DS-M, Chou P-Y, Stover SM. Effects of hole diameter on torsional mechanical properties of the rabbit femur. *Vet Comp Orthop Traumatol* 2019; 32 (01) 51-58
8. Sasai H, Fujita D, Seto E. et al. Outcome of limb fracture repair in rabbits: 139 cases (2007-2015). *J Am Vet Med Assoc* 2018; 252 (04) 457-463
9. Terjesen T. Bone healing after metal plate fixation and external fixation of the osteotomized rabbit tibia. *Acta Orthop Scand* 1984; 55 (01) 69-77
10. Gibert S, Ragetly GR, Boudrieau RJ. Locking compression plate stabilization of 20 distal radial and ulnar fractures in toy and miniature breed dogs. *Vet Comp Orthop Traumatol* 2015; 28 (06) 441-447



11. Fulkerson E, Egol KA, Kubiak EN, Liporace F, Kummer FJ, Koval KJ. Fixation of diaphyseal fractures with a segmental defect: a biomechanical comparison of locked and conventional plating techniques. *J Trauma* 2006; 60 (04) 830-835
12. Rich GA. Rabbit orthopedic surgery. *Vet Clin North Am Exot Anim Pract* 2002; 5 (01) 157-168, vii
13. Frigg R. Locking compression plate (LCP). An osteosynthesis plate based on the dynamic compression plate and the point contact fixator (PC-Fix). *Injury* 2001; 32 (Suppl. 02) 63-66
14. Wagner M. General principles for the clinical use of the LCP. *Injury* 2003; 34 (Suppl. 02) B31-B42
15. Takizawa H, Honnami M, Sakai T, Sasaki A, Sakamoto A, Mochizuki M. A biomechanical comparison of three miniature locking plate systems in a rabbit radial and ulnar fracture model. *Vet Comp Orthop Traumatol* 2019; 32 (04) 297-304
16. Preston TJ, Glyde M, Hosgood G, Day RE. Dual bone fixation: a biomechanical comparison of 3 implant constructs in a mid-diaphyseal fracture model of the feline radius and ulna. *Vet Surg* 2016; 45 (03) 289-294
17. Uthoff, H. K. & Finnegan, M. (1983) The effects of metal plates on post-traumatic remodelling and bone mass. *J. Bone Joint Surg.* 65-B, 66-71.
18. Terjesen, T. (1984) Plate fixation of tibial fractures in the rabbit. Correlation of bone strength with duration of fixation. *Acta Orthop. Scand.* 55, 452-456.
19. Terjesen, T. & Benum, P. (1983b) The stress-protecting effect of metal plates on the intact rabbit tibia. *Acta Orthop. Scand.* 64, 810-818.
20. Anderson, L. D. (1965) Compression plate fixation and the effect of different types of internal fixation on fracture healing. *J. Bone Joint Surg.* 47-A, 191-208.
21. Jager, M., Gordes, W., Kossyk, W. & Ungethim, M. (1976) Bruchfestigkeitsuntersuchungen bei konservativ (Gipsfixation und Markraumschienung) und operativ (stabile Plattenosteosynthese) behandelten Osteotomien der Kaninchen-Tibia. *Unfallheilkunde* 79, 193-201.
22. Müller, M. E., Allgower, M., Schneider, R. & Willenegger, H. (1979) *Manual of internal fixation.* Springer Verlag, Berlin, Heidelberg, New York.
23. Rhinelander, F. W. (1974) Tibia1 blood supply in relation to fracture healing. *Clin. Orthop.* 105, 34-81.
24. Terjesen, T. (1984b) Healing of rabbit tibia1 fractures using external fixation. Effects of removal of the fixation device. *Acta Orthop. Scand.* 56, 192-196.
25. Wolf, J. W., White, A. A., Panjabi, M. M. & Southwick, W. O. (1981) Comparison of cyclic loading versus constant compression in the treatment of long-bone fractures in rabbits. *J. Bone Joint Surg.* 63-A, 805-810.
26. Paavolainen, P., Slatis, P., Karaharju, E. & Holmstrom, T. (1979) The healing of experimental fractures by compression osteosynthesis. *Acta Orthop. Scand.* 50, 369374.
27. Schenk, R. & Willenegger, H. (1963) Zum histologischen Bild der sogenannten Primarheilung der Knochenkompakta nach experimentellen Osteotomien am Hund. *Experientia* 19, 593-595.
28. Uthoff, H. K. & Dubuc, F. L. (1971) Bone structure changes in the dog under rigid internal fixation. *Clin. Orthop.* 81, 165-170.
29. Meeson RL, Davidson C, Arthurs GI. Soft-tissue injuries associated with cast application for distal limb orthopaedic conditions. A retrospective study of sixty dogs and cats. *Vet Comp Orthop Traumatol* 2011; 24 (02) 126-131

30. Noser, G. A., Brinker, W. O., Little, R. W. & Lammerding, J. J. (1977) Effect of time on strength of healing bone with bone plate fixation. *J. Am. Anim. Hosp. Assoc.* 13, 559-561.
31. Craig A, Witte PG, Moody T, Harris K, Scott HW. Management of feline tibial diaphyseal fractures using orthogonal plates performed via minimally invasive plate osteosynthesis. *J Feline Med Surg* 2018; 20 (01) 6-14
32. Pozzi A, Risselada M, Winter MD. Assessment of fracture healing after minimally invasive plate osteosynthesis or open reduction and internal fixation of coexisting radius and ulna fractures in dogs via ultrasonography and radiography. *J Am Vet Med Assoc* 2012; 241 (06) 744-753
33. Lenz M, Stoffel K, Gueorguiev B, Klos K, Kielstein H, Hofmann GO. Enhancing fixation strength in periprosthetic femur fractures by orthogonal plating—a biomechanical study. *J Orthop Res* 2016; 34 (04) 591-596
34. Labus KM, Sutherland C, Notaros BM. et al. Direct electromagnetic coupling for non-invasive measurements of stability in simulated fracture healing. *J Orthop Res* 2019; 37 (05) 1164-1171
35. Johnson AL, Houlton JEF, Vannini R. *AO Principles of Fracture Management in the Dog and Cat.* AO Pub; 2005
36. Palierno S, Froidefond B, Swider P, Autefage A. Biomechanical comparison of two locking plate constructs under cyclic loading in four-point bending in a fracture gap model: two screws versus three screws per fragment. *Vet Comp Orthop Traumatol* 2019; 32 (01) 59-66
37. De Arburn Parent R, Benamou J, Gatineau M, Clerfond P, Planté J. Open reduction and cranial bone plate fixation of fractures involving the distal aspect of the radius and ulna in miniature- and toy-breed dogs: 102 cases (2008-2015). *J Am Vet Med Assoc* 2017; 250 (12) 1419-1426
38. Alza Salvatierra DN, Witte PG, Scott HW, Catchpole C. Pantarsal arthrodesis in cats using orthogonal plating. *J Feline Med Surg* 2018; 20 (01) 45-54

## **KORELACIJA ČVRTOĆE KOSTI ANIMALNOG MODELA (KUNIĆA) NAKON PRELOMA I PERIODA TRAJANJA FIKSACIJE TITANIJUMSKOM MIKRO PLOČICOM**

Risto DUČIĆ, Bogomir Bolka PROKIĆ, Milan HADŽI-MILIĆ,  
Nikola KRSTIĆ, Vera TODOROVIĆ, Nikola RADMANOVIĆ, Maja ĐORĐEVIĆ, Marko DAKOVIĆ, Farah HAMZAGIĆ, Srbislav PAJIĆ

Period zarastanja kostiju prolazi kroz određene fiziološke procese nakon traume. U situacijama kada dođe do preloma kostiju, namera je da ih hirurški pozicioniramo u adekvatan morfo-anatomski položaj. Za osteosintezu upotrebljene su vipla žica i mikro ploče sa odgovarajućim šrafovim.

Cilj istraživanja bio je procena optimalnog vremena za uklanjanje osteosintetskog materijala, kao i biomehanička stabilnost mesta preloma i merenje debljine stvorenog kalusa.

Za ovo istraživanje korišćeno je deset kunića starih 4 meseca sa prelomom butne kosti desne noge. Osteosinteza je urađena titanijumskim mikro pločama, odgovarajućim šrafovim i vipła žicom. Eksperimentalne životinje su praćene kroz postoperativni period prvi, sedmi postoperativni dan, kao i naredne 2., 4., 6., 9., 12. nedelje. Dalja dodatna fiksacija je bila potrebna kod jednog kunića u drugoj nedelji.

Postoperativni period nam je pružio informacije o optimalnom periodu za skidanje titanijumskih mikro ploćica. Pokazalo se da je u periodu od šest nedelja kost imala skoro sva normalna biomehantička svojstva. Znaćajno veća ćvrstoća i rigidnost oporavljene butne kosti dobijena je nakon 12 nedelja, a mikro ploćice su uklonjene nakon 4, 6 ili 9 nedelja, bez potrebe za nastavkom fiksacije i nisu naknadno primenjene u poređenju sa onima postavljenim tokom 12 nedelja. Rendgenska evaluacija je pružila naknadne rezultate zarastanja preloma.

Rezultati sugerišu da je prihvatljivo uklanjanje titanijumskih mikro ploćica nakon perioda zarastanja, odnosno nakon formiranja kalusa i premošćavanja pukotine preloma i dijastaze sa novonastalom kosti.