

Short communication

MORPHOLOGICAL DIFFERENCES OF PANCREATIC LESIONS IN MUTE SWANS AND HENS NATURALLY INFECTED WITH HIGHLY PATHOGENIC AVIAN INFLUENZA VIRUS H5N8

BOŽIĆ Biljana^{1*}, POLAČEK Vladimir¹, VUČIĆEVIĆ Ivana²,
VIDANOVIĆ Dejan³, VASKOVIĆ Nikola³, PRODANOV-RADULOVIĆ Jasna¹,
ALEKSIĆ-KOVAČEVIĆ Sanja²

¹Scientific Veterinary Institute “Novi Sad”, Novi Sad, Serbia; ²Department of Pathology, Faculty of Veterinary Medicine, University of Belgrade, Belgrade, Serbia; ³Veterinary Institute “Kraljevo”, Kraljevo, Serbia

(Received 22 March, Accepted 13 June 2018)

During the epizootic of highly pathogenic avian influenza subtype H5N8 in Serbia in the winter of 2016-2017, the highest percent of mortality due to this infection was recorded in mute swans (*Cygnus olor*). Besides mute swans, avian influenza virus subtype H5N8 was also diagnosed in a small number of hens in rural households. Pancreatic tissues from avian influenza H5N8 positive mute swans and hens that died during this outbreak were collected to determine the character of morphological lesions and the distribution of the viral antigen in this organ. Macroscopic examination of the pancreas of mute swans revealed hemorrhages as well as necrosis, while there were no macroscopic visible lesions in the pancreas of infected hens. Despite the different macroscopic finding, microscopic examination of the pancreas of both infected bird species revealed lesions in the form of acute pancreatitis and multifocal acinar necrosis. The viral antigen was abundantly expressed in the cytoplasm and nucleus of necrotic cells, as well as in macrophages in both examined bird species. Immunohistochemical expression of the viral antigen in the pancreas was strongly consistent with histological lesions. According to the above described findings, it could be concluded that highly pathogenic avian influenza virus H5N8 has a high affinity to pancreatic tissue in both mute swans and hens and the distribution and the character of the lesions in the pancreas are similar in both bird species.

Key words: avian influenza, hens, H5N8, mute swans, pancreatic lesions

INTRODUCTION

Avian influenza is a viral, highly contagious disease of poultry and wild birds, which leads to substantial health and economic losses in the poultry industry. Considering its zoonotic feature, this disease represents a constant threat to public health. Avian

*Corresponding author: e-mail: biljana@niv.ns.ac.rs

influenza viruses (AIV) are divided into subtypes according to the combinations of different virus surface proteins: hemagglutinin (HA) and neuraminidase (NA). Further classification of avian influenza viruses is based on their ability to cause the disease in chickens. The very virulent viruses cause highly pathogenic avian influenza (HPAI), while low pathogenic avian influenza viruses (LPAI) cause a much milder disease. To date, only viruses of H5 and H7 subtype have been shown to cause HPAI in birds, but not all H5 and H7 viruses are highly virulent [1].

The first outbreak of highly pathogenic avian influenza subtype H5N8 was recorded in Europe at the end of 2014. During the 2015, 2016 and the first half of 2017, large areas of Europe were affected with outbreaks of HPAI H5N8 in poultry, as well as in wild birds. In the Republic of Serbia, the first case of AIV H5N8 infection was reported in mute swans (*Cygnus olor*), at the end of 2016 [2]. Besides mute swans, AIV H5N8 was detected in hens in several households. Mute swans and other wild birds of the orders *Anseriformes* and *Charadriiformes* are considered as natural reservoirs of avian influenza viruses. However, during AIV H5N8 epizootic in Serbia, mute swans appeared to be highly susceptible and represented the mainly reported affected bird species. Reports from many European countries also demonstrate a high susceptibility of mute swans to AIV H5N8 infection [3–5].

There are many literature data on macroscopic and histopathologic lesions caused by avian influenza viruses. Most of the research was done on naturally and experimentally infected domestic poultry, especially in chickens and turkeys. However, literature data on pathobiology of avian influenza in mute swans are considerably scarce. Clinical signs and pathomorphological findings may vary in different bird species, depending of the strain and pathogenicity of avian influenza virus. Infection caused by HPAI viruses affect multiple visceral organs, cardiovascular and nervous system. HPAI virus strains can be epitheliotropic, endotheliotropic, neurotropic or pantropic depending of the species of host bird. Considering that pancreatic lesions are a common finding in birds naturally and experimentally infected with HPAI viruses, the aim of this study was to determine the character of lesions and the distribution of the viral antigen in the pancreas of mute swans and hens naturally infected with HPAI H5N8 virus.

MATERIALS AND METHODS

For the detection of influenza A virus, tissue samples of brain, spleen, pancreas and lungs were collected from wild and domestic birds that died during avian influenza outbreak in Serbia. Tests were done by real-time RT-PCR method with primers specific for the matrix gene of all influenza viruses, and after the confirmation of the presence of the virus, additional tests were done with primers specific for different virus subtypes. Macroscopic and microscopic examination was done on the pancreas of 15 mute swans and 15 hens in which the highly pathogenic avian influenza virus, subtype H5N8 had been previously proven by real time RT-PCR method. Necropsies were performed according to standard protocol, including gross examinations and photo-

documentation of the pancreas of both bird species. Tissue samples of pancreas were fixed in 10% buffered formaldehyde for 24 hours. After fixation, the tissues were routinely processed and embedded in paraffin. Sections were cut at 5 μ m and stained with hematoxylin and eosin. For immunohistochemistry, commercial staining kit was used - Novolink Polymer Detection Systems, Novocastra (Leica biosystems, Germany). To detect the influenza virus antigen, sections were incubated with rabbit antinucleoprotein serum (kindly provided by Dr. Jens P. Teifke, the Federal Research Institute for Animal Health, Greifswald-Insel Riems, Germany) in a dilution of 1:1000 for 1h in a humid chamber at room temperature. The immunoreaction was visualized using diamino benzidine solution and counterstained with Mayer's hematoxylin.

RESULTS AND DISCUSSION

At necropsy, the predominant macroscopic lesions in the pancreas of mute swans were hemorrhages (Figure 1a) and scattered multifocal necrotic fields of light pink color and round shape, different in size, from 1 to 5 mm diameter (Figure 1b). These lesions were found in all examined mute swans (15/15). Same results were obtained in mute swans naturally and experimentally infected with AIV H5N1 [6–10]. In contrast, there were no visible macroscopic lesions in the pancreas of infected hens. This finding is unusual, despite the fact that in gallinaceous bird species macroscopic lesion in the form of necrosis, hemorrhages, red to light orange to brown mottling of the pancreas are common [11].

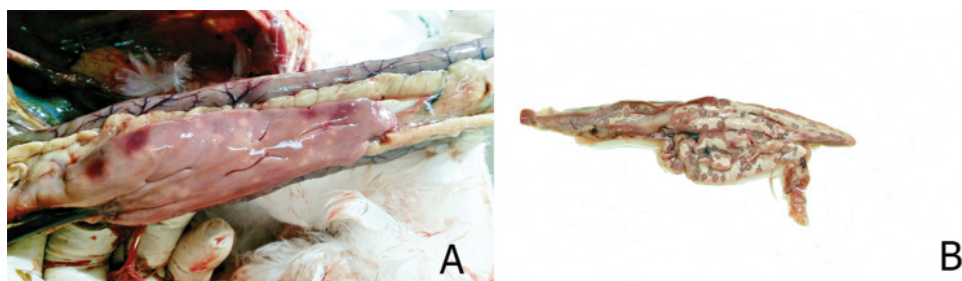


Figure 1. Macroscopic lesions in the pancreas of mute swans: **a)** multifocal hemorrhages **b)** multifocal necrotic fields of whitish-pink color and round shape

Although there were no macroscopic lesions in the pancreas of hens, the major histological lesions were multifocal necrosis of the acini (Figure 2b). Additionally, in the exocrine pancreatic cells vacuolization of the cytoplasm was detected. Patohistological examination of the pancreas of mute swans revealed severe multifocal acinar necrosis with mononuclear infiltrate as well as hemorrhages (Figure 2a).

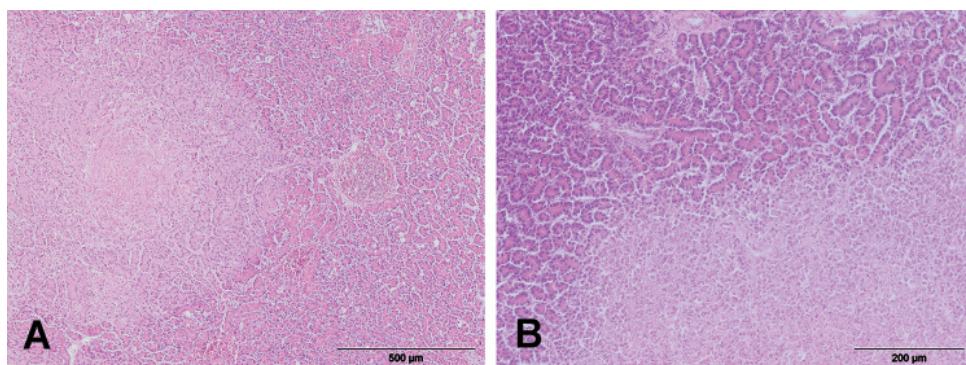


Figure 2. Microscopic lesions in the pancreas. **a)** Mute swan. Necrosis, HE, original magnification x 100; **b)** Hen. Necrosis, HE, original magnification x 200.

Immunostaining for avian influenza virus nucleoprotein in the pancreas was positive in all examined birds. The viral antigen was distributed within the cytoplasm and nucleus of necrotic cells as well in macrophages in both bird species (Figures 3a, 3b). Immunohistochemical demonstration of influenza virus antigen in the pancreas in both bird species was strongly consistent with histological lesions.

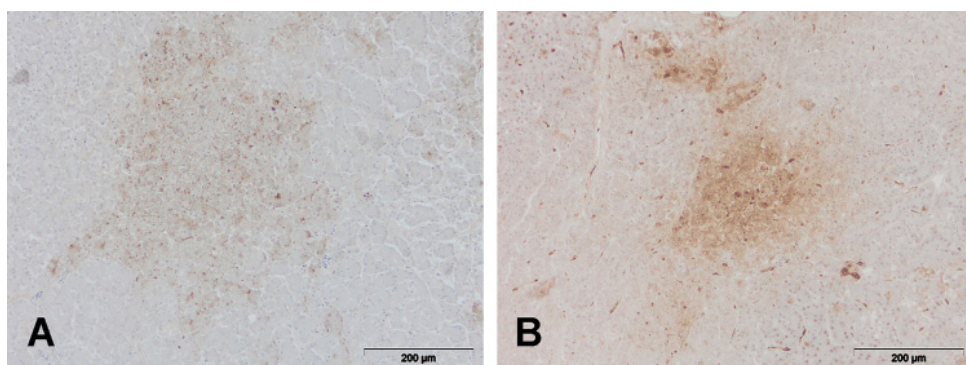


Figure 3. Immunohistochemical staining for AIV nucleoprotein in pancreas. **a)** Mute swan. Intranuclear and intracytoplasmic staining for AIV nucleoprotein in necrotic cells; original magnification x 200 **b)** Hen. Virus antigen in the acinar cells of pancreas; original magnification x 200.

Highly pathogenic avian influenza viruses can cause damage in cells and lead to cell death through necrosis or apoptosis. Necrosis is associated with direct virus replication in cells due to high accumulation of viral nucleoprotein in the cytoplasm and nucleus of infected cells [12]. Exocrine pancreatic epithelium is one of the most frequently reported site of necrosis in infected chickens [13]. These viruses also cause increased vascular permeability and damage of vascular endothelial cells, resulting in edema, hemorrhages and microthrombi formation. If the infected chickens survive

the peracute phase of infection, the virus may disseminate and replicate in multiple organs. Besides the brain and myocardium, the pancreas is the mostly affected organ in HPAI infections. In some HPAI cases, microscopic lesions are more frequent than gross lesions. Histopathological lesions in birds vary with virus strain, route of inoculation, breed of avian host. Most frequently histological lesions are consisted of necrosis and inflammation in multiple organs, but most severely are within the brain, heart, pancreas, lungs, and adrenal glands.

In addition to HPAI viruses, it is demonstrated that some LPAI viruses also may cause pancreatic lesions in chickens and turkeys, but the mechanisms of this damaging are not thoroughly investigated [14]. In mute swans experimentally infected with HPAI H5N1, a high titer of viral particles in the pancreas was detected by RT-PCR method [6]. Also, according to Kalthoff *et al.*, a high level of correlation between viral RNA loads in the pancreas and immunohistochemical detection of avian influenza virus nucleoprotein was demonstrated [6]. In our study, a strong immunopositive finding was detected in all pancreatic tissue samples, in both examined bird species. The results obtained herein and results from other authors suggest on the importance of this organ in the diagnostics of avian influenza. Although macroscopic lesions of the pancreas can be absent (which was confirmed in our study), histopathological examination revealed lesions characteristic for this disease, indicating the significance of histopathology as an important diagnostic tool. In conclusion, our data confirm that in both mute swans and hens HPAIV subtype H5N8 has tropism for the pancreatic tissue and that the distribution and character of the lesions in the pancreas are similar in both bird species.

Acknowledgements

This study was supported by the Ministry of Education, Science and Technological Development of the Republic of Serbia, Project number TR 31011, TR 31084 and III 46002.

Authors' contributions

BB drafted the manuscript, carried out literature research, performed necropsy, examined and described gross lesions, took photography. PV participated in the design of the study. VI carried out histopathological studies and critically revised the manuscript. VD participated in isolation of the virus. VN provide reagents for immunohistochemistry. PRJ helped to draft the manuscript. AKS have been involved in drafting the manuscript and revising it critically for important intellectual content and have given final approval of the version to be published.

Declaration of conflicting interests

The author(s) declared no potential conflicts of interest with respect to the research, authorship, and/or publication of this article.

REFERENCES

1. Alexander DJ. An overview of the epidemiology of avian influenza. *Vaccine*. 2007;25:5637–44.
2. Božić B, Pajić M, Petrović T, Pelić M, Samojlović M, Polaček V. Pathologic Changes in Swans Infected With Highly Pathogenic Avian Influenza (H5N8) Virus. *Arch Vet Med*. 2016;9:77–86.
3. Verhagen JH, van der Jeugd HP, Nolet BA, Slaterus R, Kharitonov SP, de Vries PP, et al. Wild bird surveillance around outbreaks of highly pathogenic avian influenza A(H5N8) virus in the Netherlands, 2014, within the context of global flyways. *Eurosurveillance*. 2015;20:21–32.
4. Pohlmann A, Starick E, Harder T, Grund C, Höper D, Globig A, et al. Outbreaks among Wild Birds and Domestic. *Emerg Infect Dis*. 2017;23:633–6.
5. Núñez A, Brookes SM, Reid SM, Garcia-Rueda C, Hicks DJ, Seekings JM, et al. Highly Pathogenic Avian Influenza H5N8 Clade 2.3.4.4 Virus: Equivocal Pathogenicity and Implications for Surveillance Following Natural Infection in Breeder Ducks in the United Kingdom. *Transbound Emerg Dis*. 2016;63:5–9.
6. Kalthoff D, Breithaupt A, Teifke JP, Globig A, Harder T, Mettenleiter TC, et al. Highly pathogenic avian influenza virus (H5N1) in experimentally infected adult mute swans. *Emerg Infect Dis*. 2008;14:1267–70.
7. Pálmai N, Erdélyi K, Bálint Á, Márton L, Dán Á, Deim Z, et al. Pathobiology of highly pathogenic avian influenza virus (H5N1) infection in mute swans (*Cygnus olor*). *Avian Pathol*. 2007;36.
8. Teifke JP, Klopfeisch R, Globig a, Starick E, Hoffmann B, Wolf PU, et al. Pathology of natural infections by H5N1 highly pathogenic avian influenza virus in mute (*Cygnus olor*) and whooper (*Cygnus cygnus*) swans. *Vet Pathol*. 2007;44:137–43.
9. Ogawa S, Yamamoto Y, Yamada M, Mase M, Nakamura K. Pathology of Whooper Swans (*Cygnus cygnus*) Infected with H5N1 Avian Influenza Virus in Akita, Japan, in 2008. *J Vet Med Sci*. 2009;71:1377–80.
10. Vasković N, Šekler M, Vidanović D, Polaček V, Kukolj V, Matović K, et al. Pathomorphological lesions and distribution of viral antigen in birds infected with the pathogenic strain of H5N1 avian influenza virus. *Acta Vet Belgrade*. 2011;61:591–8.
11. Pantin-Jackwood MJ, Swayne DE. Pathogenesis and pathobiology of avian influenza virus infection in birds. *Rev Sci Tech*. 2009;28:113–36.
12. Swayne D.E. & Halvorson D.A. Diseases of poultry. Y.M. Saif, J.R. Glisson AMF, L.R. McDougald & L. Nolan E, editors. 12th Ed. Blackwell, Ames, Iowa; 2008.
13. Suarez DL, Perdue ML, Cox N, Rowe T, Bender C, Huang J, et al. Comparisons of highly virulent H5N1 influenza A viruses isolated from humans and chickens from Hong Kong. *J Virol* 1998 ;72:6678–88.
14. Capua I, Mercalli A, Pizzuto MS, Romero-Tejeda A, Kasloff S, De Battisti C, et al. Influenza A Viruses Grow in Human Pancreatic Cells and Cause Pancreatitis and Diabetes in an Animal Model. *J Virol*. 2013;87:597–610.

MORFOLOŠKE KARAKTERISTIKE PROMENA NA PANKREASU KOD LABUDOVA I KOKOŠAKA PRIRODNO INFICIRANIH VIRUSOM AVIJARNE INFLUENCE PODTIPA H5N8

BOŽIĆ Biljana, POLAČEK Vladimir, VUČIĆEVIĆ Ivana,
VIDANOVIĆ Dejan, VASKOVIĆ Nikola, PRODANOV-RADULOVIĆ Jasna,
ALEKSIĆ-KOVAČEVIĆ Sanja

Tokom epizootije visoko patogene avijarne infleunce podtipa H5N8 u Srbiji krajem 2016. godine, najveći procenat mortaliteta zabeležen je kod labudova grbaca (*Cygnus olor*). Pozitivan nalaz na virus avijarne influence podtipa H5N8 je pored labudova utvrđen i kod kokošaka iz nekoliko seoskih domaćinstava. Od labudova i kokošaka kod kojih je potvrđen virus i koji su uginuli tokom epizootije, prikupljeno je tkivo pankreasa radi utvrđivanja karaktera lezija i distribucije virusnog antigena u ovom organu. Makroskopskim pregledom pankreasa kod labudova, utvrđene su promene u vidu krvavljenja i nekroze dok su kod kokošaka izostale makroskopski vidljive promene na ovom organu. Uprkos različitom makroskopskom nalazu, mikroskopskim pregledom pankreasa obe vrste ptica utvrđene su promene u vidu akutnog pankreatitisa i multifokalnih acinarnih nekroza. Virusni antigen je obilno eksprimiran u citoplazmi i jedru nekrotičnih ćelija, kao i u makrofagima kod obe vrste ptica pri čemu je utvrđen je visok stepen korelacije između ekspresije virusnog antigena i histoloških lezija u pankreasu. Na osnovu opisanih nalaza, može se zaključiti da virus visoko patogene avijarne influence podtipa H5N8 ima visok afinitet prema tkivu pankresa kod labudova i kokošaka, kao i da su distribucija i karakter mikroskopskih lezija slične kod obe vrste ptica.