

CLINICAL PRESENTATION OF BLUETONGUE AND THE MALIGNANT FORM OF CONTAGIOUS ECTHYMA IN SHEEP: DESCRIPTION OF CASES

STEVANOVIĆ Oliver^{1*}, NEDIĆ Drago²

¹PI Veterinary Institute of the Republic of Srpska Dr. Vaso Butozan Banja Luka, Republic of Srpska, B&H; ²University of Belgrade, Faculty of Veterinary Medicine and PI Veterinary Institute of the Republic of Srpska Dr. Vaso Butozan Banja Luka, Republic of Srpska, B&H

Received 27 November 2018; Accepted 27 March 2019

Published online: 13 May 2019

Copyright © 2019 Stevanović et al. This is an open-access article distributed under the Creative Commons Attribution License, which permits unrestricted use, distribution, and reproduction in any medium, provided the original work is properly cited

Abstract

Bluetongue and contagious ecthyma are sheep diseases that have very similar clinical presentation, thus, making it difficult to distinguish between the two based on clinical symptoms. In practice, a detailed clinical examination of sheep is underestimated and rarely is carried out. The paper presents and describes clinical cases of bluetongue and the malignant form of contagious ecthyma. The differences in the clinical presentation and diagnostic procedures for the two diseases are described in detail, as this information is necessary in order to establish correct disease control measures.

Key Words: sheep, bluetongue disease, contagious ecthyma, clinical presentation

CASE PRESENTATION

Case 1: Description of bluetongue in sheep

During the epizooty of bluetongue, various clinical forms of this disease in Republika Srpska, Bosnia and Herzegovina were observed in 2016. The first officially reported and described case of bluetongue in sheep was diagnosed in a family farm in Vrbnica, Foča municipality. Vrbnica is a small village with 10 farms located near Zelengora mountain in Herzegovina.

Epizootiological investigation. Initial symptoms of disease in sheep were observed in July, 2016: the owner noticed bloating and discharge from the mouth with swollen lips in

*Corresponding author – e-mail: oliver.13.stevanovic.bih@gmail.com

lambs. The sudden death of four lambs and one sheep in the flock was observed. Until August 2016, the number of affected sheep increased, and by the day of clinical examination, a total of 12 sheep had died, the corpses of which were uncontrollably disposed of in the environment. According to the farmer, some animals recovered from the disease. During examination, there were about 100 sheep in the flock and 19 head of cattle in the family farm, although many animals had not been marked. Sheep farming in Vrbnica is semi-nomadic, which is typical for this geographical area of Herzegovina. During the summer, sheep are grazed with other flocks on the pastures of Zelengora mountain without movement control. In winter, the same flocks are moved from the pastures to the village. Local veterinarians unsuccessfully tried to treat sheep with antibiotics and vitamins, but in the end, they reported suspicion of bluetongue to the veterinary inspector. Furthermore, the owner stated that a similar disease had appeared in other sheep flocks on the pastures of Zelengora mountain.

Clinical examination. A number of animals, including sheep and cattle, were not adequately marked on the farm, meaning animals did not have ear tags or other identification marks. In order to conduct proper sampling, triage of animals was applied, i.e. sampling and clinical examination was carried out only in 32 sheep and 7 cattle with valid marking (ear tags). Sheep in the suspected flock had poor health status. It was clearly noticeable that the sick sheep were apathetic and depressed. On careful physical examination of affected animals, it was noted that several types of clinical changes, depending on the course of the disease, existed in the flock. Clinical changes were more noticeable in lambs. Fever, general weakness, and edema of ears, eyelids and lips were observed as initial clinical changes in lambs (Figure 1). These lambs expressed various degrees of respiratory distress.



Figure 1. Initial clinical picture in the flock: swelling of ears, lips and eyelids

Besides the noted swelling in lambs, in several sheep in the flock, a swollen and congested tongue was observed (Figure 2), and on labial mucosa there were ulcers with hemorrhage. Due to the swelling of the tongue, the sheep showed abundant salivation. Necrotic skin and mucosal changes were detected on nostrils which were covered with ulcers in several sheep in the affected flock (Figure 3a). The symptoms were visible on hooves – there were changes on the corium which began with mild swelling of the fetlock joint. After that, hoof avulsion was observed, in our case, visible in one sheep. Consequently alterations in hooves resulted in the sheep showing signs of lameness.

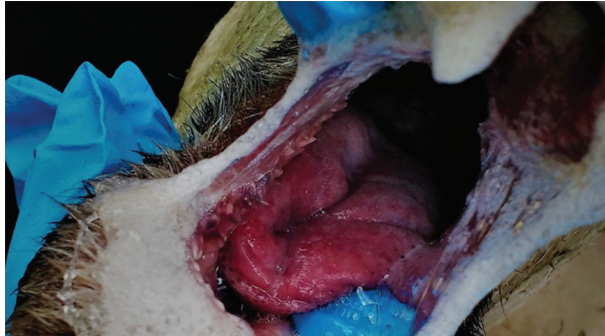


Figure 2. Edema and congested tongue

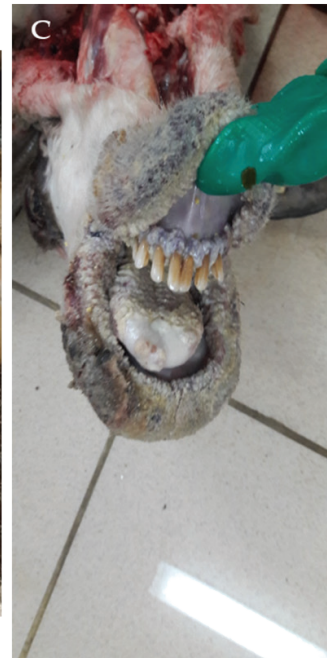
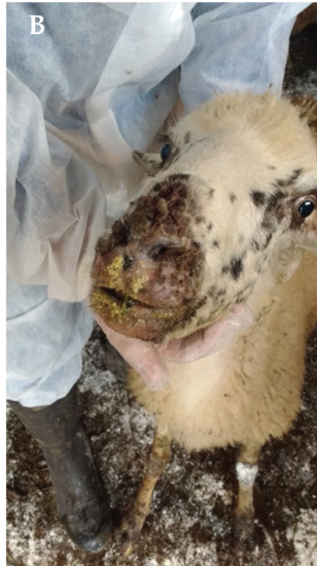
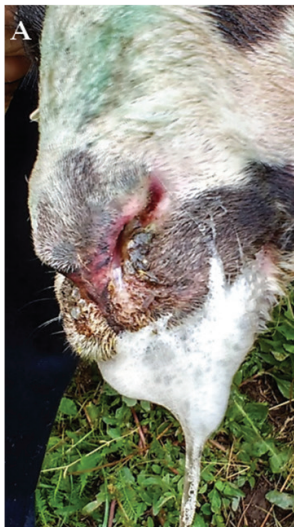Figure 3. a) Salivation, hyperemia and ulceration of nostrils in sheep; b) Proliferative and advanced changes in affected sheep; c) Advanced changes in oral cavity, lips and skin (photograph provided by Sonja Nikolić, spec.)

Diagnosis. Of the total of 32 sheep, 17 sheep showed signs of the disease at a different stage (from swellings on head to mouth, tongue and hoof changes) A total of 15 sheep in the flock and 7 cows from the same farm were seropositive to bluetongue virus by an ELISA test. Whole blood and serum samples were sent to the National Reference Laboratory for Bluetongue Disease, i.e. the Veterinary Faculty in Sarajevo. Additional analysis confirmed the disease, and the presence of bluetongue virus serotype 4 was confirmed by the European Reference Laboratory.

Case 2. Description of malignant form of contagious ecthyma in sheep

A malignant form of contagious ecthyma was described in a small sheep flock at the end September in 2017, in the small village of Rosulje, Pale.

Epi-zootiological investigation. During clinical examination, the field veterinarian suspected the presence of contagious ecthyma, but mortality was higher than usual. In the meantime, the carcass of one dead sheep from the affected flock was delivered to the Veterinary Institute of Republika Srpska Dr. Vaso Butozan Banja Luka for *post mortem* analysis. Affected sheep were not treated after the onset of the disease. According to the information taken from the owner, the following data were recorded: there were no similar symptoms of the disease in the previous years, there was no direct contact of the sheep with other flocks, there was no presence of bluetongue in the flock before, and all sheep were dewormed. The owner applied salt and iodine to treat the wounds of the affected sheep. Sheep were kept in bad hygienic conditions; these were typically extensive, which is characteristic of this region. Within 15 days, 33 sheep had died, which constituted nearly 50% of the flock.

Clinical examination. About 90-95% of the sheep in the flock was affected. There was noticeable general weakness of ill sheep, somnolence, depression, and visible cachexia. The examined sheep were febrile. Cough was noticeable with evident abdominal breathing. In several ill sheep, diarrhea with a small amount of fresh blood was observed. Other evident clinical changes included: head swelling, salivation, easily removable scabby lesions on the lips and nostrils. Beneath the scabs there were signs of fresh bleeding and pus. In the case of a larger number of sheep, nasal discharge was clearly visible. Proliferative changes with scabs were visible in the oral cavity of examined sheep with suppurative and foul-smelling discharge from the nose.

Diagnosis. Serologic examination excluded bluetongue. Pathological examination revealed proliferative lesions typical for ecthyma (Figure 3c) with secondary complications: necrotic and suppurative dermatitis and pneumonia. Vacuolar degeneration, epithelial inclusion with secondary necrosis, and lymphocytic infiltration were recorded by histology. Scab samples were sent to the Scientific Institute of Veterinary Medicine, Belgrade, Serbia, where the presence of parapoxvirus was confirmed by polymerase chain reaction. Furthermore, *Pseudomonas* spp. from the lungs of dead sheep was isolated by routine microbiological examination.

DISCUSSION

Bluetongue and contagious ecthyma are sheep diseases that need to be differentiated diagnostically because the measures to be undertaken in the case of outbreaks of these diseases are significantly different in Republika Srpska (Bosnia and Herzegovina). On the one hand, bluetongue is regularly reported and eradication in the case of an outbreak is regulated by legislation, while contagious ecthyma is regularly underestimated. In addition, there are no legally defined measures to control ecthyma. Although bluetongue in this area has been known since 2002 (Nedić, 2002; Đuričić et al., 2002; Mitrović et al., 2004, Đuričić et al., 2004; Velić et al., 2004); significant epizooty occurred in 2016, when this disease caused serious economic losses in sheep farming. One of the major problems for veterinarians at the time of the epizooty was to clinically distinguish bluetongue from ecthyma and other diseases (facial eczema, insect bites, etc.) with similar clinical presentation, especially in the initial clinical stages (Sperlova and Zendulkova, 2011).

Clinical examination of diseased sheep in the two described cases of disease showed differences in the type of lesions in the oral cavity and lips. The main noted differences were proliferative changes in lips and oral mucosa in the case of the malignant form of contagious ecthyma, which is understandable, given the epitheliotropism of the parapoxvirus. These signs were not seen in the case of bluetongue, but rather, swelling and hyperemia of oral mucosa and nostrils that could turn into bleeding and necrosis in the late stage of the disease were observed. Swelling and congestion due to changes in tongue blood vessels are typical in cases of bluetongue, giving a clinical pathognomonic sign. Similar clinical and pathological changes have been described in Montenegro during an outbreak of bluetongue (Pejović, 2016).

Changes in the tongue are also possible in contagious ecthyma, but they are proliferative, and later, they turn into scabs. Scabs can spread from the lips to the surrounding skin of the face, which was evident in our case. The scabs can easily be removed from the skin, leaving shallow erosions that become doorways for secondary bacterial infections. Consequently, suppurative and necrotic lesions occur in these places. If the sheep in the flock are immunocompromised, the mortality rate can rise, and in the literature this is called the malignant form of contagious ecthyma (Scagliarini et al., 2012). The mortality for contagious ecthyma can be over 50% (Scagliarini et al., 2012). Generally, contagious ecthyma has a lower mortality rate than bluetongue, but due to similar clinical phases, veterinarians sometimes do not submit samples for laboratory confirmation, which is not recommended in areas endemic for bluetongue. Although contagious ecthyma often occurs, there is not enough data on this disease in Republika Srpska and Bosnia and Herzegovina, and it is not possible to assess losses in the case of outbreaks. Advanced complications of contagious ecthyma in the sheep from Pale were a consequence of bad farming practice and inadequate treatment.

Clinical examination is essential and always helpful in making a final diagnosis. It is also necessary to revise the procedure for laboratory diagnosis of contagious ecthyma and

bluetongue in the Republic of Srpska. Unfortunately, in bluetongue endemic areas, serological techniques are insufficient, because a significant number of animals in the population will have been previously exposed to infection (Sperlova and Zendulkova, 2011). In this case, the disease must be confirmed using molecular techniques. Given the large number of diseases that can be mistaken for bluetongue, practitioners should insist on laboratory testing and, thus, reduce the possibility of diagnostic errors.

Authors contributions:

OS described outbreaks of Bluetongue and Malignant Orf in Bosnia and Herzegovina. OS and DN drafted manuscript.

Competing interests:

Authors declare that they have no competing interests

REFERENCES

- Nedić D. 2002. Veterinarsko-epidemiološka situacija u Republici Srpskoj i svijetu, 2001-2002. Zbornik radova, Osmo savjetovanje veterinara Republike Srpske – Uvodni referat, 7-8.
- Đuričić B., Pavlović M., Laušević D., Nedić D., Radenković-Damjanović B. 2002. Bluetongue - mere suzbijanja i kontrole bolesti. Zbornik referata i kratkih sadržaja Simpozijum, četvrti Jugoslovenski epizootiološki dani, 84-94.
- Mitrović N., Nedić N. D., Marić J., Santrač V. 2004. Epiziotološka situacija bolesti plavog jezika u 2002-2003 godini u Republici Srpskoj. Zbornik kratkih sadržaja 10. Godišnje savjetovanje veterinara Republike Srpske, 61-62.
- Đuričić B., Nedić D., Laušević D., Pavlović M. 2004. The epizootiological occurrence of bluetongue in the central Balkans. *Veterinaria Italiana*, 40 (3), 105-107.
- Velić L., Velić R., Bajrović T., Dukić B., Čamo D. 2004. Bluetongue in Bosnia: comparisons of competitive enzyme-linked immunosorbent assay and standard agar gel immunodiffusion tests. *Veterinaria Italiana*, 40(4), 562-563.
- Pejović N. 2016. Nalaz karakterističnih patomorfoloških promjena kod ovaca sa malignom groznicom ovaca, Doktorska disertacija, Poljoprivredni fakultet, Univerzitet u Novom Sadu
- Sperlova A., Zendulkova D. 2011. Bluetongue: a review. *Vet Med-Czech*, 56(9), 430-452.
- Scagliarini A., Piovesana S., Turrini F., Savini F., Sithole F., McCrindle C.M. 2012. Orf in South Africa: endemic but neglected. *Onderstepoort Journal of Veterinary Research*, 79(1), 1-8.

KLINIČKA PREZENTACIJA BOLESTI PLAVOG JEZIKA I MALIGNOG OBLIKA ZARAZNOG EKTIMA KOD OVACA: OPIS SLUČAJEVA

STEVANOVIĆ Oliver, NEDIĆ Drago

Kratak sadržaj

Bolest plavog jezika i zarazni ektim su bolesti ovaca koje imaju sličnu kliničku sliku te ih je teško razlikovati na osnovu ispoljavanja kliničkih znakova. U praksi, detaljan klinički pregled ovaca je potcenjen i retko se sprovodi. U radu su prikazani klinički slučajevi bolesti plavog jezika i maligne forme zaraznog ektima. Detaljno su opisane razlike u kliničkoj slici kod ova dva oboljenja i postupak postavljanja kliničke dijagnoze koja je neophodna za primenu efikasnih mera suzbijanja bolesti.

Ključne reči: ovce, bolest plavog jezika, zarazni ektim, klinička prezentacija