

## Unilateral ureteral obstruction in a ferret - case report

Ivana Kiš<sup>1</sup>, Gabrijela Jurkić Krsteska<sup>1</sup>, Mirna Brkljačić<sup>1\*</sup>, Marin Torti<sup>1</sup>, Dražen Vnuk<sup>2</sup>, Marko Hohšteter<sup>3</sup>, Miloš Vučičević<sup>4</sup>, and Vesna Matijatko<sup>1</sup>

<sup>1</sup>Clinic for Internal Diseases, Faculty of Veterinary Medicine, University of Zagreb, Zagreb, Croatia

<sup>2</sup>Clinic for Surgery, Orthopaedics and Ophthalmology, Faculty of Veterinary Medicine, University of Zagreb, Zagreb, Croatia

<sup>3</sup>Department of Veterinary Pathology, Faculty of Veterinary Medicine, University of Zagreb, Zagreb, Croatia

<sup>4</sup>Department of Equine, Small Animal, Poultry and Wild Animal Diseases, Faculty of Veterinary Medicine, University of Belgrade, Belgrade, Serbia

---

KIŠ, I., G. JURKIĆ KRSTESKA, M. BRKLJAČIĆ, M. TORTI, D. VNUK, M. HOHŠTETER, M. VUČIČEVIĆ, V. MATIJATKO: Unilateral ureteral obstruction in a ferret - case report. Vet. arhiv 90, 93-99, 2020.

### ABSTRACT

A four-year old castrated male ferret (*Mustela putorius furo*) was presented with a 1-week history of gastrointestinal signs. The ultrasonographic findings showed mild right pelvic dilatation and hydroureter with obstruction at the ureterovesical junction. Conservative treatment resulted in clinical but no ultrasonography improvement. Three months later the ferret was presented with signs of gastrointestinal disease. Ultrasonography revealed progression of the process to mild hydronephrosis and further dilatation of the right ureter. Excretory urography confirmed the finding. Laboratory findings indicated renal failure with proteinuria. Ureteroneocystotomy was performed. A small amount of sludgy material was found at the ureteropelvic junction. The ferret died 4 months later due to pneumonia. Necropsy revealed multifocal tubulointerstitial lymphoplasmacytic nephritis.

**Key words:** ferret; ureter; obstruction; proteinuria

---

### Introduction

In veterinary medicine, ureteral obstructions have emerged as an increasingly common problem in clinical practice (BERENT, 2011). Ureteral obstruction may be the result of intraluminal, mural or extraluminal compression. It may also be classified as acute or chronic, static or dynamic, partial or complete, or by its location. In dogs and cats intraluminal obstruction is the most common

cause of ureteral obstruction (SEGEV, 2011), and among all intraluminal causes, ureterolithiasis is the most common (BERENT, 2011).

Diseases involving the urinary tract are arguably less common in ferrets than in some other domestic animals (ORCUTT, 2003), and there are only a few reports of ureteral pathology in ferrets (VILALTA et al., 2017; DI GIROLAMO et al., 2015; BELL and MOELLER, 1990).

---

\*Corresponding author:

Assist. Prof. Mirna Brkljačić, PhD, DVM, Clinic for Internal Diseases, Faculty of Veterinary Medicine, University of Zagreb, Heinzelova 55, 10000 Zagreb, Croatia, Phone: +385 1 2390 111; E-mail: mbrkljacic@vef.hr

This report describes a case of dynamic unilateral ureteral obstruction at the level of the ureterovesical junction as the cause of unilateral hydronephrosis in a ferret.

### Case description

A four-year old castrated male ferret (*Mustela putorius furo*), weighing 1.5 kg, was presented with a 1-week history of vomiting, depression, decreased appetite and passing of soft stools. During the physical examination, the ferret was dehydrated and had mild cranial abdominal pain. Blood samples for haematology and biochemistry were collected from the cephalic vein. All findings were within the reference intervals (Table 1, Admission). Complete urinalysis, consisting of urine sediment, dipstick analysis and determination of urine protein and creatinine concentration, and the urine protein creatinine ratio (UPCR), was performed on a free catch urine sample. The abnormalities recorded are presented in Table 2 (Admission). The results of qualitative and quantitative bacteriological analysis were negative. After initial supportive treatment, diagnostic imaging studies revealed a mild dilation of the right renal pelvis and hydroureter (Fig. 1) with vigorous peristalsis (MyLab™ 40, Esaote, Italy, 8 MHz microconvex transducer), while radiographs (Genius HF#128A3, Villa Sistemi Medicali, Italy) were unremarkable.

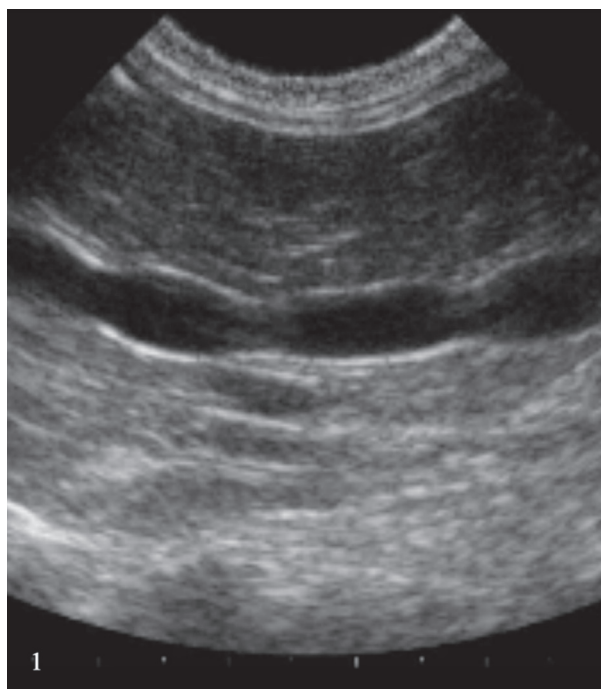


Fig. 1. Ultrasound image of the right ureter. The narrowings are contractions of ureter.

The dilated ureter was easily followed to the level of the ureterovesical junction, where no obvious cause of the obstruction could be determined. Further diagnostics (renal biopsy, antegrade pyelography) were refused by the owner due to financial constraints. Medical

Table 1. Values of haematocrit, urea, creatinine and phosphorus upon admission and at control appointments

	Adm	C1	C 2	C 3	C 4	C 5	RI
Haematocrit (%)	47	30	19	25	20	21	36-48
Urea (mmol/L)	10.4s	60.1	30.7	29.1	32.5	30.0	3.6-16
Creatinine (µmol/L)	40	230	143	141	108	148	35-79
Phosphorus (mmol/L)	ND	3.8	2.1	2.7	2.6	2.3	2.1-2.9

ND - not done; Adm - admission; C1 - Control 1; C2 - Control 2; C3 - Control 3; C4 - Control 4; C5 - Control 5; RI - Reference interval. Control 2 at discharge. Reference intervals according to Quesenberry and Orcutt (2012).

Table 2. Values of pH, urine specific gravity (USG), protein concentration and urine protein creatinine ratio (UPCR) upon admission and at control appointments

	Admission	Control 1	Control 4	Reference interval
pH	5.5	5.5	5.5	6.5-7.5
USG	1.020	1.015	1.015	
Protein (g/L)	1.2	0.99	0.63	0.07-0.33
UPCR	7.9	2.5	1.4	

Reference intervals according to Quesenberry and Orcutt (2012)

treatment was attempted, consisting of 24 hours of aggressive intravenous fluid therapy at the rate of 5 ml/kg/h, with monitoring of body weight, electrolyte concentrations and hydration status. Concurrently famotidine (Famosan, Alkaloid) and analgesia with meloxicam (Meloxidolor, Genera) were used. Although the ferret showed marked clinical improvement during the treatment (it stopped vomiting and had a normal appetite and stool), no improvement in ultrasound findings was observed. The ferret was discharged with standing recommendations for further diagnostic and therapeutic procedures. Three months later the ferret was again evaluated due to signs of weakness, anorexia and vomiting. At presentation the ferret

was apathetic, weak and dehydrated. No abdominal pain could be elicited upon palpation. At this point, the results of blood analyses showed decreased haematocrit and increased urea, creatinine and phosphorus values (Table 1, Control 1). Changes in the urine were present (Table 2, Control 1).

Abdominal ultrasound was repeated, and progression of the process to moderate dilation of the right renal pelvis (Fig. 2) and hydroureter was observed. After restoration of hydration status, a 350 mg/kg dose of iodinated ionic contrast medium (Telebrix 35, Guebert, France) was used for intravenous pyelography (Fig. 3), confirming the localisation of a partial obstruction at the level of ureterovesical junction.

The final diagnosis was dynamic partial obstruction of the right ureter at the level of the ureterovesical junction. The differentials were small uroliths, debris, stricture, mural proliferative or a neoplastic process. The proteinuria was thought to be the consequence of glomerulonephropathy which had progressed to renal failure with azotemia. Since the presence of azotemia was also evidence of coexisting significant impairment of the contralateral kidney, the decision was made to try to relieve the ureteral obstruction surgically.

Ventral midline laparotomy was performed. The right ureter was wide and, during palpation, it was difficult for urine to pass from the right ureter to

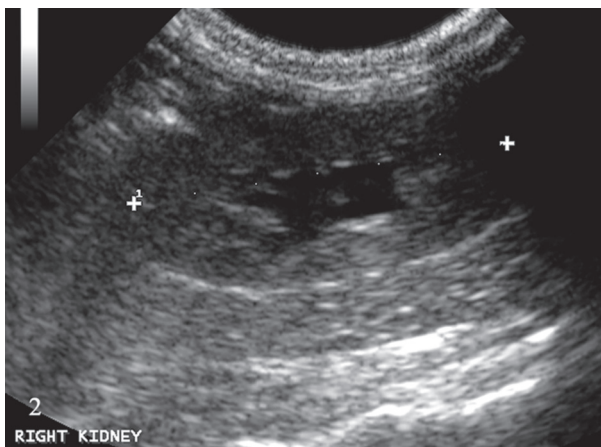


Fig. 2. Ultrasound image of the right kidney. Moderate hydronephrosis.

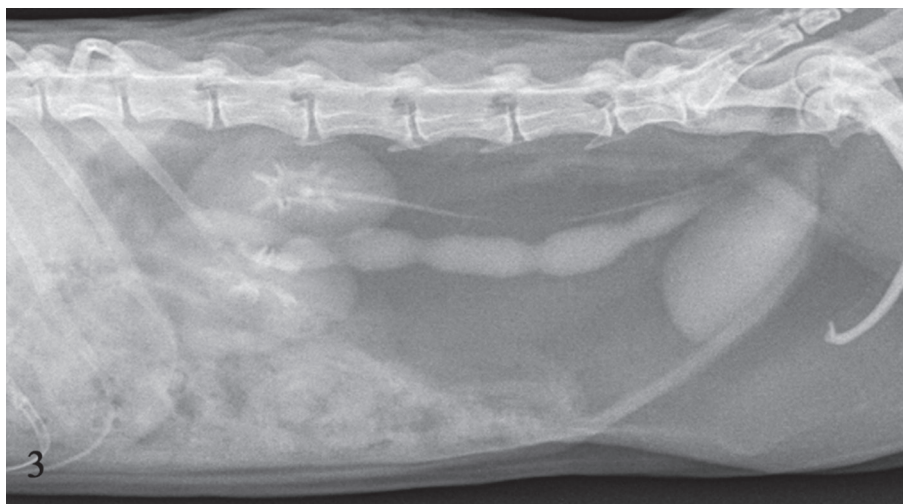

Fig. 3. Intravenous excretory urography. Dilated right ureter with multiple similar filling defects throughout its length, representing contractions of the ureter.

the urinary bladder at the level of the ureterovesical junction. Ureteroneocystostomy was performed, following the same procedure reported for cats (MEHL et al., 2005; WORMSER et al., 2016).

As no thickening or narrowing were visible or palpable on the removed part of the ureter, it was opened and a small amount of thick sludgy material was found covering the wall of the ureter. The retrieved material was used for cytological examination, which revealed eosinophilic amorphous material without recognizable cellular elements. The amount of material precluded further analyses.

At controls after 1 week, 1 month and 3 months (Table 1, Controls 3, 4, 5; Table 2, Control 4) persistent azotemia was found, confirming the diagnosis of chronic renal failure due to progression of glomerulonephropathy. All urinalyses showed increased protein concentration and UPCr. Ultrasound control 1 month after the operation showed a dilated ureter without visible peristalsis and no progression of dilatation of the right pelvis.

One month after the last control, the ferret died of pneumonia after one day of anorexia. At necropsy moderate hydronephrosis of the right kidney and hydroureter were detected. The healed surgical wound of the right ureter and urinary bladder was present. Post mortem catheterisation of the right ureter was facile.

Histopathological examination of both kidneys was performed and showed multifocal tubulointerstitial lymphoplasmacytic nephritis (Fig. 4). Pelvic distension of the right kidney with corticomedullary atrophy and focal cortical cyst were also present.

The main extra-renal lesions were diffuse interstitial pneumonia with neutrophilic, lymphocytic and plasmacytic infiltration of the interalveolar septa, alveolar oedema and emphysema, with multifocal bronchiolar dilation and bronchiolar epithelial hyperplasia, which were the cause of death.

Histopathological examination of the kidney and lungs with Congo red stain showed a negative result for the presence of amyloids.

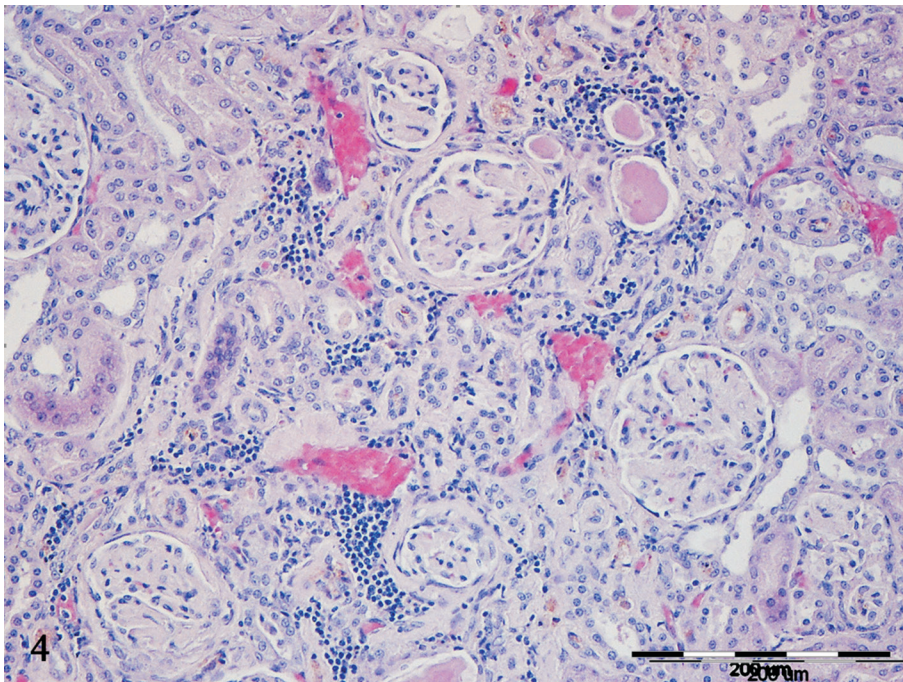


Fig. 4. Histopathology of the right kidney. Multifocal tubulointerstitial lymphoplasmacytic nephritis with intratubular protein accumulations (cylindruria) and multifocal glomerular and interstitial fibrosis. H&E; scale bar = 200  $\mu$ m.

## Discussion

Ureteral obstructions can be difficult to diagnose and treat in veterinary medicine (BERENT, 2011). Clinical findings in patients with ureteral obstructions can vary significantly from complete absence of any signs to various degrees of clinical manifestations.

In dogs with ureteral obstruction the usual reported clinical abnormalities are abdominal pain, vomiting, anorexia, depression or lethargy, fever or hypothermia, and abnormalities in urination (e.g. urinary incontinence, stranguria, dysuria, pollakiuria, polyuria, haematuria) (BERENT, 2011). A recent study in cats with ureteral strictures (ZAID et al., 2011) reported combinations of mostly nonspecific clinical abnormalities such as anorexia, lethargy, vomiting, diarrhoea, abdominal pain, weight loss, haematuria and polyuria/polydipsia. The ferret in this case report presented with signs of abdominal pain and a history of gastrointestinal symptoms.

As the ureterovesical junction is one of physiologically narrowest parts in the urinary tract of humans (HARDIE and KYLES, 2004), the finding of ureteral sludge at that specific location might suggest that this could be the same case in ferrets as well. It could also be possible that the presence of obstructive uretral sludge might be explained by the same mechanisms that cause the formation of urethral plugs in cats (KRUGER et al., 2009), the underlying processes being neurogenic inflammation, neuroimmune disbalance or psychoneuroendocrine disbalance in conjunction with adrenal androgens (REINES and WAGNER, 2018). As plugs in cats are predominantly a mixture of matrix made from proteinaceous gel that traps intact or disintegrated epithelial cells, leukocytes, erythrocytes, lipid droplets or various types of crystals (OSBORNE et al., 1992), a focal inflammatory process combined with proteinuria would seem to be a plausible explanation.

Although the presence of uroliths in ferrets is already well documented (NWAOKORIE et al., 2011; NWAOKORIE et al., 2013), proteinuria has not yet been reported. We established proteinuria by comparing the protein concentration in the

urine with the only available report of normal protein values in urine (QUESENBERRY and ORCUTT, 2012). The presence of protein sludge at the ureterovesical junction presents itself as a reasonable explanation, since high proteinuria without crystalluria was a consistent finding in all urinalyses. Even more, reports about the course of proteinuria are rare in domestic animals, and in ferrets there is only one report about amyloidosis, the disease that is accompanied with proteinuria, but the reported data were primarily based on pathological findings (GARNER et al., 2007), and proteinuria was noted in only one patient. To the authors' knowledge, this is the first report of the course of proteinuria in chronic renal disease in a ferret.

Ultrasonography is a well-recognized diagnostic imaging method which allows the examiner to monitor the dynamics of the process. The presence of ureteral contractions proved to be useful for following the ureter by ultrasonography from the pylon to the level of the bladder, rendering the use of Doppler unnecessary for discerning the ureter from blood vessels. Intravenous excretory urography also confirmed the localisation of the obstruction, proving itself to be a useful diagnostic method in ferrets too (VILALTA et al., 2017).

Hydronephrosis and hydroureter are relatively uncommon in ferrets, and most of the cases reported have resulted from inadvertent ligation of the ureters during ovariohysterectomy (ORCUTT, 2003), retrocaval ureter (DI GIROLAMO et al., 2015), congenital stenosis (VILALTA et al., 2017) or due to a tumour (BELL and MOELLER, 1990). In this case report the presence of ureteral sludge was determined to be the cause of the partial obstruction.

Renal diseases described in ferrets include renal cysts, acquired hydronephrosis, pyelonephritis, renal calculi, chronic interstitial nephritis, toxic nephropathy, immune complex glomerulonephritis and neoplasia (JACKSON et al., 2008). Some of those diseases are often related to abnormalities in other body systems, including the secondary reproductive organs (e.g. the prostate gland) and the adrenal glands (ORCUTT, 2003), which were not present in this ferret. Chronic renal failure as a

consequence of membranous glomerulonephropathy or some other acquired or developmental disease has been well described in ferrets (JACKSON et al., 2008). In this case report, on-going chronic renal disease was clinically silent until the point of development of the obstruction at the level of the ureterovesical junction, which caused secondary damage through the development of hydronephrosis. At that point the laboratory parameters and clinical signs indicated severe renal failure, averting the decision for renal biopsy. Ureteroneocystotomy was performed in order to prevent further damage caused by the ureteral obstruction. The procedure resulted in partial improvement of the laboratory parameters consistent with chronic renal failure, and advancing renal failure was compatible with the decrease in proteinuria. The ferret died of acute pneumonia unrelated to its renal disease.

Finally, concerning the facts of this case (the unspecific clinical signs of illness with no clear signs of a urinary tract problem) it is recommended to include urinalysis and abdominal ultrasound as a part of standard diagnostic work-up in ferrets.

## References

- BELL, R. C., R. B. MOELLER (1990): Transitional cell carcinoma of the renal pelvis in a ferret. *Lab. Anim. Sci.* 40, 537-538.
- BERENT, A. C. (2011): Ureteral obstruction in dogs and cats: A review of traditional and new interventional diagnostic and therapeutic options. *J. Vet. Emerg. Crit. Care* 21, 86-103.  
DOI: 10.1111/j.1476-4431.2011.00628.x
- DI GIROLAMO, N., A. CARNIMEO, A. NICOLETTI, P. SELLERI (2015): Retrocaval ureter in a ferret. *J. Small Anim. Pract.* 56, 355.  
DOI: 10.1111/jsap.12351
- GARNER, M. M., J. T. RAYMOND, T. D. O'BRIEN, R. W. NORDHAUSEN, W. C. RUSSEL (2007): Amyloidosis in black-footed ferret (*Mustela nigripes*). *J. Zoo Wildl. Med.* 38, 32-41.  
DOI: 10.1638/06-023.1
- HARDIE, E. M., A. E. KYLES (2004): Management of ureteral obstruction. *Vet. Clin. Small Anim.* 34, 989-1010.  
DOI: 10.1016/j.cvsm.2004.03.008
- JACKSON, C. N., A. B. ROGERS, K. J. MAURER, J. L. LOFGREN, J. G. FOX, R. P. MARINI (2008): Cystic renal disease in the domestic ferret. *Comp. Med.* 58, 161-167.
- KRUGER, J. M., C. A. OSBORNE, J. P. LULICH (2009): Changing paradigms of feline idiopathic cystitis. *Vet. Clin. Small Anim.* 39, 15-40.  
DOI: 10.1016/j.cvsm.2008.09.008
- MEHL, M. L., A. E. KYLES, R. POLLARD, J. JACKSON, P. H. KASS, S. M. GRIFFEY, C. R. GREGORY (2005): Comparison of 3 techniques for ureteroneocystotomy in cats. *Vet. Surg.* 34, 114-119.  
DOI: 10.1111/j.1532-950X.2005.00008.x
- NWAOKORIE, E. E., C. A. OSBORNE, J. P. LULICH, H. ALBASAN, C. LEKCHAROENSUK (2011): Epidemiology of struvite uroliths in ferrets: 272 cases (1981-2007). *J. Am. Vet. Med. Assoc.* 239, 1319-1324.  
DOI: 10.2460/javma.239.10.1319
- NWAOKORIE, E. E., C. A. OSBORNE, J. P. LULICH, H. ALBASAN (2013): Epidemiologic evaluation of cystine urolithiasis in domestic ferrets (*Mustela putorius furo*): 70 cases. *J. Am. Vet. Med. Assoc.* 242, 1099-1103.  
DOI: 10.2460/javma.242.8.1099
- ORCUTT, C. J. (2003): Ferret urogenital disease. *Vet. Clin. Exot. Anim.* 6, 113-138.
- OSBORNE, C. A., J. M. KRUGER, J. P. LULICH, J. W. BARTGES, D. J. POLZIN, T. MOLITOR, K. J. BEAUCLAIR, J. ONFFROY (1992): Feline matrix-crystalline urethral plugs: A unifying hypothesis of causes. *J. Small Anim. Pract.* 33, 172-177.
- QUESENBERRY, K. E., C. ORCUTT (2012): Basic approach to veterinary care. In: *Ferrets, rabbits and rodents: clinical medicine and surgery*. (Quesenberry, K. E., J. W. Carpenter, Eds.), Elsevier Saunders, St. Louis, pp. 13-26.
- REINES, B. P., R. A. WAGNER (2018): Resurrecting FUS: Adrenal Androgens as an ultimate cause of hematuria, periuria, pollakuria, stranguria urolithiasis and obstruction in neutered cats. *Front. Vet. Sci.* 5, 207.  
DOI: 10.3389/fvets.2018.00207
- SEGEV, G. (2011): Diseases of the ureter. In: *Nephrology and Urology of Small Animals*. (Bartges, J., D. J. Polzin, Eds.), Wiley-Blackwell, Ames, pp. 583-590.
- VILALTA, L., E. DOMINGUEZ, R. ALTUZARRA, N. SIBERA, Y. ESPADA, R. NOVELLAS, J. MARTORELL (2017): Imaging diagnosis - radiography and ultrasonography of bilateral congenital ureterovesical junction stenosis causing hydronephrosis and hydroureter in a ferret (*Mustela putorius furo*). *Vet. Radiol. Ultrasound* 58, E31-E36.  
DOI: 10.1111/vru.12399
- WORMSER, C., D. L. CLARKE, L. R. ARONSON (2016): Outcomes of ureteral surgery and ureteral stenting in cats: 117 cases (2006-2014). *J. Am. Vet. Med. Assoc.* 248, 518-525.  
DOI: 10.2460/javma.248.5.518

ZAID, M. S., A. C. BERENT, C. WEISSE, A. CACERES  
(2011): Feline ureteral strictures: 10 cases (2007-2009). J.  
Vet. Intern. Med. 25, 222-229.  
DOI:10.1111/j.1939-1676.2011.0679.x

Received: 30 October 2018

Accepted: 29 April 2019

---

**KIŠ, I., G. JURKIĆ KRSTESKA, M. BRKLJAČIĆ, M. TORTI, D. VNUK, M. HOHŠTETER, M. VUČIČEVIĆ, V. MATIJATKO: Unilateralna ureteralna opstrukcija u tvora - prikaz slučaja. Vet. arhiv 90, 93-99, 2020.**

#### **SAŽETAK**

Četverogodišnji kastrirani muški tvor (*Mustela putorius furo*) doveden je na kliniku zbog gastrointestinalnih simptoma. Ultrazvučni nalaz pokazao je blagu dilataciju desne bubrežne zdjelice i hidroureter s opstrukcijom na razini ureterovezikalnog spoja. Provedeno je konzervativno liječenje koje je dovelo do kliničkog poboljšanja, ali ne i do poboljšanja nalaza dobiveno ultrazvukom. Nakon tri mjeseca tvor je ponovno doveden na kliniku zbog općih znakova bolesti. Pri ponovljenoj ultrazvučnoj pretrazi utvrđena je progresija procesa u blagu hidronefrozu i izraženiju dilataciju desnog uretera. Dijagnoza je potvrđena i ekskrecijskom urografijom. Laboratorijski su nalazi jednoznačno upućivali na zatajenje bubrega s proteinurijom. Da bi se spriječila daljnja oštećenja desnoga bubrega učinjena je ureteroneocistotomija. Na mjestu opstrukcije pronađena je mala količina gustoga muljavog materijala. Tvor je otpušten na kućnu njegu, a četiri mjeseca poslije uginuo je od upale pluća. Patohistološki je nalaz utvrdio multifokani tubulointersticijski limfoplazmicitni nefritis.

**Ključne riječi:** tvor; ureter; opstrukcija; proteinurija

---