

## ACTINOMYCOTIC GRANULOMA IN HIGHLY PREGNANT SOW (CASE REPORT)

TIHOMIR PETRUJKIĆ, VLADIMIR KUKOLJ, BRANKO PETRUJKIĆ,  
BRANISLAV STANKOVIĆ<sup>1</sup>

*SUMMARY: This paper presents a case of udder actinomycotic granuloma in high-pregnant sows, which was surgically treated. The sow is from a private pig farm in eastern Serbia. Landrace sows, about 3 years old, weighing about 200 kg, it is normal eating and behaving normally. During the first examination, the mammary gland tumor was established, in the size of a fist. In another review, 81 days after mating the sow, the tumor was the size of the balloon of 5 liters. The tumor was surgically removed, and a sample was sent for histopathological diagnosis. The clinical picture and histopathological findings confirmed chronic purulent-granulomatous actinomycotic inflammation of the mammary gland. The postoperative course was uneventful. The sow farrowed 6 live piglets, 32 days after surgery (113 days gestation). All 6 piglets are weaned after 6 weeks. After weaning the litter, sows were surgically ovariectomised. The metastatic formations was not observed. Applied surgical procedure and postoperative treatment, show that the surgical treatment of mammary tumors can be successfully applied in practice.*

**Ključne reči:** high pregnant sow, actinomycosis, mammary gland, surgical treatment.

### INTRODUCTION

Actinomycosis is described as chronic granulomatous disease by cattle and pigs and rarely other animals and humans (Šamanc, 2001 and 2009). The cause of this disease is sometimes *A. bovis* and *A. israeli*. According to some authors, swine actinomycosis occurs sporadically (Sofrenović et.al., 1979; Naglič et.al., 2005). In the sows, the most common changes are observed on udder, and rarely on the other parts of skin and

---

Case report / Prikaz slučaja

<sup>1</sup>Tihomir Petrujković, DVM, PhD, full professor, Vladimir Kukolj, DVM, PhD, assistant, Branko Petrujković, DVM, PhD, assistant, Faculty of Veterinary Medicine, Belgrade, Serbia. Branislav Stanković, DVM, PhD, assistant, Faculty of Agriculture, Belgrade-Zemun, Serbia.

Corresponding author: Tihomir Petrujković, e-mail: tihomirpetrujkic@hotmail.com; phone: + 381 11 268-41-84.

\*The paper presents a part of research results of the project TP 20110, financed by the Ministry of Education and Science of the Republic of Serbia.

ears. Chronic suppurating granulomatous mastitis is usually the primary process occur on the udder. Also, changes have been observed on the skin. It is very rare visceral actinomycosis. The symptom of indigestion in visceral actinomycosis is very similar to the finding in the chronic peritonitis. In our article we present a clinical case of actinomycosis granulomas in high pregnant sow, which was surgically treated.

## MATERIALS AND METHOD

Landrace breed sows, about 3 years of age, and about 200kg body weight, was eating normally, and exhibited no changes in behavior. Sow originated from private pig farm eastern Serbia. During initial diagnosis was tumor the size fist. During the second diagnosis, 81 days after mating, the tumor was the size of balloon of 5 liters. Preparing for surgery is performed so that meal sow deprived for 24 hours and water for 12 hours before surgery. The further course of preparation for the sow operation consisted in bathing and disinfecting the entire udder. Removed tumor was sent for histopathological diagnosis. The patho-histological laboratory of clip granuloma of the mammary gland is fixed with 10% neutral formalin. Subsequently the tissue processed standard automatic tissue processor (dehydration several time through alcohol, polymerization in xylene, paraffin, impregnation) and paraffin block. Paraffin thickness of 3- 5  $\mu$ m were stained with hematoxylin-eosin (HE). The described changes are consistent with chronic-purulent actinomycotic granulomatous inflammation.

## RESULTS AND DISCUSSION

Preparation for surgery sows udder we did Acetpromazina combination (0.22 mg / kg intramuscularly) and ketamine 20 mg / kg intramuscularly. The operation lasted 2 hours. At the moment of separation tumor granuloma tissue from the udder of a stronger, there was bleeding. In the inguinal region sow blood vessels were very large, about 2 cm in diameter and clearly defined. Cut the udder was over 40 cm long, and during the operation was a problem separation tumors of the udder. During surgery the tumor in sow's ear vein intravenously given 2 liters of infusion (5% glucose, Hartmann's solution, vitamin C and calcium at recommended doses). Closure of the wound edges was performed linen thread.

Histological examination receipt granuloma of the mammary gland was found in central suppurous fireplace set consisting of neutrophils affected by degenerative process. In the purulent mass were submerged colonies eosinophilic agents radial looks. Around described the formation of specific granulation tissue composed of macrophages, epithelioid cells and lymphocytes. Periphery of the nodules seems poorly developed connective tissue made of fibroblasts and connective-tissue fibers (Fig. 1).

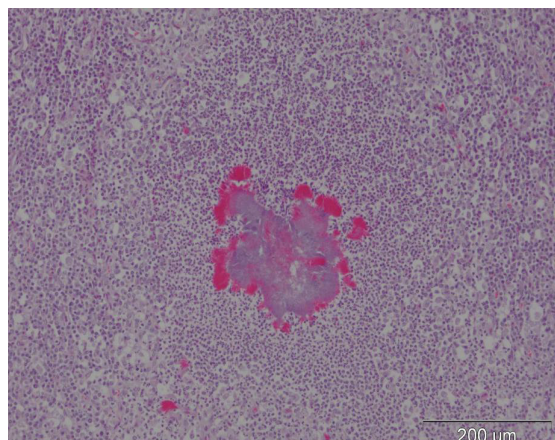


Fig. 1. Sow Mammary gland, actinomycotic granuloma with central druse in pus, HE, 200x  
 Slika 1. Mlečna žlezda krmače, aktinomikotični granulom sa centralno postavljenom družom, u gnoju, HE, 200x

The sow was treated with oxytetracyclin in recommended doses for seven days after surgery. The wound is protected with an external drain placement. Cutisan Fl-gocid-fat and Chloramivet spray (twice daily) to the removal of stitches. Sutures were removed 24 days after surgery. Before and after surgery sows were kept in a clean white washed box of straw. Sows farrowed the 6 live piglets, 32 days after surgery (it was 113. day of pregnancy). After farrowing, the sow had no health disorders. Udder is a place for localization of actinomycosis. Leads to the formation of lumps and knots (actinomycoma) of various sizes that have characteristic histological structure (Satoshi et al., 1998). According to many authors chronic mastitis in sows is associated with actinomycosis, a rare tuberculosis and brucellosis (Yamini et al., 1988). It was found that the strep actinomycoma granulomatous tissue is in most cases a mixed microflora, depending on the situation in which a flammable process (Jawetz et al., 1982). Injuries to the skin allows agents to penetrate and form a chronic mastitis actinomycoma character (Bollwain, 1986). Characteristic that prevails in sows findings knot or thickening granuloma island with abscess or necrosis induration in one or more mammary complexes, which typically leads to a large increase of the udder. Changes occur on the teats are enlarged hard nodular relaxed and more at the mammary complex. Secretion of milk is negligible or does not exist in general. Health status of sows has not changed. In older sows are formed actinomycotic changes. In the parenchyma of one or more of the mammary glandular complexes are formed nodular formation, which consists of granulation tissue containing radiating formations, so called "comrade." On the industrial swine farms were recorded in the presence of granuloma actinomycotic sows. (Valcea, 2011). It is recommended that funeral prophylactic measures aimed at combating appearance this conquer technique. Monitoring the health of the sow, regulation and hygienic measures biosecurity on the farm. Monitoring indicators biosecurity farm (Stanković et al., 2009) suggest special attention to hygiene at farrowing and adequate preparation for farrowing sow also be disable presence of infection at farrowing during the puerperium. Conduct corresponding diet sows. Reports of the World Technical Committee animal health and food hygiene, it is said that Actinomycoza diagnosed in cattle herds in cer-

tain areas, and pigs are not mentioned. General recommendations in all countries is that their veterinary services and other universities to examine the institution's animal health and monitor the occurrence of the disease. Such reports should publish and make annual reports on these investigations. In the current practice of treatment mastitis occurring in sows usually related to the formation of MMA syndrome (mastitis, metritis, agalactia syndrome) in swine farms have not noticed or found formation actinomycotic granuloma (tumor) of the udder in sows, although there were tumorous formations of mastitis and cured exclusion of certain dairy complex in older sows (six or more parities) but not by the appearance of large tumors in pregnancy in sows.

## CONCLUSION

Clinically, this case confirmed that the operation of the mammary gland tumors in advanced pregnancy sows and it is not possible in this case performed an abortion or fetal death in the last third of pregnancy. Healing the wounds of the udder was completed within 24 days. Implemented procedures that were used during the surgical treatment and postoperative therapy proved to be good practice in the applicable in these tumorous formation in the mammary glands of pigs. After 6 weeks the sow was farrowed six live pigs, and then castrated. On the udder or anywhere on the body there were observed no changes that would indicate metastatic formations.

## REFERENCES

- BOLLWAIN, W.: Surgical procedure in boars and sows. In: Disease of swine 6th ed Leman AD, Strow B, Clock, RD and Mengeling WL. P 878, Iowa State University Press Ames, IA, 1986.
- GERALDO, C.A., SOBESTIANSKY, J.P.R., WERNER, O., DALLA, C., BARIONI, W.: Junior. Presence and corelation between urinary tract infections and presence *Actinomyces suis* in the urine of pregnant sows from South Brasil. *Pesquisa Agropecuaria Tropical*, 28:2,1, 2007.
- GRINE, I., OŽEGOVIĆ, L.: Critical survey of mycological research and literature in Yugoslavia up to 1957. *Mycopathologia*, 9:341-364, 1958.
- HULTEN, F., PERSSON, A., ELIASSON-SELLING, L., HELDMER, E., LINDDBERG, M., SJORGEN, U., KUGELBERG, C., EHLORSSON, C.J.: Clinical characteristics, prevalence, influence on sow performance and assessment of sow-related risk factors for granulomatous mastitis in sows. *American Journal*, 64:463-469, 2003.
- JAWETZ, E., MELNINCK, J.L., ADEBERG, E.A.: Review of Medical Microbiology. 15th Lance Medical Publications, Los Atlos CA, pp. 301-303, 1982.
- IVETIĆ, V., ŽUTIĆ, M.B., SAVIĆ, B., PAVLIVIĆ, I., MILOŠEVIĆ, B., VALTER, D.: Atlas Bolesti Svinja. Naučni institut za veterinarstvo Srbije, 2007.
- NAGLIĆ, T., HAJIG, D., MADIĆ, J., PINTER, L.J.: Veterinarska mikrobiologija, Veterinarski fakultet, Zagreb, 2005.
- SATOSHI, M., MURAKAMI, R., AZUMA, T., KOEDA, H., OOMI, T., WATANABE, J., HIROSHI, F.: Immunohistochemical detection for *Actinomyces* sp. in swine tonsillar abscess and granulomatous mastitis. *Mycopathologia*, 141:15-19, 1998.
- STANKOVIĆ, B., HRISTOV, S.: Najčešći propusti u obezbeđivanju biosigurnosti na

farmnama goveda i svinja. Zbornik naučnih radova Agroekonomik, 15(3-4)103-110, 2009.

SOFRENOVIĆ, Đ. i saradnici Bolesti svinja, udžbenik OZID, SFRJ, 1970.

YAMINI, B., SLOCOMBE, R.F.: Porcine Abortions. Caused by Actinomyces suis. Vet. Path., 25:323-324, 1988.

VALCEVA N.I., van ASSELDONK M.A.P.M., BACKUS, G.B.C.: Perseved risk and strategy efficacy as motivators of risk managment strategy adoption to prevenrt animal disease in pig farming. Preventive veterinary medicine, 102:284-295, 2011. ŠAMANC, H.: Bolesti svinja, udžbenik. Vetereinarska komora Srbije, 2009.

ŠAMANC, H., BOJKOVSKI, J., JANKOVIĆ, D., MERČEP DRINKA: Aktinomikoza goveda. 13. Savetovanja veterinara sa međunarodnim učešćem, Zlatibor. Zbornik radova, str. 215, 2001.

## **AKTINOMIKOTIČNI GRANULOM KOD VISOKO GRAVIDNE KRMAČE (PRIKAZ SLUČAJA)**

TIHOMIR PETRUJKIĆ, VLADIMIR KUKOLJ, BRANKO PETRUJKIĆ, BRANISLAV STANKOVIĆ

### **Izvod**

O ovom radu je opisan slučaj aktinomikotičnog granuloma kod visoko gravidne krmače, koja je hirurški tretirana. Krmača rase Landras, stara oko 3 godine i telesne mase oko 200 kg, je vlasništvo jedne privatne farme u istočnoj Srbiji. Krmača je normalno jela i manifestovala normalno ponašanje. Kod prvog pregleda, tumor je bio veličine pesnice, a kod drugog, 81 dan posle parenja, tumor je bio veličine 5 litara. Pregledom je dijagnostikovana purulentna granulomatozno-aktinomikotična inflamacija mlečne žlezde. Ova dijagnoza je potvrđena histopatološkim pregledom. Ovaj slučaj pokazuje da je moguće uspešno odstraniti mamarni tumor krmače u kasnoj gravidnosti. Primenjena hirurška procedura i kasniji tretman pokazuju da mogu biti dobra praktična metoda u saniranju mamarnog tumora krmače. Posle 6 nedelja, krmača je oprasila 6 prasadi, a zatim je bila kastrirana. Uočenu su promene koje ukazuju na pojavu metastaza.

**Ključne reči:** visoko gravidna krmača, actinomycosis, vime, hirurški tretman.

Received / *Primljen*: 06.03.2012.

Accepted / *Prihvaćen*: 11.05.2012